Indian Journal of Animal Sciences **93** (6): 578–582, June 2023/Article
https://doi.org/10.56093/ijans.v93i6.128912

Relationship between serum biochemical parameters and kidney lesions in broiler chickens with acute tubular necrosis

ABDOLHAKIM BIDESHKI[1], MARYAM KARIMI-DEHKORDI[2]✉ and MAJID GHOLAMI-AHANGARAN[2]

Shahrekord Branch, Islamic Azad University, Shahrekord, Iran

Received: 8 October 2022 ; Accepted: 12 May 2023

ABSTRACT

To evaluate the effectiveness of biochemical factors such as blood urea nitrogen (BUN), creatinine, and serum uric acid in identifying and diagnosing acute tubular necrosis lesion in broilers, kidney tissue and blood samples from 80 broiler chickens at the slaughter stage were collected. Tissue samples were collected in 10% formalin to detect pathological lesions. The components of BUN, creatinine, and serum uric acid were measured with commercially available kits. After preparing the histopathological sections, based on the percentage of necrosis of the kidney tubules in each tissue sample, the pathological lesions were divided into 3 degrees: mild, moderate, and severe. The results showed that 36 samples out of 80 samples (45%) had acute tubular necrosis (ATN) lesions; 14 (17.5%), 12 (15%), and 10 (12.5%) samples had severe, moderate, and mild tubular necrosis lesions, respectively. The amount of uric acid in chickens with moderate and severe lesions showed a significant difference with the chickens without lesions and the mild lesion. However, BUN and creatinine increased significantly only in severe ATN lesions. In general, the results of this study state that severe lesions of renal tubules are associated with an increase in serum BUN, creatinine, and uric acid, but in moderate lesions, only uric acid may increase. Therefore, according to the results of this study, uric acid can be considered as a diagnostic biomarker in moderate to severe ATN.

Keywords: Biochemistry, Chickens, Kidney Tubular Necrosis, Pathology

Kidney disease in birds, like mammals, can be classified into chronic and acute. Acute kidney disease occurs as a result of a sudden and unexpected decrease in kidney function. Chronic kidney disease is described as a defect in the structural tissue of the kidney caused by a long and advanced disease process (Pollock 2006, Pendl and Kreyenbühl 2019). Causes of kidney disease in birds include infectious nephritis, vitamin A deficiency, heavy metal toxicity, and kidney tumor. Elevated blood uric acid in kidney disease occurs when there is a disruption in the integrity of the urinary tract or obstruction of urine flow (Alberton *et al.* 2019).

In birds, the most nitrogenous metabolic product is uric acid. Elevated serum uric acid levels are a main risk factor for renal failure (Gustafsson and Unwin 2013, Li *et al.* 2013). Birds produce very little urea, which does not serve as an important end product of protein metabolism. The urea cycle in birds is primarily limited to kidney detoxification processes and not nitrogenous waste disposal. Therefore, blood urea nitrogen (BUN) concentration is more affected by the bird's hydration status. BUN is of little value in diagnosing renal disease in most birds, but has been suggested as a sensitive indicator of hydration and a useful variable to detect prerenal factors for renal dysfunction in birds (Pollock 2006, Ravash *et al.* 2019).

Measurement of plasma creatinine concentration in mammals is used to evaluate the glomerular filtration rate. In birds, the physiological concentration of plasma creatinine is mostly below the detection limit (less than 0.06 mg/dl) in conventional methods, because birds mainly excrete creatine before it is converted to creatinine. The creatinine is a useful, inexpensive, readily available, and analyzable compound for examination of renal failure in birds (Huang *et al.* 2018, Alberton *et al.* 2019)

Kidney function is difficult to assess in birds because clinical signs are non-specific and often have little or no symptoms until the disease is fully advanced. Acute Tubular Necrosis (ATN) is one of the main causes of acute renal failure of kidney origin. This state can be caused by the increase in the use of drugs, chemical toxins, and microbial agents, which leads to an increase in serum biochemical indicators (Alberton *et al*. 2019, Etminan *et al*. 2021). Although, the effects of various drugs and poisons on kidney tissue and serum biochemical indices have been investigated in numerous reports (Yildirim *et al.* 2011, Gholami-Ahangaran *et al.* 2022), the relationship between the increase of renal function indicators such as

Present address: [1]D.V.M. Graduate, Faculty of Veterinary Medicine, Shahrekord Branch, Islamic Azad University, Shahrekord, Iran. [2]Department of Clinical Sciences, Faculty of Veterinary Medicine, Shahrekord Branch, Islamic Azad University, Shahrekord, Iran. ✉Corresponding author email: Ma_karimivet58@yahoo.com

uric acid, BUN, and creatinine with the severity of ATN in the kidney has not been studied, which is evaluated in the present study.

MATERIALS AND METHODS

In this study, blood samples and kidney tissues were collected from 80 broiler chickens in 20 chicken farms at slaughterhouse, randomly. A blood sample was collected without anticoagulant to measure serum biochemical parameters. Then the test tubes were centrifuged at 4000 rpm for 10 min. Serums were examined to perform kidney function tests, including BUN, creatinine, and uric acid. These values were measured using the commercial spectrophotometric kit (Pars Azmoun, Tehran-Iran) and based on the manufacturer's instructions.

Kidney tissue samples were fixed in 10% formalin and after dehydrating with alcohol using xylene, the remaining alcohol was removed and a paraffin block was prepared by a tissue preparation machine. A section with a thickness of 4-5 microns was prepared from the blocks with a microtome and stained with hematoxylin-eosin (H & E). Pathological changes in the tissues were investigated with a light microscope.

Score system was used for ATN histopathological examinations. distal and proximal tubular cell necrosis, infiltration of inflammatory cells, tubular dilation, intratubular cast formation, loss of brush border, intra tubular obstruction due to cellular were prominent in the histological findings. The kidney pathology was scored as described by Ishii *et al.* 2018 as follows:

Healthy = no visible cell damage
Mild = ATN on less than 20 % of the tubules
Moderate = ATN on 20-30 % of the tubules
Sever = ATN on more than 30 % of the tubules

The morphology of any lesions observed was classified and registered (Ishii *et al.* 2018). Correlation between pathological lesions and biochemical indices was done with Pearson's test. One-way analysis of variance (ANOVA) and Tukey's test with a significance level of $p<0.05$ were used to compare biochemical indices between healthy and diseased groups.

RESULTS AND DISCUSSION

The aim of this study was determination and comparison of the uric acid, BUN, and creatinine in healthy and chickens suspected with renal disease. Furthermore, the correlation of these parameters with acute tubular necrosis was studied in broiler chicken farms at slaughterhouse.

Recently, it has been reported that the identification of kidney failure depends on the detection of renal function indices in the serum. BUN, uric acid, and creatinine are the main indicators of kidney function in animals that were evaluated in this study (Abdelhalim *et al.* 2020).

In the study, after measuring the serum concentration of BUN, creatinine, and uric acid in chickens of different farms, the average data of each farm was calculated and analyzed. The highest serum concentration of BUN was seen in farms no. 9, 18, 4, 5, 2, 1 and 11 (Fig. 1a). The highest serum creatinine concentration was related to farms no. 1, 2, 4 and 5 (Fig. 1b). The farms no. 11, 5, 10, 1 and 2 showed the highest uric acid level (Fig. 1c).

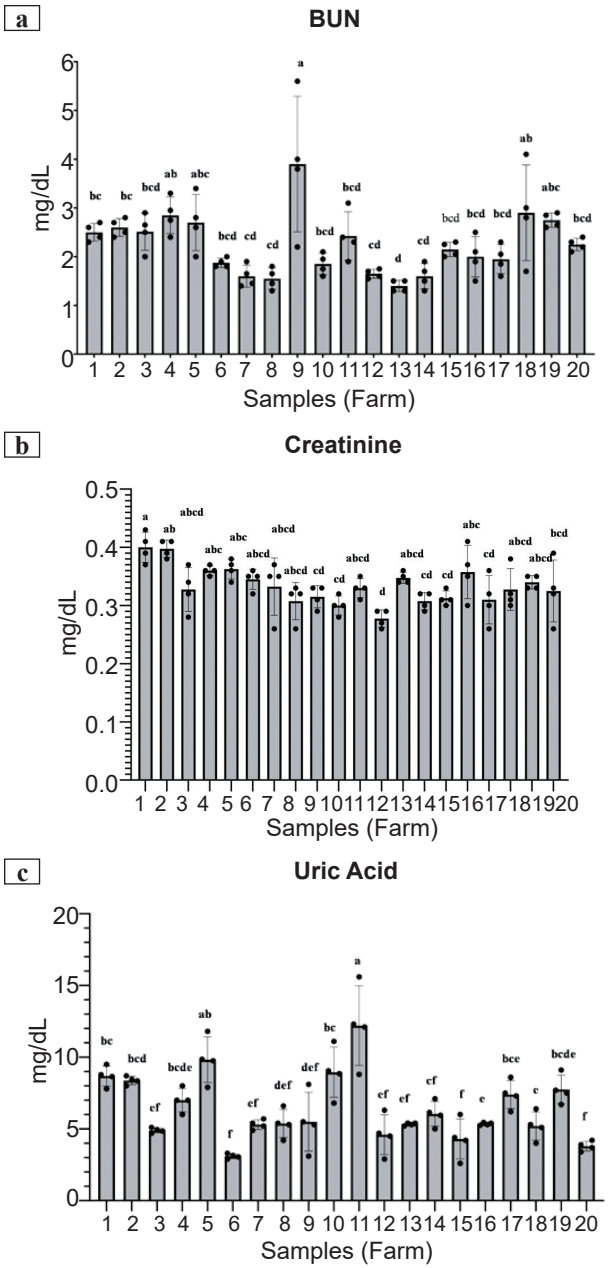

Fig. 1. (a) Comparison of average BUN in studied farms (Mean±SD). (b) Comparison of average creatinine in studied farms (Mean±SD). (c) Comparison of average uric acid in studied farms (Mean±SD).

The highest mean percentage of ATN was seen in farms no. 1, 2, 5 and 11, respectively (Fig. 2). As illustrated in Figs.1 a,b,c and 2), the farms that showed higher BUN, creatinine and uric acid levels manifested the most ATN lesions.

Chickens with no lesions in kidney were classified as healthy. The variety of ATN severity (mild, moderate

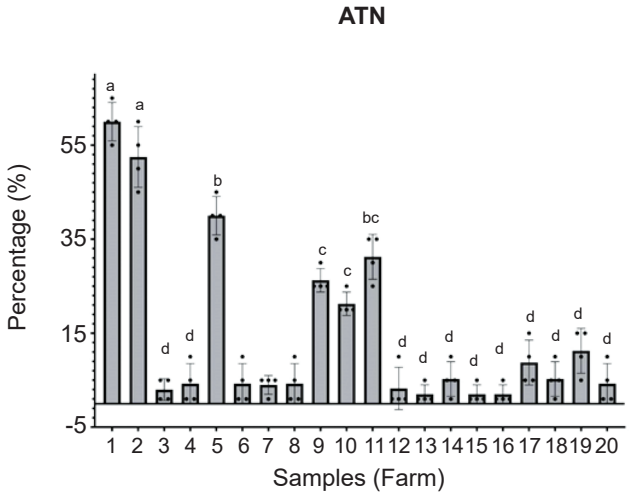

Fig. 2. Comparison of the percentage of ATN in studied farms.

and severe) was showed in kidney samples (Figs. 3 and 4). Around 44 (55%) chickens showed no lesions. Mild, moderate and sever lesions were found in 10 (12.5%), 12 (15%), and 14 (17.5%) chickens, respectively (Table 1). One of the causes of death in broilers is kidney failure caused by chemical compounds, drugs, and metabolic waste

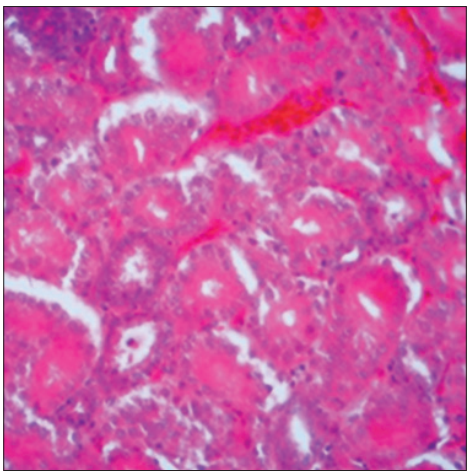

Fig. 3. Histological feature in mild ATN, H&E (×40), Normal tube (NT).

Table 1. Frequency and percentage of ATN lesion

Severity of ATN	Frequency	Percentage
Healthy (no lesions)	44	55
Mild	10	12.5
Moderate	12	15
Severe	14	17.5
All samples	80	100

(Ishii *et al.* 2022). Therefore, identifying renal biomarkers related to renal lesions may help to prevention and diagnosis of renal disease. The result of present study revealed that the frequency of 17.5% of severe acute necrosis of renal tubules, 15% of moderate acute necrosis of renal tubules, and about 12% of mild necrosis was one of the important findings of this study. Regardless of the severity of the ATN lesions, chickens in farms with higher mean BUN, creatinine and uric acid had more ATN percentage. This finding agrees with positive and significant correlation between the severity of ATN lesion and the average serum concentrations of BUN, creatinine, and uric acid.

The lowest and highest levels of BUN were seen in the healthy chickens and chickens with severe lesions, respectively ($p<0.05$). Although, the amount of BUN in the chickens with mild and moderate lesions are higher than healthy chickens, this difference is not significant. The amount of creatinine in the chickens with moderate and sever lesions were significantly higher than other groups ($p<0.05$). The amount of uric acid in the chickens with moderate and severe lesions were significantly higher than healthy chickens and chickens with mild lesion ($p<0.05$) (Table 2). Pearson correlation analysis showed that there is a positive and significant correlation between the severity of ATN lesion and the average serum concentrations of BUN ($r=0.356$; $p=0.001$), creatinine ($r=0.502$; $p<0.001$), and uric acid ($r=0.656$; $p<0.001$).

The simultaneous examination of the results of biochemical factors and pathological lesions in this study showed that the average serum uric acid in the groups with moderate and severe lesions increased significantly. These results of this study show that moderate to severe lesions

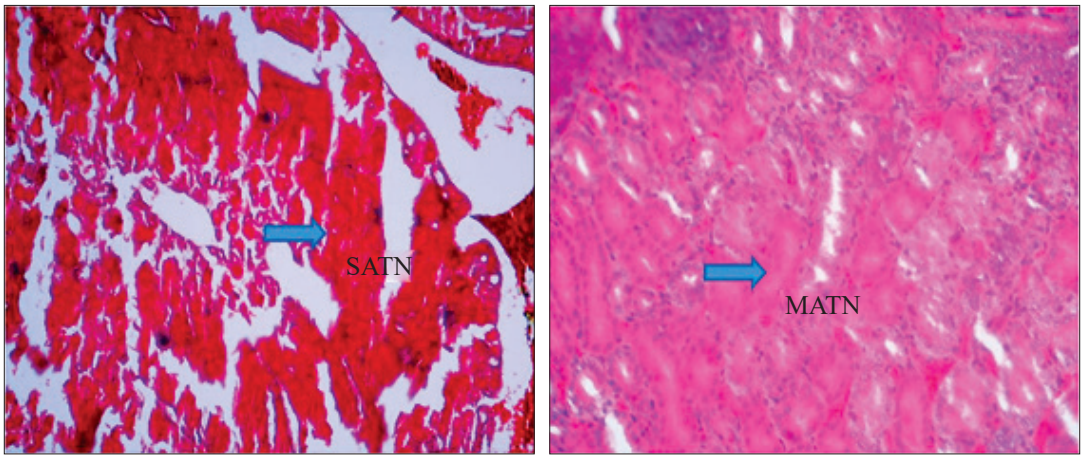

Fig. 4. Histological feature in severe and moderate ATN, H&E (×40); SATN, sever acute tubular necrosis; MATN, moderate acute tubular necrosis.

Table 2. BUN, creatinine, and uric acid (Mean±SD) levels in chickens with different severity of ATN

Parameter/Severity of ATN	Without lesion (n=44)	Mild (n=10)	Moderate (n=12)	Severe (n=14)
BUN (mg/dl)	1.99±0.51[a]	2.31±0.8[ab]	2.51±0.6[ab]	2.84±0.35[b]
Creatinine (mg/dl)	0.32±0.03[a]	0.32±0.03[a]	0.31±0.02[b]	0.37±0.03[b]
Uric acid (mg/dl)	5.04±1.19[a]	6.54±1.88[a]	7.77±2.53[ab]	9.65±2.16[b]

Different superscript letters in each column represent significant differences ($p<0.05$).

of renal tubules can be predicted by increasing serum uric acid levels, but moderate and severe lesions cannot be distinguished by measuring blood uric acid levels. Also, uric acid can be considered a biomarker to identify severe and moderate renal lesions. Birds are uricotelic and most of the total nitrogen is excreted in the form of uric acid, and uric acid is the main end product of nitrogen metabolism in birds and is used to screen for kidney disease in birds. The formation and secretion of uric acid in broiler chickens are usually constant, but when the function of the kidneys is disturbed, the amount of uric acid in the blood increases. Severe acute necrosis of renal tubules and its effect on reducing kidney function can be a reason for the increase in uric acid levels in samples with these severe lesions (Khalil *et al.* 2015). In one study, the effects of simultaneous use of florfenicol and lasalocid on performance, biochemical and pathological parameters of muscle, heart, liver, kidney, and sciatic nerve in broiler chickens were investigated. Simultaneous administration of lasalocid and florfenicol affected liver and kidney histopathology and significantly increased creatine phosphokinase and uric acid (Rangsaz and Ahangaran 2011, Gholami-Ahangaran *et al.* 2016).

Although, in present study, an increase in uric acid was observed in chickens with moderate and severe kidney lesions, blood uric acid can be affected by several nutritional (Donsbough *et al.* 2010), metabolic (Hong *et al.* 2020) and even age and gender factors (Odunitan-Wayas *et al.* 2018). The difference in the amount of protein in the diet with the increase in the amount of total nitrogen in the diet is one of the other possible causes of the increase in blood uric acid in birds (Selle *et al.* 2021). It has also recently been reported that in animal models, the increase in blood uric acid, which is the main risk factor in gout, was increased in chronic diseases such as metabolic diseases, kidney diseases, and hypertension (Hong *et al.* 2020). It has been shown that the serum concentration of uric acid in broilers can be used as an indicator for the composition of amino acids or crude protein in the diet (Donsbough *et al*. 2010). Therefore, the increase of uric acid alone and without considering the clinical symptoms of birds cannot be a correct and reliable biomarker for the presence of ATN lesions.

The results of serum BUN and creatinine showed that regardless of the farm, the average serum BUN and creatinine showed a significant increase only in severe lesions compared to the healthy chickens, and chickens with mild, and moderate ATN lesions. These results show that the increase of these two serum parameters can indicate severe ATN. These factors can be used as biomarkers in predicting only severe renal tubular lesions, while moderate renal tubular lesions cannot be predicted by increasing the amount of serum BUN and creatinine. Previously, the increasing of BUN and creatinin in renal failure was studied Yildirim *et al.* (2011) showed that chronic kidney toxicity in broilers causes degenerative changes in the kidney and increases uric acid, urea nitrogen, and creatinine. Also, Gholami-Ahangaran *et al*. (2016) evaluated the effect of aflatoxin on kidney tissue and showed that chickens receiving aflatoxin had severe congestion, degeneration, and kidney necrosis along with increased uric acid and urea nitrogen (Gholami-Ahangaran *et al.* 2022).

Although in the mentioned studies the chronic effect of toxic compounds on the kidney and increasing of BUN and creatinine was observed, the severity of kidney injuries was not well determined, and the reason for the increase in these parameters could be the occurrence of severe lesions of ATN. BUN and creatinine are products of protein metabolism in the body of birds and other animals. Under normal conditions, these small molecules are removed from glomerular filtration. If for any reason, the amount of glomerular filtration decreases or the parenchyma is damaged, it can cause an increase in BUN (Khalil *et al.* 2015). Perhaps, one of the reasons why no significant increase of BUN was seen in moderate and mild lesions was the intact part of the renal parenchyma and normal filtration in these chickens.

According to the results, it can be stated that uric acid can be a useful biomarker in predicting all degree of ATN lesions, while creatinine, and BUN are useful only in prediction of severe ATN lesions. However, the biochemical parameters can be increased in other conditions such as nutritional conditions and metabolic diseases. Therefore, the simultaneous effects of other effective factors should also be considered in interpretation of biochemical results.

REFERENCES

Abdelhalim M A K, Qaid H A, Al-Mohy Y H and Ghannam M M. 2020. The protective roles of vitamin E and α-lipoic acid against nephrotoxicity, lipid peroxidation, and inflammatory damage induced by gold nanoparticles. *International Journal of Nanomedicine* **15**: 729.

Alberton S, Vergneau-Grosset C and Summa N. 2019. Advances in exotic animal clinical pathology. *Veterinary Clinics: Exotic Animal Practice* **22**(3): 367–85.

Donsbough A, Powell S, Waguespack A, Bidner T and Southern L. 2010. Uric acid, urea, and ammonia concentrations in serum and uric acid concentration in excreta as indicators of amino acid utilization in diets for broilers. *Poultry Science* **89**(2): 287–94.

Etminan P S, Jafarian Dehkordi M and Karimi Dehkordi M. 2021. The effects of hyssop hydroalcoholic extract on the serum

biochemical factors of rats. *Journal of Medicinal Herbs* **12**(3): 23–9.

Gholami-Ahangaran M, Rangsaz N and Azizi S. 2016. Evaluation of turmeric (*Curcuma longa*) effect on biochemical and pathological parameters of liver and kidney in chicken aflatoxicosis. *Pharmaceutical Biology* **54** (5): 780–87.

Gholami-Ahangaran M, Karimi-Dehkordi M, Namjoo A, Shojaei H and Ahmadi-Dastgerdi A. 2022. The co-administration effects of florfenicol and lasalocid on performance, biochemical and pathological parameters of muscle, heart, liver, kidney and sciatic nerve in broiler chickens. *Veterinary Medicine and Science* **8**(1): 211–18.

Gustafsson D and Unwin R. 2013. The pathophysiology of hyperuricaemia and its possible relationship to cardiovascular disease, morbidity and mortality. *BMC Nephrology* **14**(1): 1–9.

Hong F, Zheng A, Xu P, Wang J, Xue T, Dai S, Pan S, Guo Y, Xie X and Li L. 2020. High-protein diet induces hyperuricemia in a new animal model for studying human gout. *International Journal of Molecular Sciences* **21**(6): 2147.

Huang S C, Fu Y F, Lan Y F, Rehman M U and Tong Z X. 2018. Histopathological and biochemical evaluations of the kidney in broiler chickens under acute heat stress conditions. *Indian Journal of Animal Research* **52**(4): 637–39.

Ishii C, Ikenaka Y, Ichii O, Nakayama S, Nishimura S-I, Ohashi T, Tanaka M, Mizukawa H and Ishizuka M. 2018. A glycomics approach to discover novel renal biomarkers in birds by administration of cisplatin and diclofenac to chickens. *Poultry science* **97**(5): 1722–29.

Ishii C, Kawai Y K, Ikenaka Y, Maekawa N, Ichii O, Nakayama S M and Ishizuka M. 2022. Clarifying expression patterns by renal lesion using transcriptome analysis and vanin-1 as a potential novel biomarker for renal injury in chickens. *Poultry science* **101**(9): 102011.

Khalil A A, Abou-Gabal A E, Abdellatef A A and Khalid A E. 2015. Protective role of probiotic lactic acid bacteria against dietary fumonisin B1-induced toxicity and DNA-fragmentation in sprague-dawley rats. *Preparative Biochemistry and Biotechnology* **45**(6): 530–50.

Li C, Hsieh M C and Chang S J. 2013. Metabolic syndrome, diabetes, and hyperuricemia. *Current Opinion in Rheumatology* **25**(2): 210–16.

Odunitan-Wayas F, Kolanisi U and Chimonyo M. 2018. Haematological and serum biochemical responses of Ovambo chickens fed provitamin a biofortified maize. *Brazilian Journal of Poultry Science* **20**: 425–34.

Pendl H and Kreyenbühl K. 2019. Clinical pathology. *BSAVA Manual of Backyard Poultry Medicine and Surgery.* BSAVA Library.

Pollock C. 2006. Diagnosis and treatment of avian renal disease. *Veterinary Clinics: Exotic Animal Practice* **9**(1): 107–28.

Ravash A, Jafarian Dehkordi M and Karimi M. 2019. The effect of hydroalcoholic extracts from Taraxacum officinale on blood indicators of kidney and liver functions in male rats. *Journal of Medicinal Herbs* **10**(1): 23–7.

Rangsaz N and Ahangaran M G. 2011. Evaluation of turmeric extract on performance indices impressed by induced aflatoxicosis in broiler chickens. *Toxicology and industrial Health* **27**(10): 956–60.

Selle P H, Cantor D I, Mcquade L R, Mcinerney B V, De Paula Dorigam J C, Macelline S P, Chrystal P V and Liu S Y. 2021. Implications of excreta uric acid concentrations in broilers offered reduced-crude protein diets and dietary glycine requirements for uric acid synthesis. *Animal Nutrition* **7**(4): 939–46.

Yildirim E, Yalcinkaya I, Kanbur M, Cinar M and Oruc E. 2011. Effects of yeast glucomannan on performance, some biochemical parameters and pathological changes in experimental aflatoxicosis in broiler chickens. *Revista de Medicina Veterinaria* **162**(8-9): 413–20.