



Pathomorphological and immunohistochemical investigations of myelocytoma caused by avian leukosis virus – J in adult laying birds

HARIKRISHNAN M P^{1✉}, AMARJIT SINGH¹, KULDIP GUPTA¹, GEETA DEVI LEISHANGTHEM¹
 and OMER KHALIL BABA¹

Guru Angad Dev Veterinary and Animal Sciences University, Ludhiana, Punjab 141 004 India

Received: 13 January 2023; Accepted: 16 April 2023

ABSTRACT

The subgroup J of avian leukosis virus causes myelocytomas, a neoplastic condition of the birds that affects several visceral organs. In the present study, myelocytomas were diagnosed in adult laying birds based on cytological and histopathological examination. On necropsy examination, the birds showed enlarged liver and spleen with multifocal tumorous growths in liver, spleen, kidneys, lungs, ovary, proventriculus, intestine and mesentery. Cytological examination of the impression smears from tumorous lesions revealed the characteristic myeloid cell population with granular cytoplasm and large eccentric nucleus with prominent nucleoli. Histopathologically, most of the organs showed infiltration of uniform sized, large myeloid cells arranged in sheets or columns. These cells had large number of cytoplasmic acidophilic granules and pleomorphic, vesicular or lobulated nucleus with few chromatin clumps. In addition, mitotic figures were also observed. The confirmatory diagnosis was done by immunolocalization of ALV-J viral antigen within the infiltrating cells in various tissues. Thus, the present study revealed circulation of ALV-J in the adult laying birds causing myelocytoma under field conditions in Punjab, India. Further, cytopathology can be used as an alternative tool for diagnosis of this viral disease in field conditions with limited resources.

Keywords: Avian leukosis virus-J, Cytology, Histopathology, Immunohistochemistry, Layer birds, Myelocytoma

In India, the poultry industry is one of the fastest growing sectors in the agriculture economy. The production of eggs and broilers has increased at a level of 8 to 10% annually compared to agricultural crop production, which is 1.5 to 2% per annum. However, various disease conditions including the avian oncogenic viral diseases affect the layer birds leading to decrease in the overall production as well as mortality. Lymphoma caused by avian oncogenic viruses in poultry have been associated with massive mortality and condemnation of the carcasses, and have great economic importance (Shailja *et al.* 2020). The avian leukosis virus (ALV) belonging to genus *Alpharetrovirus* within the Retroviridae family is prevalent worldwide (Fadly and Payne 2003, Chauhan and Sushovan 2010) and affect the broiler and layer birds. ALV has been classified based on variations in the viral glycoprotein antigens of the viral envelope, host infectivity into 10 subgroups in which A, B, C, D and J are exogenous, that possess complete infectious particles while E, F, G, H and I are endogenous, which are less pathogenic (Fadly and Payne 2003, Bagust *et al.* 2004). Since the first isolation of ALV-J in UK during 1989 from broiler breeders (Payne *et al.* 1991), till date there are reports from various parts of the world such as China

(Li *et al.* 2021) and USA (Spackman *et al.* 2003). In India, few studies were reported (Gopal *et al.* 2012, Satish *et al.* 2015, Chitradevi *et al.* 2018) where they observed ALV-J infections in commercial poultry birds. The birds infected with ALV-J are characterized by wide range of tumours including myelocytomas, erythroblastosis, hemangiomas and nephromas along with high mortality and impaired growth. Myelocytoma, a tumour condition caused by ALV-J involves skeletal system (inner sternum and ribs), liver enlargement, and occasional tumours in spleen, kidney, trachea, muscles, and gonads (Bagust *et al.* 2004). In the current study, myelocytomas associated with ALV-J virus were observed in adult layer birds based on gross lesions, cytological, histopathological and immunohistochemical study.

MATERIALS AND METHODS

The present study was conducted on birds suspected of neoplastic viral diseases presented for post mortem examination in the Department of Veterinary Pathology, Guru Angad Dev Veterinary and Animal Sciences University, Ludhiana. The birds were examined for gross lesions, cytological changes, histopathological changes, and selected tissue sections from each case was subjected to immunohistochemical reaction with avian leukosis virus polyclonal anti sera.

Collection of samples: Samples were collected from

Present address: ¹College of Veterinary Science, Guru Angad Dev Veterinary and Animal Sciences University, Ludhiana Punjab. ✉Corresponding author email: drharivet95@gmail.com

12 cases of adult laying birds showing tumorous enlargements and massive emaciation during necropsy examination. The samples include tissue pieces and impression smears from affected organs showing neoplastic changes, and processed for cytological, histopathological and immunohistochemical analysis.

Cytology: For cytological evaluation, impression smears from affected organs/tissues were collected air dried and fixed in methanol. The fixed smears were then stained with 5% Giemsa stain for 45 min and then washed in running water till extra stain was removed and air dried. The stained slides were observed under the microscope.

Histopathology: Tissue samples from various affected organs were collected and preserved in 10% neutral buffered formalin. The samples were then processed for routine histopathology, and embedded and prepared paraffin blocks. Thin sections of tissues (3-5 μ m) were cut from the embedded paraffin block and then affixed to microscope slides and passed through sequential steps of deparaffinization in xylene, rehydration through descending grades of ethyl alcohol to running water and stained using routine Haematoxylin and eosin (H and E) staining technique to increase the visibility of various cellular and intracellular components. The stained slides were observed for various histopathological features.

Immunohistochemistry: Tissues for immunohistochemical examination were selected after diagnosis with myelocytoma by histopathological examination. Primary antibodies used in this study was chicken polyclonal Avian leukosis-J antiserum (1:15000) (Charles River Laboratories, USA). Immunohistochemical staining of the sections was done using the avidin biotin complex (ABC) Kit (Vector Laboratories, Burlingame, USA) as per manufacturer's instructions. The dewaxing and rehydration of the sections were done in EZ-ARM Common Solution (BioGenex Laboratories Inc., San Ramon, California, USA), at 70°C for 10 min in microwave oven. This was followed by Heat induced epitope retrieval (HIER), using EZ-ARTM 3 Solution at 95°C for 10 min (Table 2) in microwave. Inactivation of endogenous peroxidases was performed using solution of 3% H₂O₂ in methanol for 1 h at room temperature. The sections were incubated with 1:10 dilution of a normal goat serum (Vector Laboratories, Burlingame, USA) mixed with power block (1 drop in 1 ml) (Biogenex Laboratories Inc., San Ramon, California) to block non-specific protein binding and Avidin D solution (4 drops in 1 ml) (Vector Laboratories, Burlingame, USA) to block non-specific avidin contents in tissues, for 60 min at room temperature in humidified chamber. This was followed by overnight incubation with the primary polyclonal antisera of ALV-J at a dilution of 1:15000 in 4°C. After overnight incubation, sections were incubated with secondary biotinylated anti chicken IgY (Vector Laboratories, Burlingame, USA) at a concentration of 1:400 for 30 min at room temperature. The sections were incubated in Vectastain ABC reagent (Vector laboratories, Burlingame, USA) for 30 min at room temperature. Tissues

were rinsed with phosphate-buffered saline for 3 times 3 min each between each step. The antigen-antibody peroxidase reaction was developed by 3,3-diaminobenzidine (DAB) with 5% hydrogen peroxide. Later, the sections were washed in distilled water for 5 min and then counter stained with Gill's haematoxylin (Merck, Germany) for 30 sec and washed in running tap water for 5 min. Finally, the slides were dehydrated in ascending grades of alcohol, cleared in xylene, mounted in DPX and examined under microscope (BX 61, Olympus Corporation, Japan). Negative control was run by replacing primary antibody with PBS buffer.

RESULTS AND DISCUSSION

On necropsy examination, the gross lesions observed were diffuse enlargement of organs like liver, spleen, kidney, lungs, proventriculus and intestine along with nodular growth in intestine circumscribing the whole surface as well as mesentery (Supplementary Fig. 1). Spleen showed enlargement and mottling in most cases (Supplementary Fig. 2). Nodules were also seen on the surface of heart, kidneys, ribs and sternum (Supplementary Fig. 3). Some cases liver showed diffuse enlargement with poorly demarcated variable sized multifocal grayish-white necrotic areas on the surface (Supplementary Fig. 4). All the affected birds were weak and emaciated. Mottled and enlarged liver with cherry red discoloration and greyish white pinpoint foci under capsule was observed in avian leukosis virus subgroup J virus infection in birds (Xu *et al.* 2004, Shailja *et al.* 2020). Myeloid tumors on liver with marked enlargement was reported in birds concurrently infected with subgroup J avian leukosis virus and reticuloendotheliosis virus (Cui *et al.* 2009). Xu *et al.* (2004) reported slight enlargement of spleen with whitish nodules in surface of birds affected by avian leukosis virus subgroup J infection in birds. Enlargement of kidneys with some greyish white mottled neoplastic growths were observed by Xu *et al.* (2004) in birds affected with avian leukosis virus subgroup J. Xu *et al.* (2004) observed undeveloped ovaries and oviduct in avian leukosis virus subgroup J infected birds during postmortem examination. Birds with enlarged visceral organs and skeletal myelocytomas on inner sternum, sacrum, cervical vertebrae and ribs were observed with subgroup J avian leukosis virus (Bagust *et al.* 2004, Xu *et al.* 2004 and Cheng *et al.* 2010). Nodular tumours of varying sizes involving spleen, liver, kidney and lungs due to myelocytomatosis were reported by Shailja *et al.* (2020).

Cytological examination of the impression smear revealed the presence of myeloid cells with characteristic eccentric nucleus, prominent nucleolus and cytoplasm filled with eosinophilic granules in liver (Fig. 1A), lungs, spleen, kidney and heart along with mitotic figures (Supplementary Fig. 5).

Microscopic examination of tissues of affected organs revealed population of immature myelocytes having eccentric nucleus, prominent nucleolus and cytoplasm filled with eosinophilic granules infiltrating in the liver around the central vein, and hepatic parenchyma (Supplementary

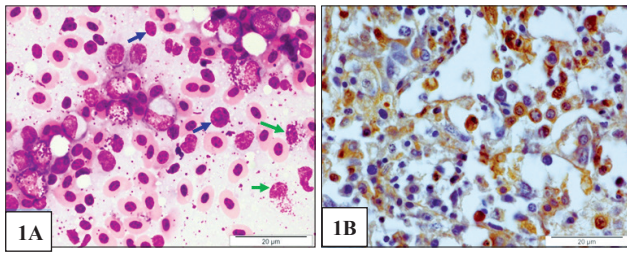


Fig 1. **A.** Liver: Impression smear showing mixed infiltration of pleomorphic lymphoid cells (Blue arrow) and myeloid cells (Green arrow), Giemsa 100 \times , Bar 20 μ m. **B.** Liver: Immunolocalization of avian leukosis virus – J viral antigen in liver, Vectastain ABC staining, counter-stained by Gill's haematoxylin \times 100 \times , Bar 20 μ m.

Fig. 6). Other observations were spleen disrupting the red pulp and white pulp, kidney focally between the tubules (Fig. 2A), ovary between the ovarian follicles (Supplementary Fig. 7), lungs around pneumocapillaries and interalveolar septa causing its thickening, and in intestine, cells were infiltrating in the lamina propria and mucosal area (Fig. 3A). Xu *et al.* (2004) and Sun *et al.* (2010) observed myeloid cells having eccentric nucleus, prominent nucleolus and cytoplasm filled with eosinophilic granules in the liver of birds infected with avian leukosis-J virus. Myelocytes predominated in the red pulp and white pulp of spleen in ALV-J infected bird (Sun *et al.* 2010, Xu *et al.* 2004). Swollen and degenerated tubular cells with myelocytes infiltration in the interstitium was observed in kidneys of ALV-J infected bird (Xu *et al.* 2004). Xu *et al.* (2004) observed pneumocapillaries and parabronchial lobules filled with myelocytes in ALV-J infected bird. Myelocytic proliferation was also observed focally in the ovary and oviduct. Microscopic examination of the intestinal wall and mesentery showed the presence of mixed population of myelocytes and pleomorphic cells along with connective tissue proliferation (Murakami and Sassa 2018). Myelocytes invasion into the lamina propria was also noticed. Xu *et al.* (2004) had observed lamina propria of the intestinal mucosa as well as mucous membrane of the proventriculus infiltrated with myelocytes. Shailja *et al.* (2020) and Bagust *et al.* (2004) observed the presence of immature myelocytes having characteristic eosinophilic cytoplasmic granule on tumours lesions of affected organs during histopathological interpretation.

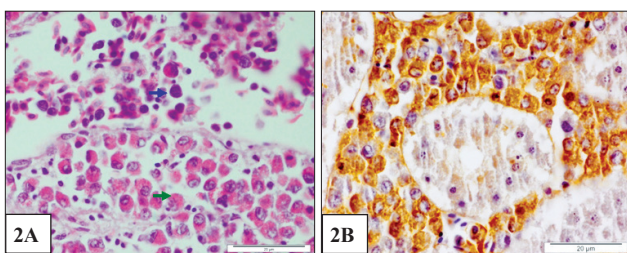


Fig 2. **A.** Kidney: Infiltration of pleomorphic lymphoid cells (Blue arrows), myeloid cells (Green arrows), H&E \times 100 \times , Bar 20 μ m. **B.** Kidney: Immunolocalization of avian leukosis virus – J viral antigen, Vectastain ABC staining, counter-stained by Gill's haematoxylin \times 100 \times , Bar 20 μ m.

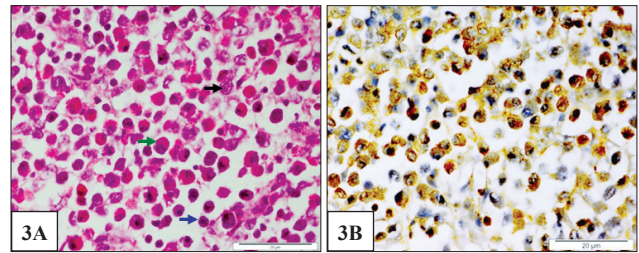


Fig 3. **A.** Intestine: Mixed infiltration of pleomorphic lymphoid cells (Blue arrow), reticular cells (Black arrow) and myeloid cells (Green arrow), H&E \times 100 \times , Bar 20 μ m. **B.** Intestine: Immunolocalization of avian leukosis virus – J viral antigen, Vectastain ABC staining, counter-stained by Gill's haematoxylin \times 100 \times , Bar 20 μ m.

Moderate to strong reactivity for ALV - J antigen was detected in the cytoplasm as well as nucleus of the infiltrating neoplastic cells in the liver (Fig. 1B), spleen, kidney (Fig. 2B), lungs, intestine (Fig. 3B), ovary (Supplementary Fig. 8) and proventriculus. Immunohistochemical staining for gp85 viral glycoprotein was done in tumourous lesions from birds experimentally infected with ALV-J and observed positive staining in all organs and most intense staining was observed in adrenal gland, heart, kidney and proventriculus (Gharaibeh *et al.* 2001). Xu *et al.* (2004) observed positive staining with monoclonal antibody to gp85 antigen of avian leukosis virus subgroup J in all affected visceral organs during immunohistochemical studies. Positive immunohistochemical staining was observed by Cheng *et al.* (2010) on some tumour cells for ALV-J antigen. Murakami and Sassa (2018) diagnosed avian leukosis virus subgroup J as the causative agent of pleomorphic malignant mesothelioma in a broiler bird based on immunohistochemical features. Neoplastic myeloid cells detected in bird affected by myelocytoma of ALV-J infection showed negative staining for CD79 alpha and CD3 differentiation markers, and hence concluded that these cells are not of T or B lymphoid origin (Shailja *et al.* 2020).

The present study concludes the prevalence of myelocytoma caused by avian leukosis virus-J in adult layer birds under field conditions and this will provide an additional knowledge in the field of avian oncogenic virus in India. Further the cytological methods will serve as a useful alternative tool for diagnosis of ALV-J in the field condition with limited resources.

ACKNOWLEDGEMENTS

The First author acknowledge ICAR for providing NTS scholarship during M.V.Sc. Programme in Veterinary Pathology at Guru Angad Dev Veterinary and Animal Sciences University, Ludhiana, Punjab.

REFERENCES

- Bagust T J, Fenton S P and Reddy M R. 2004. Detection of subgroup J avian leukosis virus infection in Australian meat-type chickens. *Australian Veterinary Journal* **82**(11): 701–06.

- Chauhan H V S and Sushovan R. 2010. Poultry diseases, diagnosis and treatment. 3rd Edn. p. 69-73. New Age International (P) Ltd, New Delhi.
- Cheng Z, Liu J, Cui Z and Zhang L. 2010. Tumors associated with avian leukosis virus subgroup J in layer hens of during 2007 to 2009 in China. *Journal of Veterinary Medical Science* **72**(8): 1027.
- Chitradevi S, Raja A and Sukumar K. 2018. Incidence of avian leukosis virus infection in commercial broiler chicken. *Indian Journal of Comparative Microbiology, Immunology and Infectious Diseases* **38**(2): 108–111.
- Cui Z, Sun S, Zhang Z and Meng S. 2009. Simultaneous endemic infections with subgroup J avian leukosis virus and reticuloendotheliosis virus in commercial and local breeds of chickens. *Avian Pathology* **38**(6): 443–48.
- Fadly A and Payne L. 2003. Leukosis/sarcoma group. *Diseases of Poultry*, 11th Edn. p. 465–516. Iowa State University Press, Ames, IA.
- Gharaibeh S, Brown T, Stedman N and Pantin M. 2001. Immunohistochemical localization of avian leukosis virus subgroup J in tissues from naturally infected chickens. *Avian Diseases* **45**: 992–98.
- Gopal S, Manoharan P, Kathaperumal K, Chidambaram B and Divya K C. 2012. Differential detection of avian oncogenic viruses in poultry layer farms and turkeys by use of multiplex PCR. *Journal of Clinical Microbiology* **50**(8): 2668–73.
- Li H, Tan M, Zhang F, Ji H, Zeng Y, Yang Q, Tan J, Huang J, Su Q, Huang Y and Kang Z. 2021. Diversity of Avian leukosis virus subgroup J in local chickens, Jiangxi, China. *Scientific Reports* **11**(1): 1–13.
- Murakami T and Sassa Y. 2018. Pleomorphic malignant mesothelioma in a broiler breeder infected with avian leukosis virus subgroup J. *Journal of Comparative Pathology* **160**: 50–55.
- Payne L N, Brown S R, Bumstead N, Howes K, Frazier J A and Thouless M E. 1991. A novel subgroup of exogenous avian leukosis virus in chickens. *Journal of General Virology* **72**(4): 801–07.
- Sathish G, Parthiban M, Divya K C, Kumanan K and Vedamanickam S. 2015. Detection of avian leukosis viruses in commercial poultry flocks by immunohistochemistry and PCR. *International Journal of Advanced Research in Biological Sciences* **2**(6): 215–24.
- Shailja P, Deepika L and Vikas N. 2020. Pathomorphological and immunohistochemical studies on myelocytomatosis in layer chicken. *Haryana Veterinarian* **59**(1): 55–58.
- Spackman E, Pope C R, Cloud S S and Rosenberger J K. 2003. The effects of avian leukosis virus subgroup J on broiler chicken performance and response to vaccination. *Avian Diseases* **47**(3): 618–26.
- Sun H, Qin M, Xiao Y, Yang F, Ni W and Liu S. 2010. Haemangiomas, leiomyosarcoma and myeloma caused by subgroup J avian leukosis virus in a commercial layer flock. *Acta Veterinaria Hungarica* **58**(4): 441-51.
- Xu B, Dong W, Yu C, He Z, Lv Y, Sun Y, Feng X, Li N, Lee L F and Li M. 2004. Occurrence of avian leukosis virus subgroup J in commercial layer flocks in China. *Avian Pathology* **33**(1): 13–17.