



## Pathomorphological and immunohistochemical investigations of myelocytoma caused by avian leukosis virus – J in adult laying birds

HARIKRISHNAN M P<sup>1✉</sup>, AMARJIT SINGH<sup>1</sup>, KULDIP GUPTA<sup>1</sup>, GEETA DEVI LEISHANGTHEM<sup>1</sup>  
 and OMER KHALIL BABA<sup>1</sup>

*Guru Angad Dev Veterinary and Animal Sciences University, Ludhiana, Punjab 141 004 India*

Received: 13 January 2023; Accepted: 16 April 2023

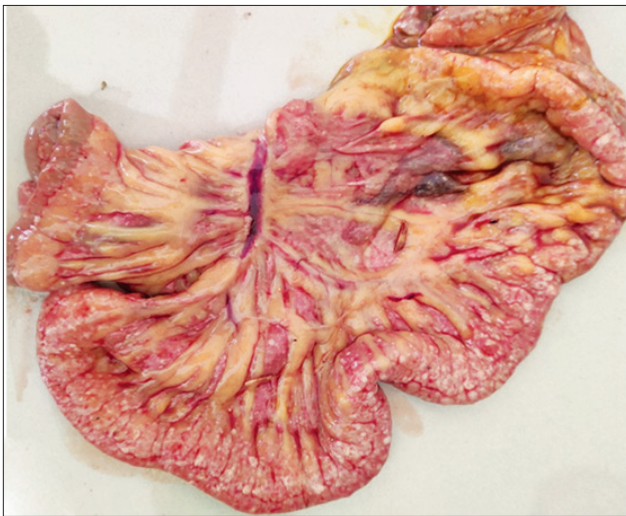

Fig. 1. Intestine circumscribed by multinodular foci throughout the surface and mesentery.

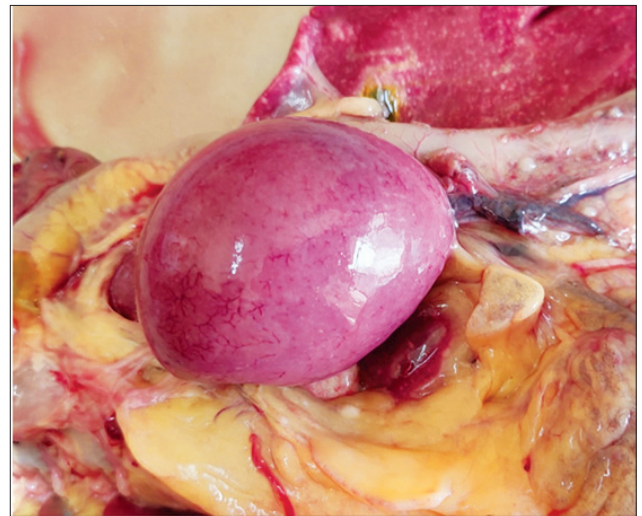

Fig. 2. Spleen diffusely enlarged and mottled spleen.

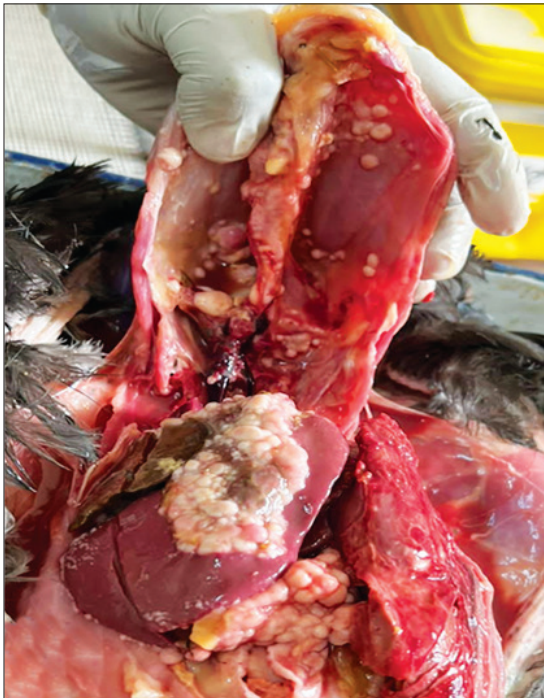

Fig. 3. Enlarged visceral organs and skeletal myelocytomas on inner sternum, sacrum, ribs, liver and intestine.

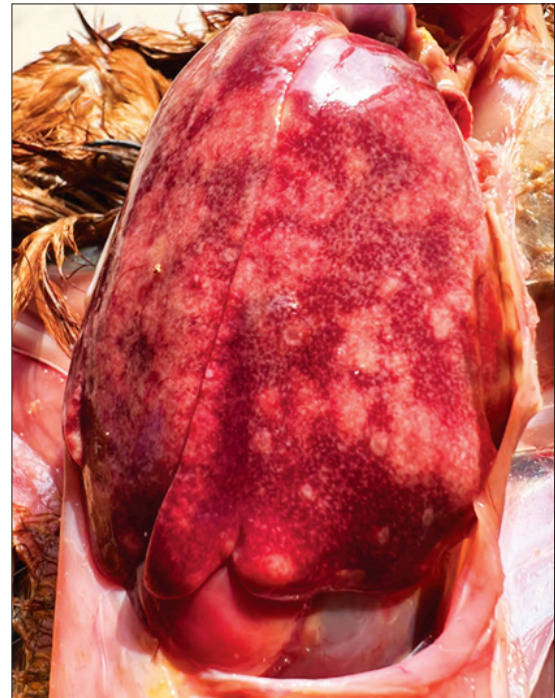

Fig. 4. Liver showing diffuse enlargement with poorly demarcated variable sized multifocal grayish-white necrotic areas.

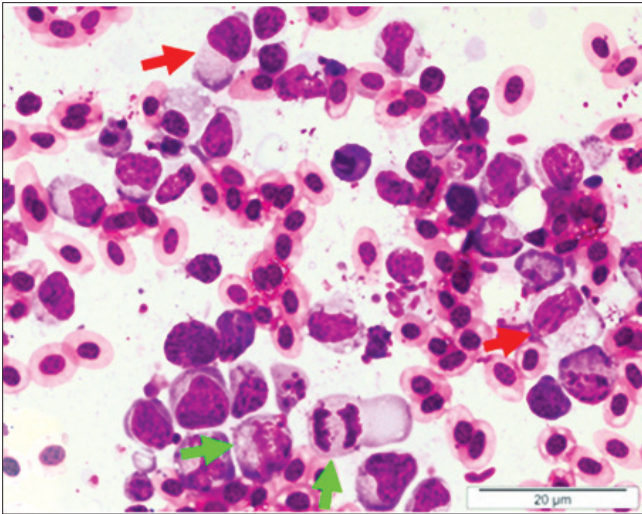


Fig. 5. Heart: Cytology showing myelocytes having eccentric nucleus, prominent nucleoli and abundant basophilic cytoplasm filled with eosinophilic granules (Red arrows) and mitotic figures (Green arrows). Giemsa stain, 100 $\times$ . Bar 20  $\mu$ m.

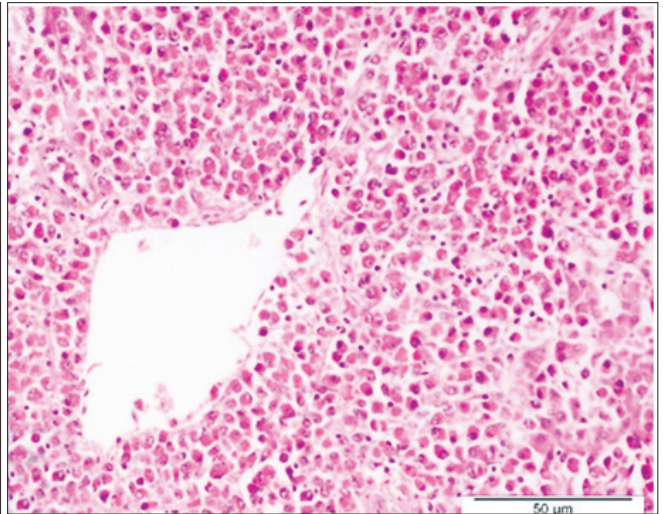


Fig. 6. Liver: Infiltration of myelocytes with eccentric nucleus prominent nucleoli and cytoplasm filled with eosinophilic granules around the central vein. H&E  $\times$  40 $\times$ , Bar 50  $\mu$ m.

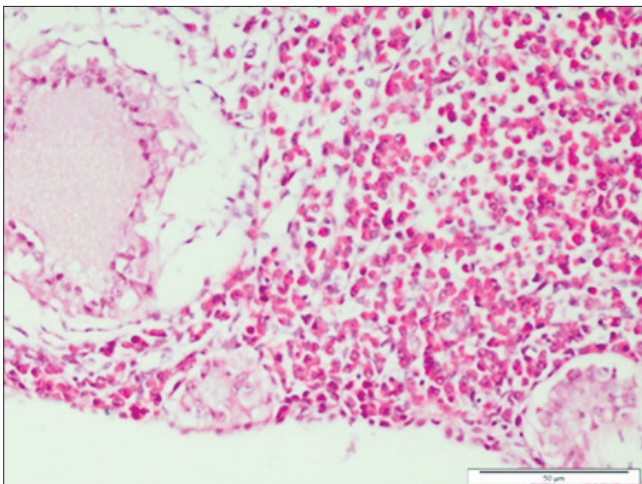


Fig. 7. Ovary: Infiltration of myeloid cells having granular eosinophilic cytoplasm between the follicles. H&E  $\times$  40 $\times$ , Bar 50  $\mu$ m.

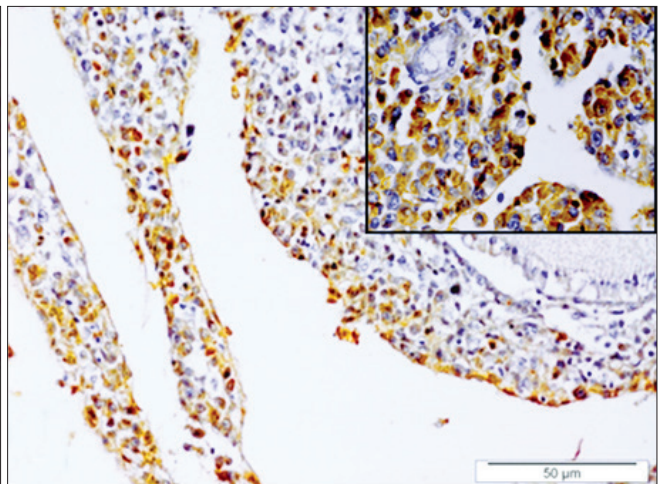


Fig. 8. Ovary: Immunolocalization of Avian leukosis virus – J viral antigen, Vectastain ABC staining, counter-stained by Gill's haematoxylin  $\times$  40 $\times$ , Bar 50  $\mu$ m. Inset showing the reactivity more clearly.