



## Note

# Captive maturation of the silver moony fish *Monodactylus argenteus* (Linnaeus, 1758) under laboratory conditions

PREM KUMAR, A. R. THIRUNAVUKKARASU, M. KAILASAM, J. K. SUNDARAY\*, G. BISWAS\*, R. SUBBURAJ, G. THIAGARAJAN AND S. ELANGESWARAN

Central Institute of Brackishwater Aquaculture, 75, Santhome High Road, R. A. Puram  
Chennai - 600 028, Tamil Nadu, India

\*Kakdwip Research Centre of Central Institute of Brackishwater Aquaculture, Kakdwip – 743 347  
South 24 Parganas, West Bengal, India  
e-mail: prem.cife@gmail.com

## ABSTRACT

The silver moony, *Monodactylus argenteus* is a highly priced euryhaline ornamental fish, which can survive well in freshwater, brackishwater as well as seawater. In the present investigation, an attempt was made to study the maturation of moony fish under controlled conditions. Sub-adults (mean weight  $7.0 \pm 0.45$  g), caught from Ennore backwaters, were reared for a period of one year from January to December 2010. Animals were fed *ad libitum* with frozen artemia biomass and formulated diet (32% crude protein, 8% lipid). Monthly sampling, through cannulation, was carried out to assess the maturity. Calculations of the biological parameters, like condition factor (K), gonado-somatic index (GSI) and histological analysis of gonad, were carried out from different size groups of animals to assess the maturity. Results of the present study showed that males attain sexual maturity at mean length of  $13.16 \pm 0.54$  cm (mean weight  $51.2 \pm 0.33$  g) and female of the same size was in maturing stage. The GSI was 0.62 in mature male and 0.72 in mature female. The value of GSI was found to increase with the advancement of maturity in both the sexes (male 0.21 to 0.62; female 0.23 to 0.72), which was in accordance with histological observations.

Keywords: Captive maturation, Gonado-somatic index, *Monodactylus argenteus*, Silver moony fish

The silver moony, *Monodactylus argenteus* is a highly priced euryhaline ornamental fish, which can survive well in freshwater, brackishwater and seawater. Young ones migrate to sea to attain sexual maturity, and mature fish migrates to freshwater for spawning. In teleosts, the development of gonad is directly related to the somatic growth (Misra, 1994) and is generally monitored on the basis of microscopic and macroscopic appearance of gonads (Wang *et al.*, 2003). Gonadal development represents morphological and physiological changes in gonad to attain sexual maturity (Ha and Kinzie, 1996; Wang *et al.*, 2003). The development of gonad has been described in terms of stages of maturity by several authors (Rideout *et al.*, 1990; Goodbred *et al.*, 1997). Patino and Sullivan (2002) described two basic stages of follicular growth in teleosts, *viz.*, previtellogenic and vitellogenic stage. Grier and Lo Nostro (2000) observed changes in the gonadal germinal epithelium and stressed its importance in the reproductive cycle of teleost such as its use in establishing reproductive classes in males. Testicular stage is generally assessed based on the relative proportion of spermatogonia, spermatocytes, spermatids and spermatozoa. To understand the reproductive physiology of fish,

the study of the seasonal developmental changes of the gonad by both macroscopic and microscopic observations is necessary.

In spite of its abundance and the ornamental value, the silver moony, *M. argenteus* is poorly studied and little information is available on its reproductive biology. The present study was conducted to have basic information on reproductive biology of silver moony, which would help in taking up captive breeding and seed production of the species in future.

Two hundred numbers of wild caught silver moony fish, *M. argenteus* from Ennore backwaters (mean weight =  $7.0 \pm 0.45$  g) were transported under closed system in oxygen filled polythene bag (10 l capacity) to Muttukadu Experimental Station of Central Institute of Brackishwater Aquaculture (CIBA), Chennai, India. They were carefully transferred to a circular tank (10 t) and were left undisturbed the whole night. As a prophylactic measure, a mild freshwater treatment was given, the next day. Frozen artemia biomass and formulated diet (32% protein, 8% lipid) were used as feed. Feed was given *ad libitum* twice daily at 10:00 and 18:00 hrs under a normal light regime. Uneaten feed and faecal matter were siphoned out daily and siphoned out water was replaced with fresh filtered seawater.

The volume of the water in the tank was maintained at 10 t with continuous aeration. Water was changed to the extent of 80% with clean filtered seawater at monthly intervals. Physico-chemical parameters of water, such as dissolved oxygen, pH, salinity, and temperature were measured with probes (HANNA), while total ammoniacal nitrogen was analysed by titrimetric method (APHA, 1989). Fishes were reared for a period of one year (January to December 2010) and sampled monthly to assess the sexual maturity through cannulation (cannula dia. 2.0 mm). Growth parameters such as weight gain% and specific growth rate (SGR) were calculated at the end of the year using the following formulae:

$$\text{Wt gain \%} = (\text{Final weight} - \text{Initial weight}) / \text{Initial weight} \times 100$$

$$\text{Specific growth rate (SGR)} = 100 (\log_e \text{ Average final weight} - \log_e \text{ Average initial weight}) / \text{Number of culture days}$$

Thirty fishes (n=30) from three different size groups (10-30 g, 30-50 g, and >50 g) were used to measure individual total length (TL) and wet weight (TW). For macroscopic and microscopic observation of gonad, fishes (n=30) from the different groups were dissected, gonads were collected and length (to nearest mm) and weight (nearest mg) were measured. Samples were also collected for histological study. The gonado-somatic index (GSI) for each fish was calculated using the formula of Yuen (1955):

$$\text{Gonado-somatic index (\%)} = (\text{Weight of gonad (g)} / (\text{weight of fish (g)} \times 100)$$

The average value of GSI was calculated for the three different size groups. The criterion for the characterisation of the maturity stage through macroscopic observation was based on colour, texture, size and extent of occupancy of gonads in the body cavity (Mc Bride *et al.*, 2002). The ponderal index or condition factor, K for each fish was calculated using the formula suggested by Clark (1934):

$$\text{Condition factor (K)} = (\text{Final mean body weight (g)} / \text{Mean total length (cm)}^3) \times 100.$$

The average values of K were determined for different size groups.

For histological studies, tissue samples collected from middle portion of gonads were immediately fixed in 10% neutral buffered formalin. The tissue samples were processed, embedded

in paraffin wax, sectioned and stained using haematoxylin and eosin, following the standard histological procedures (Fitzhung *et al.*, 1993).

Mean values of all parameters were subjected to one-way ANOVA and post-hoc test were carried out, using Duncan's multiple range tests, to determine the significant differences if any, between the mean values. Comparisons were made at 5% probability level. All statistical analyses were performed with SPSS 17.0 for Windows

The macroscopic staging of gonadal development is presented in Table 1. Anatomy of ovary showed that it is of the cystovarian type in which matured eggs will be released into ovarian cavity during ovulation. Testes have two lobes and each lobe is composed of many lobules, each lobule is separated from other by a thin layer of connective tissue.

Mean total length and mean wet weight of mature male was 13.16 cm  $\pm$  0.054 and 51.2 g  $\pm$  0.33 respectively. However, the females of same size group are in mature stage (Table 2 and Table 3). Growth parameters, such as weight gain% and SGR observed in one year were 0.55 % and 632 respectively. The mean value of K and GSI of male and female are given in Table 2 and 3 respectively. GSI indicates the stage of readiness of the ovary for maturation and degree of ripeness (Htun-Han, 1978). The mean value of GSI increases significantly ( $p < 0.05$ ) with the increase in average size of animal. Similar observation was made by Yashiro *et al.* (1993) in *Epinephelus malabaricus* and also by Tessy (1994) as well as Rao and Krishnan (2009) in *Epinephelus diacanthus*. It was also observed that the mean value of GSI in female is higher than the male and this may be due to the allocation of higher proportion of body reserve towards the development of ovary than testis. Chatzifotis *et al.* (2004) in *Dentex dentex* and Mahmoud (2009) in *Lethrinus nebulosus* have also reported similar findings.

The condition factor (K) which is a measure of fish energy reserves exhibits inter-annual variations and seasonal cycles in fish (Lambert and Dutil, 1997). In the present study, K values in both the sexes increased significantly ( $p < 0.05$ ) with the advancement of sexual maturity and directly correlated to each other. Similar observation was made by Gopalkrishnan (1991) in *Mugil cephalus*; Hernandez *et al.* (2003) in *Diplodus puntazzo* and by Rao and Krishnan (2009) in *E. diacanthus*.

Table 1. Macroscopic description of gonadal stages of *M. argenteus*

Stage	Ovary	Testis
Immature	Ovaries are small, filiform and translucent with no signs of blood vessels. Adhered to intestine.	Testes are small, translucent and adhered to intestine
Maturing	Early maturing: ovaries are bi-lobed, rounder and wider than earlier stage, occupying almost 1/3 <sup>rd</sup> of the abdominal cavity. Reddish in colour.	Testes are ribbon shaped occupying 1/3 <sup>rd</sup> of the abdominal cavity having whitish colour and are bi-lobed.
	Late maturing: gonad filled almost 2/3 <sup>rd</sup> of the abdominal cavity. Colour reddish yellow. Oocytes 200 $\mu$	
Mature	Mature ovaries light reddish in colour with blood vessels clearly seen	Testes are milky white in colour, turgid with thicker edges.

Table 2. Gonado-somatic index (GSI) and condition factor (K) for different maturity stages of testis in silver moony fish

Size group	Fish		Testis		GSI (%)	K	Stage of maturity
	TL (cm)	TW (g)	L (cm)	W (g)			
10-30 g	8.31 <sup>a</sup> ± 0.23	12.50 <sup>a</sup> ± 0.55	0.65 <sup>a</sup> ± 0.89	0.029 <sup>a</sup> ± 0.55	0.23 <sup>a</sup> ± 0.13	2.10 <sup>a</sup> ± 0.59	Immature
30-50 g	12.85 <sup>b</sup> ± 0.03	47.82 <sup>b</sup> ± 0.34	0.70 <sup>b</sup> ± 0.94	0.215 <sup>b</sup> ± 0.54	0.45 <sup>b</sup> ± 0.32	2.25 <sup>b</sup> ± 0.76	Maturing
50 - 55 g	13.16 <sup>c</sup> ± 0.54	51.20 <sup>c</sup> ± 0.33	2.80 <sup>c</sup> ± 0.45	0.316 <sup>c</sup> ± 0.67	0.62 <sup>c</sup> ± 0.45	2.26 <sup>c</sup> ± 0.76	Mature

Values are expressed as mean ± SE (n=30)

Mean value in the column under each category with different superscript differ significantly (p<0.05)

Table 3. Gonado-somatic index (GSI) and condition factor (K) for different maturity stages of ovary in silver moony fish

Size group	Fish		Ovary		GSI (%)	K	Stage of maturity
	TL (cm)	TW (g)	L (cm)	W (g)			
10-30 g	8.66 <sup>a</sup> ± 0.33	13.45 <sup>a</sup> ± 0.67	0.58 <sup>a</sup> ± 0.54	0.031 <sup>a</sup> ± 0.89	0.23 <sup>a</sup> ± 0.54	2.07 <sup>a</sup> ± 0.76	Immature
30-50 g	12.70 <sup>b</sup> ± 0.98	47.45 <sup>b</sup> ± 0.56	0.74 <sup>b</sup> ± 0.67	0.235 <sup>b</sup> ± 0.76	0.50 <sup>b</sup> ± 0.53	2.32 <sup>b</sup> ± 0.56	Maturing
50 - 55 g	13.00 <sup>c</sup> ± 0.45	53.00 <sup>c</sup> ± 0.32	2.30 <sup>c</sup> ± 0.45	0.380 <sup>c</sup> ± 0.65	0.72 <sup>c</sup> ± 0.24	2.41 <sup>c</sup> ± 0.89	Mature

Values are expressed as mean ± SE (n=30)

Mean value in the column under each category with different superscript differ significantly (p<0.05).

The GSI showed linear relation with total length and wet weight of the male fish. The regression equation of GSI on total length and wet weight is expressed as :  $GSI = 0.0665 TL - 0.3279$  ( $r^2 = 0.8536$ );  $GSI = 0.0085 TW + 0.1173$  ( $r^2 = 0.8687$ ) respectively. Similar trend was observed for female and the regression equation of GSI on total length and weight can be expressed as:  $GSI = 0.0932 TL - 0.5836$  ( $r^2 = 0.8436$ );  $GSI = 0.0108 TW + 0.0723$  ( $r^2 = 0.892$ ) respectively. Higher value of  $r^2$  indicates the higher coefficient of correlation between GSI with total length as well as weight of both the sexes, which is similar to the finding of Rao and Krishnan (2009) in *E. diacanthus*.

Histological observation of immature testis reveals the pre-spermatogenic stage of testis which is characterised by the presence of only spermatogonia cells (Fig. 1). Histological sections of maturing testis showed the presence of early and mid spermatogenic stages. Early spermatogenic stage is predominantly characterised by the presence of spermatocytes and spermatids with few spermatozoa (Fig. 2) and the mid-spermatogenic stage contains approximately equal

numbers of spermatocytes, spermatids and spermatozoa (Fig. 3). The mean size of the silver moony fish in this stage was  $47.82 g \pm 0.34$ . Mature testis in late-spermatogenic stage has more spermatozoa (Fig. 4). The mean weight of the silver moony fish in this stage was  $51.2 g \pm 0.33$ . Oozing male was observed during the months from August to November.

In immature females, the diameter of oocytes ranged between 23 to 41  $\mu m$ . The ovary contains young oocytes, chromatin nucleolar oocytes and perinucleolar oocytes (Fig. 5). Chromatin nucleolar oocytes are more abundant than perinucleolar oocytes. Chromatin nucleolar oocytes are characterised by scant, strongly basophilic cytoplasm and a centrally located nucleus containing a single basophilic nucleolus (Fig. 6). Perinucleolar oocytes are characterised by increased cytoplasmic volumes with less basophilic nature, large nuclei and multiple nucleoli. In maturing group, the diameter of oocytes ranged between 200 to 210  $\mu m$  and the oocytes are in the stage of early vitellogenic stage, which is characterised by the presence of dense cortical alveoli (yolk vesicles) and appearance of yolk granules, with the number and size of

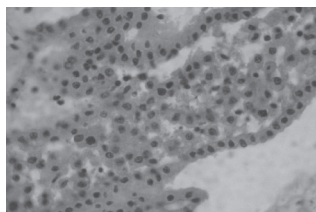


Fig.1. Photomicrograph of immature testis (pre-spermatogenic stage) with spermatogonia cells (H&E; X40)

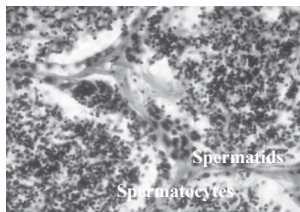


Fig. 2. Maturing testis (early spermatogenic stage) showing predominantly spermatocytes, and spermatids (H&E; X 100)

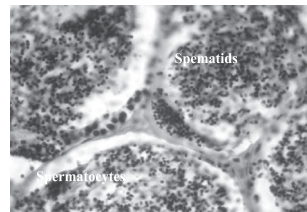


Fig. 3. Maturing testis (mid spermatogenic stage) showing approximately equal numbers of spermatocytes, spermatids and spermatozoa (H&E; X100)

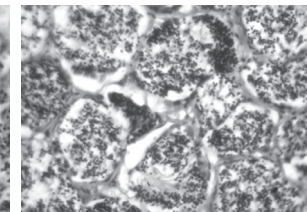


Fig. 4. Mature testis in late spermatogenic stage having more spermatozoa (H&E; X100)

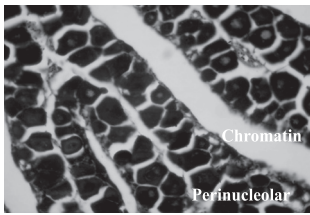


Fig. 5. Photomicrograph of immature ovary showing chromatin nucleolar oocytes and perinucleolar oocytes (H&E; X40)

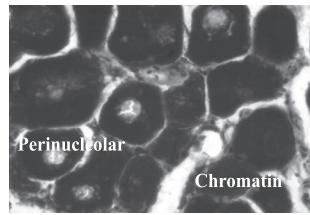


Fig. 6. Photomicrograph of immature ovary showing chromatin nucleolar oocytes and perinucleolar oocytes at higher magnification (H&E; X100)

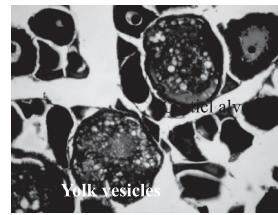


Fig. 7. Photomicrograph of maturing oocytes showing dense yolk vesicles and appearance of yolk granules (H&E; X40)

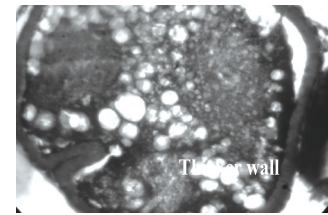


Fig. 8. Photomicrograph of mature oocytes showing dense yolk vesicles and fusion of yolk granules (H&E; X100)

yolk vesicles being more and larger than the yolk granules (Fig. 7). The mean weight of silver moony fish in this stage was  $47.45 \text{ g} \pm 0.56$ . Mature female above  $53 \text{ g} \pm 0.32$  had oocyte diameter ranging between 350 to 410  $\mu\text{m}$ . Histological observations of this stage showed fusion of yolk granules (Fig. 8). Results of the histological studies showed that the advancement of histological changes in ovary and testis and the maturation is in accordance with the increase of GSI value, which is similar to the findings of Johnson *et al.* (1998) in *Epinephelus morio*; Lee *et al.* (2002) in *Epinephelus merra* and Rao and Krishnan (2009) in *E. diacanthus*. The results of the present study indicated that male moon fish mature earlier than that of female of same size group under captive condition and the present findings would be of use in brood stock development and seed production of the species in captivity.

## Acknowledgements

Authors sincerely thank the Director, Central Institute of Brackishwater Aquaculture, Chennai, for providing the necessary facilities to carry out this research.

## References

- APHA 1989. *Standard methods for the examination of water and wastewater*, 17<sup>th</sup> edn. American Public Health Association, Washington D. C., USA, p. 10-203.
- Chatzifotis, S., Muje, P., Pavlidis, M., Agren, J., Paalavuo, M. and Molsa, H. 2004. Evolution of tissue composition and serum metabolites during gonadal development in the common dentex (*Dentex dentex*). *Aquaculture*, 236: 557 – 573.
- Clark, F. N. 1934. Maturity of the Californian sardine (*Sardina caerulea*) determined by ova diameter measurements. *Californian Department Fish and Game for Fish Bulletin*, p. 42-49.
- Fitzhugh, G. R., Thompson, B. and Snider III, T. 1993. Ovarian development, fecundity, and spawning frequency of black drum *Pogonias cromis* in Louisiana. *Fish. Bull., U. S.*, 91: 244-253.
- Goodbred, S. L., Gilliom, R. J., Gross, T. S., Denslow, N. P., Bryant, W. L. and Schoeb, T. R. 1997. Reconnaissance of  $17\beta$ -estradiol, 11-ketotestosterone, vitellogenin, and gonadal histopathology in common carp of United States streams: Potential for contaminant-induced endocrine disruption. *U. S. Geological Survey Open-File Report 96-627*, Sacramento, California, p. 47.
- Gopalakrishnan, A. 1991. *Studies on some aspects of the reproductive physiology of the female grey mullet, Mugil cephalus*. Ph. D. Thesis. Cochin University Science Technology, Cochin, 214 pp.
- Grier, H. J. and Lo Nostro, F. 2000. The teleost germinal epithelium: a unifying concept. In: Norberg, B., Kjesbu, O. S., Taranger, G. L., Andersson, E., and Stefansson, S. O. (Eds.), *Proceedings of the 6<sup>th</sup> International symposium on the reproductive physiology of fish*, July 1999. Institute of Marine Research and University of Bergen, Bergen, Norway, p. 233-236.
- Ha, P. Y. and Kinzie, R. A. 1996. Reproductive biology of *Awaous guamensis*, an amphidromous Hawaiian goby. *Env. Biol. Fish.*, 45: 383-396.
- Hernandez, M. D., Egea, M. A., Rueda, F. M., Martinez, F. J. and Garcia, G. B. 2003. Seasonal condition and body composition changes in sharpsnout seabream (*Diplodus puntazzo*) raised in captivity. *Aquaculture*, 220: 569-580.
- Htun-Han, M. 1978. The reproductive biology of the dab *Limanda limanda* (L.) in the North Sea: Gonado-somatic index, hepato-somatic index and condition factor. *J. Fish Biol.*, 13 (3): 369-378.
- Lambert, Y. and Dutil, J. D. 1997. Can simple condition indices be used to monitor and quantify seasonal changes in the energy reserves of Atlantic cod (*Gadus morhua*). *Can. J. Fish. Aquat. Sci.*, 54: 104 -112.
- Lee, Y. D., Park, S. H., Takemura, A. and Takano, K. 2002. Histological observations of seasonal reproductive and lunar-related spawning cycles in the female honeycomb grouper *Epinephelus merra* in Okinawan waters. *Fish. Sci.*, 68: 872-877.
- Mahnoud, H. Hatem 2009. Gonadal maturation and histological observations of *Epinephelus areolatus* and *Lethrinus nebulosus* in Halaieib Shalatein Area "Red Sea", Egypt. *Global Veterinarian*, 3(5): 414-423.
- Mc Bride, R. S., Stengard, F. J., and Mahmoudi, B. 2002. Maturation and diel reproductive periodicity of round scad (Carangidae: *Decapterus punctatus*). *Mar. Biol.*, 140: 713-722.

- Misra, S. K. 1994. Aspects of reproductive biology of the freshwater teleost, *Anabas testudineus* (Bloch), in south-east India. *The third Asian Fisheries Forum. Asian Fisheries Society*, Manila, Philippines, p. 461-464.
- Patiño, R. and Sullivan, C. V. 2002. Ovarian follicle growth, maturation, and ovulation in teleost fishes. *Fish. Physiol. Biochem.*, 26: 57–70.
- Rao Chandrasekhara, A. and Krishnan, L. 2009. Studies on the reproductive biology of the female spiny cheek grouper, *Epinephelus diacanthus* (Valenciennes, 1928). *Indian J. Fish.*, 56 (2): 87-94.
- Rideout, R. M., Maddock, D. M. and Burton, M. P. M. 1999. Oogenesis and the spawning pattern in Greenland halibut from the North-west Atlantic. *J. Fish Biol.*, 54: 196–207.
- Tessy, K. L. 1994. *Studies on the biology of three cultivable species of Epinephelus from the south-west coast of India*. Ph. D. thesis, Cochin University of Science and Technology, 219 pp.
- Wang, S. P., Sun, C. L. and Yeh, S. Z. 2003. Sex ratios and sexual maturity of swordfish (*Xiphias gladius* L.) in the waters of Taiwan. *Zoological Stud.*, 42(4): 529 – 539.
- Yashiro, R., Vanakal, J., Kongkumnerd, V. and Ruangpanit, N. 1993. Histological changes in gonad of grouper, *Epinephelus malabaricus*. *Proceedings of grouper culture*, NACA, Thailand, p. 16-26.
- Yuen, H. S. H. 1955. Maturity and fecundity of big eye tuna in the Pacific. *Spec. Sci. Rep. Fish.*, 150: 28-30.