



Note

Copepod parasite *Lepeophtheirus kabatai* (Ho & Dojiri, 1977) infestation in orange spotted grouper, *Epinephelus coioides* (Hamilton, 1822) and its control in captivity

RITESH RANJAN, BIJI XAVIER, B. SANTOSH*, SEKAR MEGARAJAN AND SHUBHADEEP GHOSH

Regional Centre of ICAR-Central Marine Fisheries Research Institute, Visakhapatnam - 530 003, Andhra Pradesh, India

*Research Centre of ICAR-Central Marine Fisheries Research Institute, Vizhinjam - 695 521, Kerala, India

e-mail: rranjanfishco@gmail.com

ABSTRACT

Parasitic infection in the orange spotted grouper *Epinephelus coioides* (Hamilton, 1822) and its control measures in captive conditions were studied. Wild collected groupers after 8 weeks of rearing in captivity showed lethargy and sluggishness. The caligid parasite, *Lepeophtheirus kabatai* (Ho & Dojiri, 1977) was identified from the affected fishes. This parasite was also prevalent in wild fish, however at lower prevalence (11%). The mean intensity of *L. kabatai* in fishes reared in captivity was 92.85 ± 10.71 , whereas in wild fish it was 3.54 ± 1.61 . Infected cultured fish were randomly assigned to one of five treatment groups (Group A, B, C, D and E). Group A fishes were given dip treatment in freshwater for 5 min, whereas groups B, C, D and E were given bath treatment in formalin @ 50, 100, 150 and 200 mg l⁻¹ respectively for 30 min, followed by 5 min dip in freshwater. Group E fish were fully free of the infestation and no re-infestation was seen in them even after two months. This is the first study to confirm *L. kabatai* infestation in orange spotted grouper in both wild and cultured fish; and formalin treatment @ 200 mg l⁻¹ was found effective to control the infestation in captivity.

Keywords: *Epinephelus coioides*, Formalin, *Lepeophtheirus kabatai*, Parasite

One of the major constraints in broodstock development is to maintain good health of brood fishes in confined condition. However, maintenance of a healthy fish stock depends on the knowledge of the disease causing agents and on implementation of an effective disease control programme. In groupers, frequent outbreak of parasitic diseases has been observed in broodstocks (Koesharyani *et al.*, 1999) and hence, parasitic infestation seriously hampers their seed production. Ectoparasites, especially parasitic copepod infestation, pose a great threat in the breeding and culture of these fishes in captivity.

Sea lice (Class Copepoda, Family Caligidae) have come under intense scrutiny with the commencement of farming of fishes in sea cages. They are among the most notorious pests affecting wild as well as cultured marine fishes (Chinabut, 1996; Lester and Hayward, 2006). Members of the genera *Lepeophtheirus*, *Caligus* and *Pseudocaligus* in particular, are more popularly reported and cause heavy mortalities (Chinabut, 1996). Caligids of the genera *Caligus* and *Lepeophtheirus* commonly affect farmed marine fishes and cause damages to external body parts, leading to growth retardation, patchy inflammations, osmoregulatory and respiratory failures, secondary microbial infections and mortalities (Boxhall and Defaye,

1993). Parasitic infestations in grouper culture are reported from Malaysia (Leong and Wong, 1988), Kuwait (Al-Marzouq and Al-Rifae, 1994) and Indonesia (Koesharyani *et al.*, 1999) with *Caligus* spp. and *Lepeophtheirus* spp., being the most commonly reported copepod parasites.

ICAR-Central Marine Fisheries Research Institute (ICAR-CMFRI), at the Visakhapatnam Regional Centre is maintaining broodstocks of orange spotted grouper *Epinephelus coioides* (Hamilton, 1822) in cement tanks, a for captive seed production. *E. coioides*, (50 nos, 28.5 ± 8.15 cm, 1.82 ± 1.12 kg) were collected from the wild, near Bhimilipatnam off Visakhapatnam coast of India. These fishes were brought alive to the mariculture hatchery and stocked @ 1 kg m⁻³ in 10 t concrete tanks. All fishes, on external observation, were found healthy and active. The fishes were fed with sardine, scad and squid upto satiation once a day in the morning. Manual cleaning and siphoning of excess feed and faecal matter was done daily in the morning. About 50% water of the experimental tanks was exchanged daily with sand filtered seawater. Salinity of 30-32 ‰, temperature of 27-31°C and dissolved oxygen content of 4.5-6.5 mg l⁻¹ were recorded in the rearing tanks during the experimental period.

The fishes in the culture tanks showed symptoms like lethargy and sluggishness, occasional restlessness and loss of appetite after 8 weeks of rearing in captivity. Thus, it was felt necessary to screen the broodstock for parasitic infestation. Examination for parasitic infestations was carried out adopting the methods suggested by Lucky (1977), Kennedy (1979) and Rohde (1992). All organs of a moribund fish were dissected out and examined under stereozoom microscope. Parasites were collected, washed in tap water, fixed in 7% neutral buffered formalin, washed in distilled water and stored in 70% alcohol. A few specimens of the parasites were examined live and details were recorded. The parasites were later dissected in lactic acid using wooden slide technique (Humes and Goodings, 1964) and identified upto species level. Photomicrographs were taken using WILD MPS 46 microcamera fitted to a Leica Laborlax S microscope. For comparison on the prevalence and intensity between cultured and wild fishes, 100 wild fishes were collected from Visakhapatnam Harbour and were examined for parasite infestation.

Twenty five infested fishes were divided into five groups (Group A, B, C, D and E), randomly with each group comprising 5 fish each and were treated individually in 300 l FRP tanks with vigorous aeration. Group A fishes were given dip treatment in freshwater for 5 min only, while groups B, C, D and E were given bath treatment in formalin (formaldehyde 37%) @ 50, 100, 150 and 200 mg l⁻¹ respectively for 30 min followed by 5 min dip in freshwater. After treatment, fishes were stocked in UV treated fresh seawater in different tanks and the water was filtered through 20 µm mesh net and parasites were collected and counted. The fishes were examined fortnightly to assess the effect of treatment, by external observation as well as by observation of scrapings from the skin, fins and gills under microscope, for 2 months to record re-infestation.

Infested fishes showed slimy dark skin with signs of asphyxia, rapid opercular movement, aggregation on the water surface with gulping the surface water, flashing behaviour and beating the head to the side of tank. Moribund fishes had eroded skin and patchy hemorrhages on the body surface and fins. Gills and all internal organs were pale and covered with mucous. Detailed examination revealed presence of parasites, which were readily visible to the naked eye and were found attached to the eyes, skin, fins and gill filaments of the fishes (Fig. 1). Loss of scales was observed more near the head and eyes.

A single species of caligid parasite, *Lepeophtheirus kabatai* was identified from the moribund and infected cultured fishes. Morphological characteristics of the collected parasite clearly matched with *Lepeophtheirus kabatai* (Figs. 2, 3) as described by Ho and Dojiri (1977).

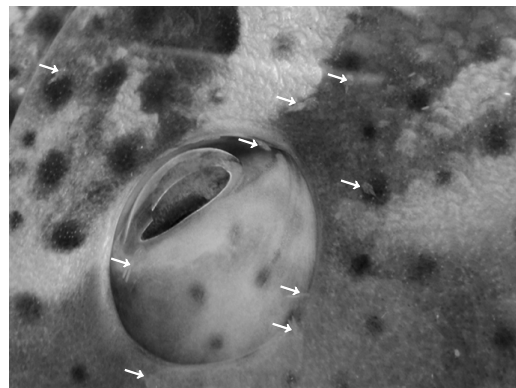


Fig. 1. Parasite *Lepeophtheirus kabatai* attached to the snout region of fish (indicated by arrows)

Originally, Lewis (1968) collected this species from *Epinephelus fuscoguttatus* and *Epinephelus kohleri* and described it as *Lepeophtheirus plectropomi*. Later, Ho and Dojiri (1977) confirmed the specimen described by Lewis (1968) as a new species and named it as *Lepeophtheirus kabatai*. *L. kabatai* closely resembles *L. plectropomi*. In both species, size and shape are mostly similar and the main differences are in the shape of sterna furca, abdomen and second endopod segment in the third leg. The present

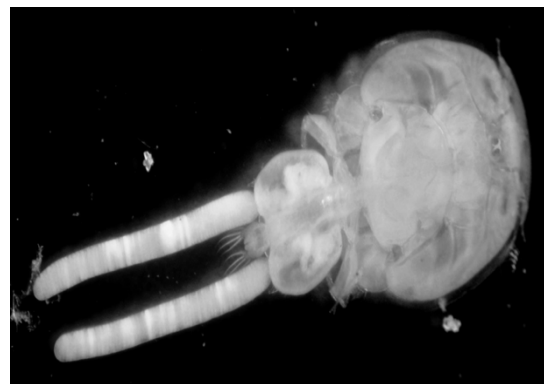

Fig. 2. Female *Lepeophtheirus kabatai* with egg capsule

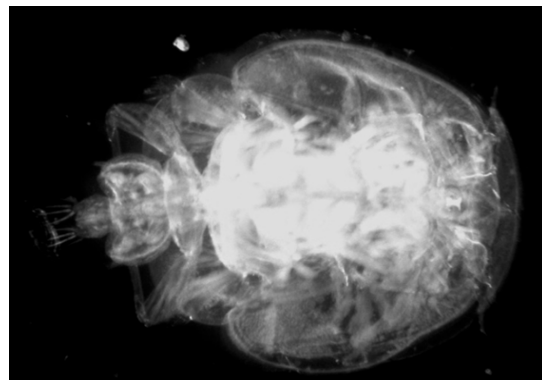


Fig. 3. Male *Lepeophtheirus kabatai*

specimen fully agrees with the original description and also the detailed description given by Prabha and Pillai (1986) from *Plectropomus maculatus* off Thiruvananthapuram coast, India. The present study forms the first record of infestation of the caligid copepod parasite *L. kabatai*, in *E. coioides*. Additionally, this study is the first report of the parasite from the waters of Bay of Bengal.

Caligid infestations are common in nursery, grow-out and broodstock facilities of groupers. These parasites are almost transparent and are not permanently attached to the body surface of the fish. The scales near the infected area become loose and small hemorrhagic spots or ulcers appear. The affected fish had a lumpy body surface, swim sluggishly by near the water surface with occasional flashing behaviour, with loss of appetite and excessive mucus production. Fishes were weak during heavy infestation. Skin and muscle erosion was also observed. Scale sloughing, skin and fin hemorrhages are attributed to continuous irritation caused by the feeding activity of copepodites, chalimus, pre-adults and adults. Salmon lice, *Lepeophtheirus salmonis* uses rasping mouthparts to feed on host mucus, skin and underlying tissue including blood (Brandal *et al.*, 1976; Costello, 2006). Asphyxia and respiratory dysfunction are attributed to damaged gill filaments caused by parasite feeding activity, which resulted in the fish swimming sluggishly near the water surface with occasional flashing behaviour.

The prevalence of *L. kabatai* in fishes reared in captivity was 100% with a mean intensity of 92.85±10.71 (Table 1), whereas in wild collected fishes, prevalence of the parasite was only 11% with a mean intensity of 3.54±1.61. Parasites, though generally harmless in

the wild due to continuous water flow, can flare up and cause mortality and lead to severe economic losses in culture conditions. In captive condition, water exchange is minimal and the natural enemies of these parasites are also absent making the environment congenial for their proliferation and horizontal transmission, resulting in high prevalence and intensity in captive fishes, unlike wild fishes.

Treatment with formalin bath followed by freshwater dip with strong aeration was found effective in controlling the parasite. However, the efficacy of the treatment was found to be dependent on the effective concentration of formalin. A concentration of 200 mg l⁻¹ formalin prevented re-infestation by the same parasite, even after two months of treatment, but fish treated with lower concentrations were found re-infested with the same parasite within 15 days of treatment. This higher concentration (200 mg l⁻¹) is essential to remove all stages of parasite; whereas lower concentrations might not be so effective to eliminate the infection. The group treated with only freshwater dip showed re-infestation the next day itself. Similarly, Rowland *et al.* (2009) also reported higher concentration of formalin upto 30 mg l⁻¹ for effectively controlling ichthyophthiriosis in silver perch, *Bidyanus bidyanus*, whereas lower concentration was not found effective to control all stages of the parasite leading to re-infection. From results of the present study, it is inferred, that immersion treatment with formalin at 200 mg l⁻¹ for 30 min followed by 5 min dip in freshwater is essential to treat *L. kabatai* infection in orange spotted grouper.

Table 1. Infestation prevalence (%) and mean intensity (MI) levels of *L. kabatai* determined from cultured as well as wild collected fish

Source of sample	Examined fishes	Infected fishes	Prevalence (%)	Number of parasites	Intensity (mean ± SE)
Cultured	25	25	100	2321	92.84 ± 10.71
Wild	100	11	11	39	3.54 ± 1.61

Acknowledgements

The authors are thankful to Dr. A. Gopalakrishnan, Director, ICAR-CMFRI, Kochi for providing necessary facilities and constant encouragement. Thanks are due to Dr. Imelda Joseph, Head, Mariculture Division, ICAR-CMFRI, for the continuous support extended during the study period. We are thankful to ICAR, Govt. of India, New Delhi, for financial support.

References

- Al-Marzouq, A. and Al-Rifae, K. 1994. *Benedenia* sp. a monogenetic parasite of cultured brown-spotted grouper, *Epinephelus tauvina*, in Kuwait. *J. Aquac. Trop.*, 9: 255-258.
- Boxshall, G. A. and Defaye, D. 1993. *Pathogens of wild and farmed fish: Sea lice*. Ellis Horwood, 363 pp.
- Brandal, P. O., Egidius, E. and Romslo, I. 1976. Host blood: a major food component for the parasitic copepod *Lepeophtheirus salmonis* Kroyeri, 1838 (Crustacea: Caligidae). *Norw. J. Zool.*, 24: 341-343.
- Chinabut, S. 1996. Sea lice. *AAHRI Newsletter*, 5: 2.
- Costello, M. J. 2006. Ecology of sea lice parasitic on farmed and wild fish. *Trends Parasitol.*, 22: 475-483. DOI:10.1016/j.pt.2006.08.006
- Ho, J. S. and Dojiri, M. 1977. The parasitic copepods on the fishes of the Great Barrier Reef, Australia. Part II. Caligoida: *Dissonus*, *Lepeophtheirus* and *Dentigyrops*.

Publications of the Seto Marine Biological Laboratory, XXIV (1/3): 77-97.

- Humes, A. G. and Gooding, R. U. 1964. A method for studying the external anatomy of copepods. *Crustaceana*, 6(3): 238-240. DOI: 10.1163/156854064X00650.
- Kennedy, M. J. 1979. Basic methods of specimen preparation in parasitology. *IDRC Manu. Rpt. MR*, 8: 44.
- Koesharyani, I., Zafran, K., Yuasa and Hatai, K. 1999. Two species of Capsalid monogeneans infecting cultured humpback grouper *Cromileptes altivelis* in Indonesia. *Fish Pathol.*, 34(3): 165-166. doi.org/10.3147/jsfp.34.165.
- Leong, T. S. and Wong, S. Y. 1988. A comparative study of the parasite fauna of wild and cultured grouper (*Epinephelus malabaricus* Bloch & Schneider) in Malaysia. *Aquaculture*, 68: 203-207. doi.org/10.1016/0044-8486(88)90353-5.
- Lester, R. J. G. and Hayward, C. J. 2006. Phylum Arthropoda, In: Woo, P. T. K. (Ed.), *Fish diseases and disorders vol 1, Protozoan and metazoan infections*, 2nd edn. CAB international, London, p. 466-565.
- Lewis, A. G. 1968. Copepod crustaceans parasitic on fishes of Eniwetok Atoll. *Proceedings of the United State National Museum*, 125: 1-117.
- Lucky, Z. 1977. *Method for the diagnosis of fish diseases*. Amerind Publishing Co., New Delhi, 140 pp.
- Prabha, C. and Pillai, N. K. 1986. Additions to the copepods on the marine fishes of India 4. On twenty six Species of Caligids. *Miscellaneous Publication Occasional Paper No. 79*, Zoological Survey of India, 139 pp.
- Rohde, K. 1992. *Ecology of marine parasites*. C. A. B. International, Oron, UK, 300 pp.
- Rowland, S. J., Mifsud, C., Nixon, M., Read, P. and Landos, M. 2009. Use of formalin and copper to control ichthyophthiriosis in the Australian freshwater fish silver perch (*Bidyanus bidyanus* Mitchell). *Aquac. Res.*, 40: 44-54. doi.org/10.1111/j.1365-2109.2008.02061.x.