

Species-specific Variations in the Gross Anatomy of the Rete mirabile cerebrale in Ox and Sheep

Masuood Ahmad John^{1*}, A.R. Choudhury², Andleeb Rafiq¹, Firdous Ahmad Dar¹, Mohd Yusuf Dar¹, Jasvinder Singh Sasan³ and Mir Shabir Ahmad¹

Department of Veterinary Anatomy and Histology, SKUAST-K, Srinagar, 190001, India,

Received: 20.10.2025; Accepted: 25.12.2025

ABSTRACT

The rete mirabile cerebrale is one of the vital structures associated with the ruminant brain believed to play a crucial role in the cooling of the arterial circulation in this organ. The present study was therefore designed to study this vital structure in sheep and ox so as to observe any comparative differences using both ventral and dorsal approaches. A total of three adult animal heads (N=3), one sheep obtained from slaughterhouse and two male bovine heads collected during post-mortem examination were used for the present study. In ox, the rete mirabile cerebrale consisted of a well-developed rostral epidural rete and a smaller caudal epidural rete. In contrast, sheep possessed only the rostral epidural rete, with complete absence of the caudal rete. The rostral epidural rete was H-shaped in both the ox and sheep. From the present study it was concluded that the arterial blood from vertebral artery has no role in enriching the cerebrum in case of sheep. These findings highlighted species-specific variations in the organization of the rete mirabile cerebrale among ruminants and underscores its potential role in cerebral thermoregulation.

Keywords: Brain, Gross anatomy, Ox, Rete mirabile cerebrale, Sheep,

INTRODUCTION

The rostral rete mirabile cerebrale in ruminants function as a reservoir of pooled blood (KieBtyka-Kurc *et al.*, 2015) which is finally pushed to the arterial circle of brain (Brudnicki, 2011). The rete mirabile cerebrale is closely associated with the brain, including its nerves. Furthermore, the rostral epidural rete mirabile is closely associated with the cavernous sinus, a relationship believed to facilitate cooling of the arterial blood entering the brain (Zdun *et al.*, 2022). In animals like horses, the rete mirabile cerebrale is not present at all. In these animals, guttural pouch has been proposed to help in the cooling of blood supply to brain. Keeping these facts in to consideration, the present study was designed study the comparative anatomy rete mirabilecerebrale in sheep and ox.

MATERIALS AND METHODS

A total of three adult animal heads (N=3), one of sheep (collected from slaughter house) and

two male bovine heads collected during post-mortem examination, were used for the present study. The cranial cavities were then exposed using both the dorsal and the ventral approaches. In the former approach the frontal bone was taken out with the help of saw and the periosteal elevator (Ashwini *et al.*, 2008). The dorsal covering of the dura mater and the entire brain was taken out of the cranial cavity, leaving only the ventral portion of the dura mater and the rete around it. In the ventral approach, the basioccipital, together with the post and presphenoid bones were wedged out with the help of periosteal elevator and the dura mater was cleared off. The wings of the sphenoid bone, the pterygoid process, and a portion of temporal bone were disjunctured with the aid of bone cutter. The dura mater was then cleared off from the cranial periosteum. Immediately two to three incisions were given at the dorsal of the dura mater with intact brain inside. The brains were then immersed in 10% formalin for about a week (Godhino, 1968, Deepthi *et al.*, 2016). The rete was then exposed and photographed.

¹Assistant Professor, ²Professor and Head, ³Assistant Professor, Division of Veterinary Anatomy, SKUAST-J
*Corresponding author: drmasuoodbhat@gmail.com

RESULTS AND DISCUSSION

The Rete mirabile cerebrale was exposed in sheep and ox using both the ventral and the dorsal approach. The rete mirabile cerebrale was formed of a larger rostral epidural rete and a smaller caudal epidural rete in ox (Fig.1). In sheep the rete mirabile cerebrale was represented by only the rostral epidural rete, whereas the caudal rete was completely absent (Fig.2). The rete mirabile cerebrale is a typical feature observed in all ruminants, although not all the ruminants possess caudal epidural rete (Zdun, 2023). Compared to the caudal epidural rete, the rostral epidural rete was a well- developed structure in ox (Ding *et al.*, 2007). In both the sheep and ox, the rostral epidural rete was located around the pituitary gland in the region of inter-peduncular fossa, and closely invested by dura mater. The rostral epidural rete was formed of a right rostral branch and a left rostral branch which were present on the respective sides of the pituitary gland (Fig 1). The rostral epidural rete in ox was comparatively larger and more strongly developed as compared to that of sheep. However, in sheep the two branches of the rostral epidural rete were interconnected by a well-defined transverse branch just behind the pituitary gland (Fig 2). In the current study, in both ox and sheep, the rostral epidural rete was in the form of a capital H- shaped structure, as reported in camel (Jerbi *et al.*, 2016) and bison (Graczyk and Zdun, 2021). In Yak, however, the rostral rete had been reported to be U- shaped (Wang *et al.*, 2012). The rostral epidural rete, being in close association with the cavernous sinus, has been reported to perform the cooling action to the arterial blood flowing towards the brain (Zdun *et al.*, 2022). This might be an adaptation strategy to save the encephalon from the untoward effects of the high temperatures (Zdun, 2023). The caudal epidural rete was formed of a weak network of blood vessels located Just behind the rostral epidural rete (Fig. 3). The caudal epidural rete was connected on either side to its respective rostral epidural rete branch. The two

branches of the caudal epidural rete fused together just at their termination, forming a tail like structure in the region of medulla oblongata (Fig.3). Compared to the rostral epidural rete, the caudal epidural rete was positioned at a relatively lower level. The caudal rete was a weakly developed network present in the region of the medulla in ox only, whereas it was completely absent in sheep. Besides the bovines, the caudal epidural rete has been reported in Suiformes and Hippopotamases (Zdun *et al.*, 2013). The caudal epidural rete serves as a channel for the vertebral and the condylar arterial blood flow into the rete. Thus, unlike sheep, where the caudal epidural rete is absent, the vertebral blood in ox flows through the entire brain due to the communication between the rostral and the caudal rete (Baldwin, 1964). The dorsal approach in large ruminants revealed the rostral epidural rete to be located on the cranial surface of the postsphenoid bone (Fig. 3 and 4). In this region the rostral epidural rete was surrounding the area of pituitary fossa containing pituitary gland. The right and the left rostral rete were interconnected by a weak transverse branch just in front of the dorsum sella (Fig.3). Thus, the entire rostral epidural rete did not exceed beyond the basisphenoid bone. The caudal epidural rete appeared as the extension of the rostral rete, just behind the dorsum sella. The caudal epidural rete was observed in the area of the basi-occipital bone (Fig. 4).

CONCLUSION

The rete mirabile cerebrale shows marked species-specific differences between ox and sheep. The rete mirabile cerebrale in ox was more advanced compared to that of sheep in which the caudal epidural rete was absent. From our findings it may be suggested that the arterial blood from vertebral artery has no role in enriching the cerebrum in case of sheep. These anatomical variations suggested functional adaptations related to cerebral circulation and thermoregulation in ruminants.

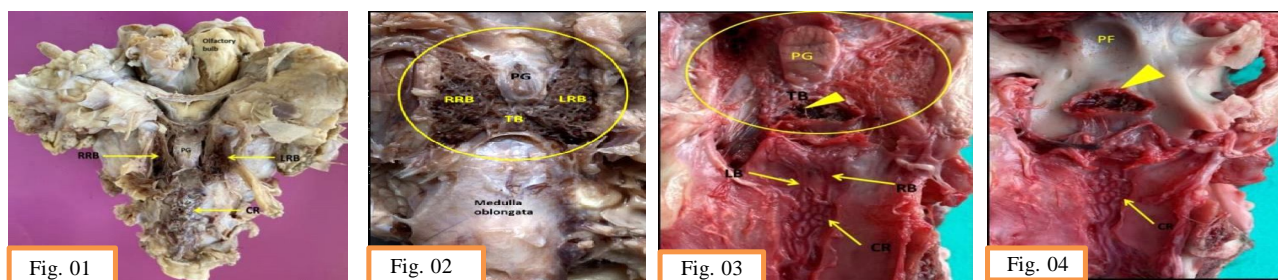


Fig. 1 Ventral view of the rete mirabile cerebrale in ox showing PG (Pituitary gland), LRB (Left rostral branch) RRB (Right rostral branch) and CR (Caudal rete) **Fig. 2** Ventral view of the rete mirabile cerebrale (encircled) in sheep showing PG (Pituitary gland), LRB (Left rostral branch) RRB (Right rostral branch) and TB (Transverse branch), **Fig. 3** Dorsal view of the rete mirabile cerebral showing Rostral rete (Encircled), Pituitary gland (PG), Dorsum sella (arrow head), transverse branch (TB) Pituitary fossa (PF), Left branch (LB), - Right branch (RB) and Caudal rete (CR), **Fig. 4** Cranial view of the postsphenoid & basioccipital bone showing pituitary fossa (PF), dorsum sella (arrow head), and caudal rete (CR); the rostral rete has been cleared off (compare with Fig.3)

REFERENCES

- Ashwini, C.A., Shubha, R. and Jayanthi, K.S. 2008. Comparative anatomy of the circle of Willis in man, cow, sheep, goat, and pig. *Journal of Neuroanatomy*, 7: 54-65.
- Baldwin, B.A. 1964. The anatomy of the arterial supply to the cranial regions of the sheep and ox. *American Journal of Anatomy*, 115:101-107. doi:10.1002/aja.1001150107.
- Brudnicki, W. 2011. Morphometric analysis of the brain base arteries in fallow deer (*Dama dama*). *Veterinarni Medicina*, 56(9): 462-468.
- Deepthi, S., Suseelamma, D., Kumar, D.P., Saradadevi, S. and Subhadradevi, V. 2016. Comparative study of formation of Circle of Willis in human and sheep brain. *Journal of the Anatomical Society of India*, 65: S16-S19.
- Ding, Y., Shao, B. and Wang, J. 2007. The arterial supply to the brain of the yak (*Bos grunniens*). *Annals of Anatomy*, 189(1): 31-38. doi:10.1016/j.aanat.2006.07.011.
- Godhino, H. 1968. A comparative anatomical study of the cranial nerves in goat, sheep and bovine (*Capra hircus*, *Ovis aries* and *Bos taurus*): their distribution and related autonomic components. (PhD), Iowa State University USA. Retrieved from <https://lib.dr.iastate.edu/rd/3241> (6810461)
- Graczyk, S. and Zdun, M. 2021. The structure of the rostral epidural rete mirabile in selected representatives of the Cervidae and Bovidae families. *Acta Zoologica*, 102(4): 496-501.
- Jerbi, H., Khaldi, S. and Pérez, W. 2016. Morphometric study of the rostral epidural rete mirabile in the dromedary (*Camelus dromedarius*, Linnaeus 1758). *International Journal of Morphology*, 34(4): 1429-1435.
- KieBtyka-Kurc, A., Frckowiak, H. and Brudnicki, W. 2015. The arteries of brain base in species of the cervid family. *The Anatomical Record*, 298(4): 735-740.
- Wang, X., Liu, Y., Zhang, L., Wang, X. and Wu, J. 2012. Comparative anatomical study of the epidural retia mirabile in the yak and cattle. *Asian Journal of Animal and Veterinary Advances*, 7(9): 884-890.
- Zdun, M. 2023. Comparison of the rostral epidural rete mirabile and the patterns of its blood supply in selected Suiformes and Hippopotamuses. *Animals*, 13(4): 644.
- Zdun, M., Frckowiak, H., KieBtyka-Kurc, A., Kowalczyk, K., Nabzdyk, M. and Timm, A. 2013. The arteries of brain base in species of Bovini tribe. *The Anatomical Record*, 296(11): 1677-1682. doi:10.1002/ar.22784
- Zdun, M., Melnyk, O.O., Ruszkowski, J.J. and Hetman, M. 2022. Arterial circle of the brain in the common wildebeest (*Connochaetes taurinus*). *The Anatomical Record*, doi:10.1002/ar.25134.