

Histochemical Dynamics of Ovarian Tissue across Developmental Stages in sheep

Mir ShabirAhmad^{1*}, Massarat Khan², Masuood Ahmad John³ A. R. Choudhury⁴, S.A. Shah⁵
Division of Veterinary Anatomy and Histology, Faculty of Veterinary Sciences and Animal Husbandry
SKUAST Kashmir, Shuhama, Alusteng, Srinagar-190 006 (J.&K.) India

Received: 20.10.2025; Accepted: 25.12.2025

ABSTRACT

Seasonal variation had no appreciable effect on histochemical reactions; however, clear age-related differences were observed. Neutral mucopolysaccharides (PAS-positive substances) showed generally weak reactions in prepubertal animals, increasing to mild–moderate intensity in pubertal and adult groups, particularly in follicular components, zona pellucida, corpus luteum, and stroma. Glycogen content was uniformly low or absent across most ovarian structures, irrespective of age. Acid mucopolysaccharides exhibited mild to moderate reactivity in stromal tissue, follicular layers, basement membrane, zona pellucida, and follicular fluid, with comparatively higher activity in developing and tertiary follicles. Basic proteins were consistently present in most ovarian structures with moderate to strong reactions in granulosa cells, basement membranes and zona pellucida of growing follicles. Lipids and phospholipids showed mild to moderate distribution in follicular cells, luteal tissue, and stroma with relatively higher lipid content in prepubertal ovaries and a decreasing trend with advancing age.

Key words: Histochemistry, Ovarian tissue, Follicular development, Sheep

INTRODUCTION

Reproduction in sheep is seasonally regulated, with ovarian activity tightly controlled by photoperiod and associated neuroendocrine mechanisms (Chemineau *et al.*, 2004). These seasonal influences are manifested through cyclical alterations in follicular development, steroidogenesis, ovulation and corpus luteum formation, all of which are reflected in the structural and biochemical dynamics of the ovary. The distribution of glycogen, mucopoly saccharides, lipids, and phosphatases in ovarian follicles, corpus luteum, and stromal components is closely associated with processes such as follicular growth, oocyte maturation, steroidogenesis, luteinization, and follicular atresia (Guraya, 1997). Variations in histochemical reactivity across different follicular stages reflect metabolic and functional heterogeneity within the ovary and provide insight into the physiological competence of follicles. Granulosa and the cells

undergo marked biochemical transformations during folliculogenesis, acquiring steroidogenic capacity and metabolic specialization essential for supporting oocyte development (Fields and Fields, 1996). Similarly, the corpus luteum exhibits intense histochemical activity due to its role as a transient endocrine gland that synthesizes progesterone. Changes in lipid distribution, enzymatic activity and carbohydrate content within luteal cells serve as reliable indicators of luteal function and regression. Moreover, follicular atresia, a process responsible for the loss of a majority of follicles, is associated with characteristic histochemical alterations that reflect cellular degeneration and metabolic disruption (Guigon and Magre, 2006). In the context of Kashmiri sheep, data on the distribution of key biochemical constituents within ovarian tissues across different ages and seasons are virtually non-existent. Such information is essential not only for a deeper understanding of ovarian function but also for refining reproductive management strategies and improving the efficiency of assisted reproductive technologies.

1. Scientist (Animal Science, SKUAST-K); 2. Ret. Prof & Head; 3. Asst. Prof. 4. Prof & Head 5. Asst. Prof. (Pathology);

*corresponding author: shbr.ahmad@gmail.com

MATERIALS AND METHODS

The study was conducted on 30 pairs of ovaries from 30 non-descript ewes of different age groups. The specimens were collected from local slaughter houses. These collected specimens were grouped into prepubertal (0-6 months), pubertal (7-12 months) and adult group (> 1 year) with 10 samples of animals in each group. The approximate age of the animals was determined from their dentition pattern (Sastri *et al.*, 1982). The research was also conducted on the ovaries of 48 clinically healthy non-pregnant local sheep of adult groups, distributed with a minimum of 12 samples in Spring (February-April), Summer (May - July), Autumn (August - October) and Winter (November - January). The parity was determined by history and phase of the sexual cycle of the animal based on the presence of Graafian follicles and corpora lutea on the surface of the ovary. All tissues collected as above were processed by the routine Alcohol- Benzene schedule and paraffin blocks were made (Luna, 1968). Sections 3-5 μ m thickness was cut for histochemical study. Sections of the ovary were stained with standard procedures as indicated in Table.1.

Table 1: Histochemical Techniques Used For Study

1	Periodic Schiff (PAS)	Acid reaction	Neutral mucopolysaccharide	Bancroft and Stevens, 1996
2	Alcian Blue method (at pH 2.5)		Acid mucopolysaccharide	Bancroft and Stevens, 1996
3	Acid haematin		Phospholipids	Chayen <i>et al.</i> 1969
4	Bromophenol blue		Basic proteins	Chayen <i>et al.</i> 1969
5	Best Carmine		Glycogen	Bancroft and Stevens, 1996
6	Sudan black/Oil red O		Lipids	Bancroft and Stevens, 1996

RESULTS AND DISCUSSION

Neutral Mucopolysaccharides and Glycogen (PAS Reaction)

The surface (germinal) epithelium exhibited weak PAS positivity, which was negligible in prepubertal ovaries, while its basement membrane showed mild reactivity (Fig. 1). This pattern is comparable to earlier reports in sheep and buffalo (Rajput and Sharma, 1996; Prasad *et al.*, 1979), although stronger epithelial reactivity has been reported in certain breeds (Bansal *et al.*, 2008; Shehan *et al.*, 2017), suggesting species and breed specific variation. The tunica albuginea demonstrated weak to mild PAS positivity with advancing age but was consistently negative for glycogen in agreement with observations in buffalo and sheep (Dwivedi and Singh, 1971; Bhardwaj and Roy, 1997).

The cortical stroma exhibited heterogeneous PAS reactivity, varying within and between sections (Fig. 2), likely reflecting functional heterogeneity of stromal fibroblasts and the extracellular matrix. Overall, stromal PAS positivity was weak in pubertal/adult animals and negligible in prepubertal sheep, with uniformly low glycogen content. This finding partially corroborates observations in Kendrapada sheep (Sahu *et al.*, 2017) but contrasts with reports of complete PAS negativity in Gaddi sheep (Rajput and Sharma, 1996), underscoring population differences.

Follicular compartments showed stage and age-dependent PAS reactivity. Primordial and primary follicles exhibited trace to mild PAS positivity in granulosa cells and oocytes, with staining intensity increasing with age, consistent with enhanced metabolic activity during follicular recruitment. Secondary follicles displayed weak PAS and glycogen reactivity in granulosa cells and basement membrane, whereas zona pellucida showed moderate to intense PAS positivity (Fig.3),

confirming its glycoprotein-rich composition (Emara *et al.*, 2019) in goats. In tertiary follicles, theca interna and basement membrane showed mild PAS positivity, while granulosa cells were largely negative, consistent with previous observations in sheep and buffalo (Prasad *et al.*, 1979; Rajput and Sharma, 1996). Liquor folliculi exhibited mild PAS reactivity but lacked detectable glycogen.

Atretic follicles showed marked histochemical alterations, characterized by intense PAS positivity in degenerating granulosa cells and moderate reactivity in theca layers and basement membrane, whereas glycogen was absent (Fig.4). These changes likely reflect accumulation of glycoprotein-rich degradation products during follicular regression and are consistent with earlier findings (Bhattacharya and Saigal, 1990).

Corpus luteum exhibited mild to moderate PAS positivity in capsule and trabeculae, with theca lutein cells showing stronger reactivity than granulosa lutein cells (Fig.5). Corpus albicans showed weak PAS positivity, while both structures were consistently negative for glycogen (Table 2.). These findings suggest that neutral mucopolysaccharides contribute to luteal stromal organization rather than serving as energy reserves.

Acid mucopolysaccharides (Alcian Blue Reaction)

Acid mucopolysaccharides (AMPS) were present in trace amounts in surface epithelium and weakly to mildly in tunica albuginea. The cortical stroma showed mild to moderate and regionally variable reactivity, indicating localized extracellular matrix remodeling, similar to observations in Garole sheep (Islam and Das, 2019). Follicular structures demonstrated

progressive enrichment of AMPS with follicular maturation. Primordial and primary follicles exhibited weak to mild reactivity, which increased in secondary follicles, where granulosa cells and basement membrane showed moderate positivity. In tertiary follicles, theca interna and basement membrane exhibited mild to moderate reactivity, while zona pellucida consistently showed moderate to intense staining, reflecting its glycosaminoglycan-rich composition and functional role in fertilization (Table 2).

Atretic follicles showed increased AMPS reactivity in granulosa cells and basement membrane during early atresia (Fig.6), supporting the hypothesis that AMPS accumulation is associated with follicular degeneration and remodelling (Sasan *et al.*, 2013). In advanced atresia, however, reactivity declined, likely due to structural disintegration. Corpus luteum and corpus albicans showed weak to moderate AMPS positivity, suggesting persistence of acidic glycoproteins within luteal connective tissue.

Basic Proteins (Bromophenol Blue Reaction)

Protein localization increased progressively as follicular development progressed. Surface epithelium, tunica albuginea, and stromal tissues exhibited moderate protein positivity. Granulosa cells, basement membrane, and zona pellucida of secondary and tertiary follicles demonstrated moderate to strong positivity, reflecting heightened biosynthetic activity required for follicular growth and oocyte support. Oocytes also showed moderate protein content, indicative of active cytoplasmic maturation (Fig.7). Atretic follicles exhibited diminished protein localization, consistent with degenerative processes. Luteal cells showed weak to moderate positivity, in line with the moderate

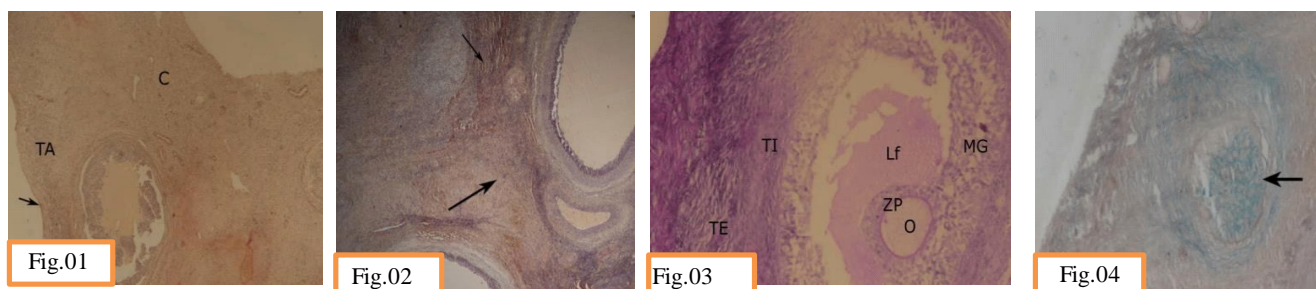


Fig.1 Photomicrograph of prepubertal ovary showing weak PAS reaction in germinal epithelium (arrow), tunica albuginea (TA), and cortex(C). PAS stain.10x **Fig.2** Photomicrograph of adult ovary showing different PAS reaction in the same section (arrow). PAS stain.10x **Fig.3** Photomicrograph of a tertiary follicle showing reaction in theca externa (TE), theca interna (TI), membrana granulosa (MG), Liquor folliculi (Lf), ovum (O), zona pellucida (ZP). PAS stain.20x **Fig.4** Photomicrograph of prepubertal ovary showing PAS reaction in atretic follicle (arrow). PAS-AB stain.20x

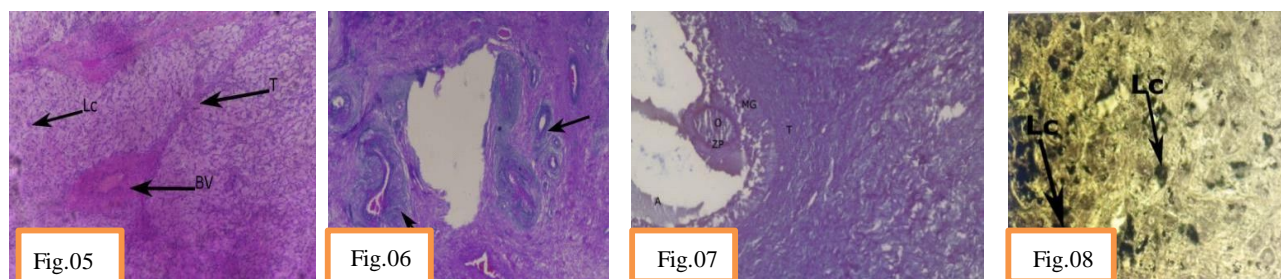


Fig.5 Photomicrograph of adult ovary showing PAS reaction in trabeculae (T), lutein cells (Lc), Blood vessels (BV) of corpus luteum. PAS stain, 20x **Fig.6** Photomicrograph of the ovary showing a strong reaction for acid mucopolysaccharides (AMPS) in an atretic follicle. PAS- AB stain, 10x, **Fig.7** Photomicrograph of pubertal ovary showing strong reaction in maturing follicle for basic proteins in oocyte (O), antrum(A), zona pellucida (ZP), membrane granulosa (MG) and theca (T). Bromphenol Blue stain, 20x, **Fig. 8** Photomicrograph ovary showing sudanophilic lipids in luteal cells of corpus luteum (arrow). Sudan Black B stain, 40x.

protein synthetic activity reported during luteal maturation (Singh, 1994).

Lipids and Phospholipids

Lipid localization showed clear age and stage dependent patterns. Surface epithelium, tunica albuginea, and stroma exhibited mild lipid positivity with higher levels in prepubertal ovaries that progressively declined with age (Table 2). This trend suggests utilization of lipid reserves during ovarian maturation. Primordial and primary follicles in prepubertal animals contained abundant sudanophilic lipid droplets, supporting earlier hypotheses that lipid accumulation is associated with early follicular (Guraya, 1997). growth and developmental programming. In secondary and

tertiary follicles, granulosa cells, theca cells, and oocytes exhibited mild to moderate lipid positivity, whereas the basement membrane and antrum were weakly positive. Zona pellucida showed negligible lipid content. Atretic follicles exhibited increased lipid accumulation in granulosa and theca cells, Histochemical dynamics of ovarian tissue in sheep consistent with the view that lipid deposition accompanies cellular degeneration. Corpus luteum exhibited mild to moderate lipid and phospholipid positivity in luteal cells, consistent with their role in steroidogenesis as lipids serve as precursors for progesterone synthesis (Fig.8). Corpus albicans and medullary stroma also demonstrated moderate lipid reactivity, reflecting persistence of residual lipid material following luteal regression.

Table 2. Histo-chemical observation of different components in the ovary of sheep.

Parameters	PAS	AMPS	Glycogen	Basic proteins	Lipids/ Phospholipids
Germinal epithelium	± to +	+	-	± to ++	± to +
Tunica albuginea	± to +	± to +	-	++	+ to ++
Cortical stroma	± to +	+ to ++	-to ±	++	+ to ++
Primordial/primary follicle and ova	± to +	± to +	-to±	+to ++	+
Secondary follicle					
Theca folliculi	± to +	± to ++	±	± to ++	+ to ++
Basement membrane	±	++	+	++	±
Membrana granulosa	±	++	+	++ to +++	+ to ++
Zona pellucida	++to +++	+	-	++	-to+
Ovum	+	±	+	± to ++	++
Tertiary follicle					
Theca externa	±	±	-	++	+
Theca interna	± to +	+	-	++	+ to ++
Basement membrane	+	+ to ++	-	++	±
Membrana granulosa	-	± to +	+	++ to +++	+++
Zona pellucida	++ to +++	++ to +++	-to ±	++ to +++	-to+
Ovum	±	+ to+++	+	++	+ to ++
Liquor follicle	+	++ to+++	-	± to ++	+
Atretic follicle					
Theca externa	+	± to+	-	± to +	+
Theca interna	++	+ to++	-	± to+	++
Basement membrane	+ to +++	- to +++		± to+	±
Membrana granulosa	+++	+ to+++	-	± to+	+to++
Zona pellucida	+to +++	±	-	±	-to ±
Ovum	± to +	±	-	±	++
uor follicle	+	+ to++	-	± to +	±
Corpus luteum					
Capsule &trabeculae	+ to ++	- to ++	-	++	+to++
Granulosa lutein cell	+	± to +	-	±to +	+to++
Theca lutein cells	++	- to ±	-	± to ++	++to+++
Spindle shaped cells	++	+	-	± to ++	-
Corpus albicans	- to ±	+	-	+	++
Medullary stroma	+ to ++	- to +	-to +	++	++to+++

- = Negative ± = In traces/weak + = Mild Reaction ++=Moderate reaction +++= Intense reaction

REFERENCES

- Bancroft, J.D. and Stevens, A. 1996. *Theory and practice Practice of Histological Techniques*. 4th Ed. Churchill and Livingstone. London.
- Bansal, N., Uppal, V. and Kumar, A. 2008. Histomorphometrical and histochemical studies on the ovaries of domestic cat (*Felis catus*). *Indian Journal of Animal Sciences*, 78(2): 175-177.
- Bhardwaj, R.L. and Roy, K.S. 1997. Age related histochemical studies on the ovary of Indian buffalo (*Bubalus bubalis*). *Indian Journal of Veterinary Anatomy*, 9(1/2): 1-14.
- Bhattacharya, M. and Saigal, R.P. 1990. Histo-enzyme studies on the goat ovarian steroid secreting cells. *Indian Journal of Animal Sciences*, 60 : 398-400.
- Chayen, J., Butcher, R.G, Bitensky, L. and Poulter, L.W. 1969. A Guide to Practical Histochemistry. pp 83-174.
- Chemineau, P., Malpoux, B., Delgadillo, J.A., Gurein, Y., Ravault, J.P., Thimonier, J. and Pelletier, J. 2004. Control of sheep and goat reproduction: use of light and melatonin. *Animal Reproduction Science*, 30: 157-184.
- Dwivedi, J.N. and Singh, C.M. 1971. Histochemical Observations on the Ovary of Indian Buffalo. *Indian Journal of Animal Health*, 10: 205-211.
- Emara, S.A., Hassanin, A.M.A. and Elnagar, H.Y. 2019. Histological and Histochemical Changes of The Ovary of Goat During Autumn and Summer Seasons. *Journal of Current Veterinary Research*, 2: 47-54.
- Fields, M.J. and Fields, P.A. 1996. Morphological characteristics of the bovine corpus luteum during the estrous cycle and pregnancy. *Theriogenology*, 45: 1295-1326.
- Guigon, C.J. and Magre, S. 2006. Contribution of germ cells to the differentiation and maturation of the ovary: insight from models of germ cell depletion. *Biology of Reproduction*, 75: 450-58.
- Guraya, S.S. 1997. Ovarian Biology in Buffaloes and Cattle. Indian Council of Agricultural Research, New Delhi.
- Islam, M.M. and Das, P. 2019. Histomorphological Study on Gravid and Non-Gravid Ovaries of Garole Sheep. *Indian Journal of Veterinary Anatomy*, 31(1): 49-51.
- Luna, L.G. 1968. Manual of histological staining methods of the Armed forces institute of Pathology, 3rd Edn. The Blakistan Division, Mo-Graw Hill Book Company, New York
- Prasad, M., Venugopal, S.P and Babu, R.S. 2017. A gross and histological study of human foetal ovary at different weeks of gestation. *International Journal of Anatomy and Research*, 5(2): 4006-11
- Rajput, R. and Sharma, D.N. 1996. Histological and histochemical studies on the ovary of cyclic Gaddi sheep. *Indian Veterinary Journal*, 73(7): 757-761.
- Sahu, S.K., Das, R.K., Sathapathy, S., Mishra, U.K and Dash, S.K. 2017. Gross, histological and histochemical studies on the ovary and oviduct of Kendrapada sheep (*Ovis aries*) at different age groups. *Journal of Entomology and Zoology Studies*, 5: 2319-2324.
- Sasan, J.S., Uppal, V. and Bansal, N. 2013. Histochemical localization of mucopolysaccharides, proteins and lipids in ovarian tissue: A seasonal study. *Indian Journal of Animal Sciences*, 83(2): 150-153.
- Sastry, N.S.R., Thomas, C.K. and Singh, R.A. 1982. Farm Animal Management and Poultry Production, Fifth Edition. Vikas Publishing House, New Delhi pp. 15-28.
- Shehan, N.A., Adel Kareem, D. and Ali, S.A. 2017. Morphological and Histological of Ovary in Domestic Iraqi Sheep (*Ovis aries*). *International Journal of Science and Research*, 6(2): 284-291.
- Singh, O. 1994. Histomorphological and histochemical studies on corpus luteum of buffalo (*Bubalus bubalis*). M.V.Sc. Thesis, Punjab Agricultural University, Ludhiana, India.