

## Trichological Analysis on Hair of Sahiwal Cattle

P. Rawat<sup>1</sup>, S.K.Gupta<sup>2\*</sup>, Y. Pandey<sup>3</sup>, B.P.Shukla<sup>4</sup> and N.Shrivastava<sup>5</sup>

Department of Veterinary Anatomy and Histology, College of Veterinary Science and A.H., MHOW  
Nanaji Deshmukh Veterinary Science University, M.P.

Received: 14.09.2025; Accepted :21.12.2025

### ABSTRACT

For trichological analysis guard hair from back, neck, umbilical and tail regions of sahiwal cattle were collected. The colour, shape and band pattern of hair was examined to know the gross profile of hair. The cuticular impressions were prepared in a thin gelatin layer on a clean glass slide for assessment of cuticular scale pattern. For medullary configuration observation hair specimen was prepared with xylene. The physical characteristic of hair like colour, shape and band pattern showed huge variation in the same individual from region to region. The hair of sahiwal cattle were flat in all body regions. Microscopically the hair was composed of cuticle, cortex and medulla from outer to inner side. The cuticular scales were in the form of regular waves with smooth margin in back, neck and tail region and crenate margin in umbilical region. Hair medulla was continuous in back region but in neck, umbilical and tail regions it was fragmented. The margins of the medulla in all the body regions were scalloped type except in tail region where it was smooth. The medullary index was more than half, it showed that the medulla form more diameter of hair than the cortex.

**Key words:** Cattle, Cuticle, Hair, Medulla, Sahiwal, Trichological

### INTRODUCTION

The morphological characteristics of hair vary from species to species. These features are an important tool for identification of animal species. The mammalian hair represent an interesting biological material which can be easily sampled, collected and transported as well as resist putrefaction and remain for very long periods of time so could provide long-term information. This study was conducted on hair of Sahiwal breed of cattle with the objectives of gross, microscopic and scanning electron microscopic examination. Because the hair are the most common biological evidence encountered during the course of veterolegal investigation (Farag *et al.*, 2015).

### MATERIALS AND METHODS

The study was carried out in the Department of Veterinary Anatomy and Histology, College of Veterinary Science and Animal Husbandry, Mhow, Nanaji Deshmukh Veterinary Science University, Jabalpur (M.P.). For present study six guard hairs from each body region (back, neck, umbilical and tail regions) from six adult and apparently healthy

Sahiwal breed of cattle irrespective of sex were collected from the Livestock Farm Complex of College and nearby private livestock farms of Indore region. The shedded gourd hair were collected by combing different body regions and for this proper permission was taken from IAEC. The colour, shape and band pattern of hair were observed by gross examination. The hair profile was studied by moving the hair between thumb and index finger. For assessment of cuticular scale pattern of hair, the cuticular impressions were prepared in a thin gelatin layer on a clean glass slide and examined under the light microscope to know the detail structure of hair cuticle of animals as describe by Teerink (1991). For this 10 gm gelatine was dissolve in 100 mL of boiling water. Once the gel is formed, a thin layer was spread on a clean glass slide. The hair was placed superficially over the gelatine layer and allowed to cool for about 2-3 hours. Then the hair was removed and a pattern of cuticular impression was study under the light microscope. For medullary configuration study each hair specimen was cleaned and cleared with xylene then mounted on microscopic slide in a drop of DPX for light microscopic observations. For this the hair were washed in detergent water for 6 to 8 hours, rinsed in water and distilled water. These were allowed to react in 70 percent alcohol for 12

All authors from Department of Veterinary Anatomy and Histology, College of Veterinary Science and A.H., MHOW, Nanaji Deshmukh Veterinary Science University, M.P.

\*Corresponding author Email: vetskgupta@gmail.com

hours, clear with xylene for 12 hours and allowed in paraffin oil for 45 minutes (Teerink, 1991). After preparation of these slides the numerical measurement in micron for both cortex and medulla width were taken using an ocular micrometer. The medullary index of hair was calculated by dividing the average width of medulla with the average diameter of hair. For scanning electron microscopic examination, the hair sample was fixed in 3% glutaraldehyde buffered with 0.1M phosphate buffer at room temperature and carried to Department of Metallurgical Engineering and Materials Science, IIT Indore (M.P.) for detailed hair cuticular observations. The middle part of guard hair was considered for SEM as a representative. The cuticular scales of guard hair were observed at 500X, 1000X, 2500X, 5000X magnification under scanning electron microscope.

## RESULTS AND DISCUSSION

Hair was composed of three layers of cells, keratinized cuticle making up the outer layer, cortex forming the middle layer and medulla the inner layer. The present trichological analysis on guard hair of Sahiwal cattle was conducted by gross, microscopic, micrometrical and scanning electron microscopic observations.

### Gross Examination of Hair:

The physical characteristics of hair like colour, band pattern and hair profile showed huge variations in the same individual from region to region in the animal species. So, these features of hair could not be considered as an important tool for species identification from hair. These findings were in accordance with the observations of Sarkar *et al.* (2011), who mentioned that the coat of mammalian species varies with season, habitat and sex of the individuals.

Hair colour depends on the pigments present in the hair and on the other physical properties that affect how light is transmitted through the hair. The hair of sahiwal cattle the hair were light brown and black coloured. No colour bands were observed. Hair showed curved hair profile at all the body regions except tail. The hair of tail region were slightly wavy as reported earlier by Koppikar and Sabnis (1976) in cattle.

The hair of sahiwal cattle were flat in all body regions. Kushwah (2024) reported flat configuration in hairs of sambar and black deer and cylindrical configuration in the hair of deer and Nilgai. No band pattern was seen in any body region of Sahiwal cattle, However, Kushwah (2024) reported band pattern in the hair of tail region of sambar and back region of deer.

### Microscopic Examination of Hair:

#### Cuticular scale pattern:

In sahiwal cattle the cuticular scales were arranged in the form of regular waves of imbricate patterns in all body regions (Figs. 1- 4) as reported in cow by Ahmed *et al.* (2018) and Yasser *et al.* (2018). However Mukherjee *et al.* (2016) reported that domestic cow has irregular waves with crenate scale margins and Lungu *et al.* (2007) reported flattened and deep imbricated scale at an oblique angle. Verma and Joshi (2012) reported imbricate scale patterns without protrusion in the shaft of jersey cow.

The scale margin was smooth in back, neck and tail region but crenate in umbilical region (Figs. 1- 4). Crenate margin in cow were reported by Ahmed *et al.* (2018), Yasser *et al.* showed reddish brown colour especially at back, neck and umbilical region, while at tail region (2018) and Mukherjee *et al.* (2016). While, flattened imbricate margin in cow was reported by Bhosale *et al.* (2019). Whereas smooth margin were present in sheep (Yasser *et al.*, 2018) and goat (Das *et al.*, 2018).

Cuticular scale were placed nearly in back and tail region while closely in neck and umbilical regions. (Figs. 1- 4). Similarly Ahmed *et al.* (2018) and Sarma *et al.* (2021) reported intermediate scale distance in cow. Number of scale per row in the hair of Sahiwal cattle in back, neck and umbilical regions were 1 to 2, but in tail region these were 2 to 3. Similarly, Bhosale *et al.* (2019) reported that cow hair has maximum 3 number of scale count. Bhosale *et al.* (2019) also reported that horse hair has maximum 2 number of scale count but elephant, barking deer, black buck, chinkara hair has maximum 3 number of scale count.

#### Medullary configurations:

It was observed that the medulla was absent

at the tip of hair in all body regions. The medulla tapers from the proximal part of hair towards the tip of hair. The medulla was composed of closely packed, shrunken cells, but unlike cortex they were clearly visible. In concordance with the findings of Krause and Cults (1975) these cells and the air filled spaces between the intercellular connections, were responsible for the specific characteristic of the medulla. The medulla of hair in back region was continuous whereas in all other body regions (neck, umbilical and tail) it was fragmented and narrow. The medullary composition was unicellular with a typical cloisonne pattern (Figs.5- 8). Ahmed *etal.* (2018) in cow reported that medulla was continuous, occupying more than half of the hair shaft, and no pigments were seen in the cortex. Senthilkumaret *al.* (2018) in cow reported that the medullary structure continued into root area and traces of follicular tissue was also observed. Mukherjee *et al.* (2016) in cow reported that the medulla of domestic cow appeared dark and continuous. Verma and Joshi (2012) in jersey cow reported continuous, amorphous or vacuolated medulla without mosaic patterns. Ahmed *etal.* (2018) and Senthilkumaret *al.* (2018) reported fragmented / discontinuous medulla in sheep and continuous medulla in goat.

The margin of the medulla was scalloped type in back, neck and umbilical regions but smooth in tail region of sahiwal cattle (Figs. 5- 8). However, Mukherjee *et al.* (2016) reported that the medulla of domestic cow has straight margin. Ahmed *et al.* (2018) in sheep and Mukherjee *et al.* (2016) in camel and donkey reported smooth margins but serrated in goat. Ahmed *et al.* (2018) and Senthilkumaret *al.* (2018) also reported serrated margin in horse.

#### **Micrometrical features of hair:**

The hair shaft diameter, showed variations throughout the length, therefore the diameter/ width of the hair was measured at mid of the shaft. In present study the highest medullary index was noted in the hair of tail region (0.81) and lowest in the neck region (0.33).

In sahiwal cattle the average length and width of the hair in back, neck, umbilical and tail regions were  $10.75 \pm 0.22$  mm &  $66.71 \pm 3.51$   $\mu$ m;  $16.80$

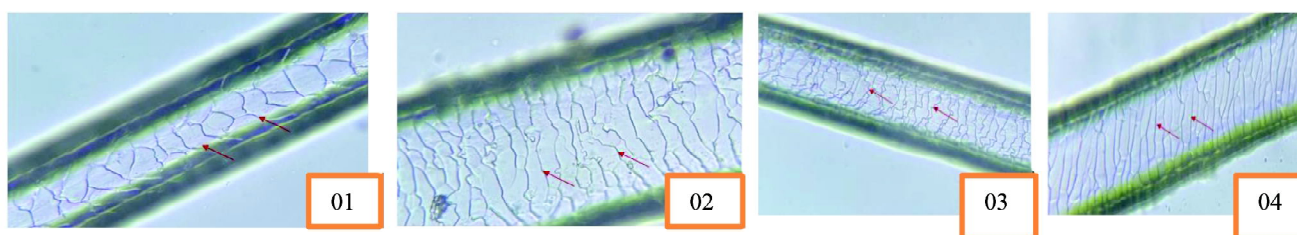
$\pm 2.49$  mm &  $67.03 \pm 3.47$   $\mu$ m;  $26.73 \pm 0.27$  mm &  $57.96 \pm 5.01$   $\mu$ m and  $38.45$  mm  $\pm 0.33$  &  $85.65 \pm 6.11$   $\mu$ m, respectively. However, Senthilkumaret *al.* (2018) reported hair width in scapular region, lumbar region and croup region as  $94.12 \pm 0.52$   $\mu$ m,  $94.18 \pm 0.93$   $\mu$ m and  $82.86 \pm 0.91$   $\mu$ m in cattle,  $161.40 \pm 0.90$   $\mu$ m,  $194.45 \pm 0.35$   $\mu$ m and  $145.80 \pm 1.02$   $\mu$ m in sheep,  $122.50 \pm 0.37$   $\mu$ m,  $141.10 \pm 0.86$   $\mu$ m and  $75.13 \pm 1.62$   $\mu$ m in goat and  $82.95 \pm 0.40$   $\mu$ m,  $60.32 \pm 0.89$   $\mu$ m and  $72.71 \pm 0.52$   $\mu$ m in horse, respectively.

Average thickness of one side cortex and diameter of medulla in the hair of back, neck, umbilical and tail regions were  $16.01 \pm 0.75$   $\mu$ m &  $34.68 \pm 1.35$   $\mu$ m;  $22.46 \pm 1.01$   $\mu$ m &  $22.11 \pm 1.01$   $\mu$ m;  $11.88 \pm 0.95$   $\mu$ m &  $34.19 \pm 2.02$   $\mu$ m; and  $8.14 \pm 0.80$   $\mu$ m &  $69.37 \pm 3.12$   $\mu$ m, respectively. Senthilkumaret *al.* (2018) reported diameter of medulla in scapular region, lumbar region and croup region as  $59.16 \pm 0.83$   $\mu$ m,  $42.96 \pm 1.31$   $\mu$ m and  $42.21 \pm 0.53$   $\mu$ m in cattle,  $115.37 \pm 0.89$   $\mu$ m,  $157.16 \pm 0.68$   $\mu$ m and  $106.82 \pm 0.31$   $\mu$ m in sheep,  $97.08 \pm 0.55$   $\mu$ m,  $107.54 \pm 0.83$   $\mu$ m and  $52.24 \pm 0.57$   $\mu$ m in goat and  $57.79 \pm 0.74$   $\mu$ m,  $18.92 \pm 0.24$   $\mu$ m and  $8.14 \pm 0.47$   $\mu$ m in horse, respectively.


The medullary index showed much variation from 0.33 to 0.81 in different body regions. It was 0.52, 0.33, 0.59 and 0.81 in back, neck, umbilical and tail region, respectively in sahiwal cattle. Senthilkumaret *al.* (2018) reported medullary index in scapular region, lumbar region and croup region as 0.62, 0.47 and 0.49 in cattle, 0.71, 0.80 and 0.74 in sheep, 0.79, 0.76 and 0.69 in goat and 0.47, 0.31 and 0.11 in horse, respectively.

#### **Scanning Electron Microscopic Examination of Hair:**


The scanning electron microscopic findings of the present study revealed that the cuticular scales of guard hair showed free cuticular scale margins, directed towards the tip or distal part of the hair shaft in concurrence with the observations of Rajaram and Menon (1986) in porcupine. In sahiwal cattle the cuticular scale of hair in all the body regions (back, neck, umbilical and regions) were positioned transversely. These cuticular scale were arranged in the form of regular waves of imbricate patterns and the distance between the scale margin was near in all the body region. Free surface was slightly convex in back, neck,



**Fig.1.** Cuticular scale patterns in hair of back region in sahiwal cattle showing transversal scales in regular wavy pattern with smooth margin (X 400).**Fig. 2.** Cuticular scale patterns in hair of neck region in sahiwal cattle showing, transversal scales in regular wavy pattern with smooth margin (X 400).**Fig. 3.** Cuticular scale patterns in hair of umbilical region in sahiwal cattle showing, transversal scales in regular wavy pattern with crenate margin (X 400).**Fig. 4.** Cuticular scale patterns in hair of tail region in sahiwal cattle showing, transversal scales in regular wavy pattern with smooth margin (X 400).



**Fig. 5.** Hair of back region of sahiwal cattle showing **Fig. 6.** Hair of neck region of sahiwal cattle showing, **Fig. 7.** Hair of umbilical region of sahiwal cattle showing **Fig. 8.** Hair of tail region of sahiwal cattle showing A-Medulla having cloisonne pattern, B- Scalloped margin C-Thick cortex(X 1000).



**Fig. 9.** Cuticular scale patterns of hair in back region of sahiwal cattle under SEM at X 1000, **Fig. 10.** Cuticular scale patterns of hair in neck region of sahiwal cattle under SEM at X 1000 **Fig. 11.** Cuticular scale patterns of hair in umbilical region of sahiwal cattle under SEM at X 5000, **Fig. 12.** Cuticular scale patterns of hair in tail region of sahiwal cattle under SEM at X 5000.

umbilical and tail region. The free margin of these scale were thin and smooth in back and neck but thin and irregular in umbilical and tail region (Figs. 9- 12). The observations of the present study regarding transversely arranged cuticular scale was in agreement with the findings of Verma *et al.* (2016) in spotted deer. Kamalakannan (2017) stated that the cuticular scale patterns was regular wave with smooth margins and had near scale distance in nilgai.

Number of scale per row in back, neck and umbilical regions were 1 to 2, but in tail region these were 2 to 3 (Figs. 9- 12). Similarly Bhosale *et al.* (2019) reported that cow hair has maximum 3 number of scale count. Bhosale *et al.* (2019) also reported that horse hair has maximum 2 number of scale count but elephant, barking deer, black buck, chinkara hair has maximum 3 number of

scale count. The maximum distance between two scale (height of scale) in back, neck, umbilical and tail regions was  $12.42 \pm 0.05 \mu\text{m}$ ,  $7.76 \pm 0.03 \mu\text{m}$ ,  $8.62 \pm 0.03 \mu\text{m}$ , and  $10.71 \pm 0.04 \mu\text{m}$  respectively. The width of the scale in back, neck, umbilical and tail region was  $44.47 \pm 1.97 \mu\text{m}$ ,  $44.68 \mu\text{m} \pm 1.80$ ,  $38.64 \pm 1.55 \mu\text{m}$  and  $34.26 \pm 1.91 \mu\text{m}$ , respectively (Figs. 9- 12).

From the present research findings it is concluded that the physical characteristic of hair like colour, shape and band pattern showed huge variation in the same individual from region to region in the animal species. Differences were recorded in the cuticular pattern and medullary pattern of the hairs. The combination of gross and microscopic characteristics of hair might be important and useful for identification of mammalian hairs.

## REFERENCES

- Ahmed, Y.A., Ali, S. and Ghallab, A. 2018. Hair histology as a tool for forensic identification of some domestic animal species. *Experimental and Clinical Science Journal*, 17: 663-670.
- Bhosale, M.S., Nanhe, B.V. and Sheth, D. D. 2019. SEM studies of some animal hairs with reference to scale pattern and scale count. *Journal of Emerging Technologies and Innovative Research*, 6(6): 783-787.
- Das, S., Sarma, K., Talukdar, M., Rajkhowa, J., Gautam, C., and Deka, S.S.A. 2018. Light and scanning electron microscopy aided with elementary analysis in characterization and identification of hair of Assam hill goat. *Journal of Entomology and Zoology Studies*, 6(3): 1141-1148.
- Farag, M.R., Abou-Hadeed, A.H., Ghoniem, M.H., Alagawany, M., Laudadio, V. and Tufarelli, V. 2015. Chemical composition and mineral contents differentiation in hairs of some wild animal species. *Pakistan Journal of Zoology*, 47(4): 1189-1191.
- Kamalakaran, M. 2017. Identification of dorsal guard hairs of Nilgai Boselaphustrago camelus (Bovidae: Artiodactyla: Mammalia). *Bulletin of Environment Pharmacology and Life Science*, 6(5): 95-98.
- Koppikar, B.R. and Sabnis, J.H. 1976. Identification of hairs of some Indian mammals. *Journal of the Bombay Natural History Society*, 73(1): 5-20.
- Krause, W.J. and Cults, J.H. 1976. Essentials of Histology, pp.405-407.
- Kushwah, V. 2024. Comparative trichological analysis on shedded hair of wild animals from indore zoo. M.V.Sc. thesis (Veterinary Anatomy), Nanaji Deshmukh Veterinary Science University, Jabalpur.
- Lungu, A., Recordati, C., Ferrazzi, V. and Gallazzi, D. 2007. Image analysis of animal hair :Morphological features useful in forensic veterinary medicine. *Lucrari Stiintifice Medicina Veterinary*, 40: 439-446.
- Mukherjee, P., Pasi, C., Patel, S. and Dhurwey, S. 2016. Comparative trichological analysis of common domestic mammals of Jabalpur district. *International Journal of Advance Research in Biological Sciences*, 3(2): 93-98.
- Rajaram, A. and Menon, R.K. 1986. Scanning electron microscope study of the hair keratins of some animals of the Indian subcontinent a preliminary report. *Journal of Bombay Natural History Society*, 83: 427-429.
- Sarkar, P.S., De, J.K. and Manna, C.K. 2011. Identification of dorsal guard hairs of five species of the family cercopithecidae (primates: mammalia). *Current Science*, 100(10):1725-1728.
- Sarma, M., Choudhury, K.B., Singson, A., Ahmed, J. and Sarma, N. 2021. Hair histology and ultrastructure of few wild and semi-wild mammals: a forensic approach. *Indian Journal of Veterinary Sciences and Biotechnology*, 17(4): 66-69.
- Senthilkumar, S., Gnanadevi, R., Kannan, T.A., Arunaman, C.S., and Ramesh, G. 2018. Microanatomical observations of hair in domestic animals: a comparative study. *Journal of Entomology and Zoology Studies*, 6:1925-1925.
- Teerink, B.J. 1991. Hair of West European Mammals: Atlas and Identification Key. Cambridge University Press, Cambridge.
- Verma, A.M., Khan, S., Joshi, P.C., Bahuguna, A. and Dev, K. 2016. Wildlife forensic techniques: DNA extraction from hard biological matter of Chital (*Axis axis*), molecular analysis use of Scanning Electron Microscopic and Energy Dispersive X- ray in species identification. *Journal of Biotechnology and Biochemistry*, 2(7): 104-110.
- Verma, K. and Joshi, B. 2012. Different animal species hairs as biological tool for the forensic assessment of individual identification characteristics from animals of zoological park, pragti maidan, New Delhi, India. *Journal of Forensic Research*,
- Yasser, A.A., Safwat, A. and Ahmed, G. 2018. Hair histology as a tool for forensic identification of some domestic animal species. *Experimental and Clinical Sciences Journal*, 17: 663-670.