

# GASTRO INTESTINAL PARASITIC INFECTIONS IN A DESI FOWL (*Gallus gallus domesticus*) OF CHENNAI, TAMIL NADU- A CASE REPORT

K.T. Kavitha\*<sup>1</sup>, B. Rubinibala<sup>1</sup>, S. Ramesh<sup>2</sup> and Bhaskaran Ravi Latha<sup>3</sup>

Department of Veterinary Parasitology  
Madras Veterinary College  
Tamil Nadu Veterinary and Animal Sciences University  
Chennai, Tamil Nadu, India

## ABSTRACT

Mixed infections with four gastrointestinal parasites were recorded in a desi fowl presented for post mortem in Chennai. The morphological characters of the worms found in the lumen of the gizzard, duodenum and caecum of a desi fowl were studied and the worms were identified as *Ascaridia galli* and *Heterakis gallinarum*. The caecum of a bird showed pathological changes including congestion and haemorrhages. Examination of the intestinal contents revealed the presence of eggs of *A. galli* and *Capillaria* spp along with oocyst of *Eimeria* spp.

**Key words:** Gastrointestinal parasites, Desi fowl, *Ascaridia galli*

Received : 16.02.2022

Revised : 13.05.2022

Accepted : 13.06.2022

Parasitic infections are very common in backyard poultry. In this system the birds feed on the soil, poultry litter and droppings and ingest many intermediate hosts like beetles, ants, earthworms and houseflies which are responsible for transmission of various helminth parasites in the birds (Ananda *et al.*, 2016; Sreedevi *et al.*, 2016). The round worms like *Ascaridia galli* and *Heterakis gallinarum* are the most common parasites which cause loss of body weight, lowered

egg production and sometimes death in young birds (Puttalakshamma *et al.*, 2008).

The growth and development of larval stages of helminth parasites occurs rapidly in the tropical countries like India (Kulkarni *et al.*, 2001). Various workers have reported a high frequency of gastrointestinal parasites in desi birds around the world (Permin *et al.*, 2002; Percy *et al.*, 2012) including India (Bhat *et al.*, 2014; Sreedevi *et al.*, 2016). However, there is limited information on the frequency of endoparasites in desi fowl of Tamil Nadu. The current study intended to record the gastrointestinal parasites affecting desi bird at Chennai.

---

Corresponding author; email: kavitharavi2004@yahoo.com

<sup>1</sup> Assistant Professor

<sup>2</sup> Professor, Department of Veterinary Pathology

<sup>3</sup> Professor and Head

An adult desi fowl was presented for post mortem to Department of Veterinary Pathology, Madras Veterinary College, Chennai. A thorough necropsy was performed on the bird. During post mortem, the round worms were observed in the lumen of the gizzard (Fig. 1), duodenum and caecum (Fig. 2) of the desi fowl.

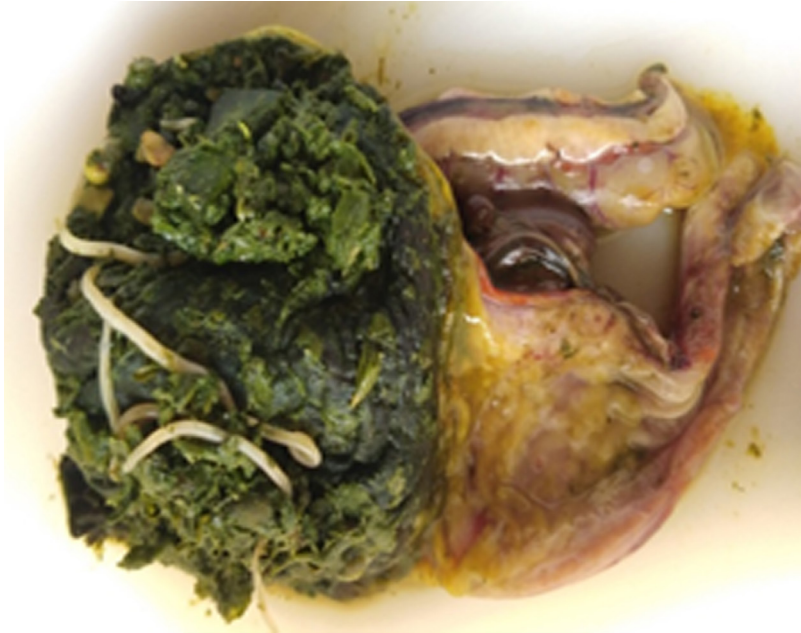The round worms and intestinal contents were collected in the normal saline solution and sent to the Department of Veterinary Parasitology for identification. The worms were processed by standard procedure and cleared in carbolic acid and identified as per Soulsby (1982). The intestinal contents were examined for the presence of parasitic eggs/oocysts using sedimentation and flotation technique and their identification was done using helminthological key.

The worms collected from the gizzard and duodenum were identified as *Ascaridiagalli* based on the morphological characters. The adult worms appeared semi-transparent and yellowish white in colour. Microscopically, the anterior end of the worms showed three prominent lips and club shaped oesophagus without posterior bulb (Fig. 3). The female worm had a simple and straight tail with anal opening at the ventral side of the worm, while the tail end of the male end showed a circular precloacal sucker and equal spicules with curved tail. *Ascaridia galli* is one of the commonest round worms of poultry and has a direct life cycle (Katakam *et al.*, 2010). Brar *et al.* (2016) reported that the adult worm of *A. galli* was rarely found in the lumen of the proventriculus and gizzard of poultry bird. The adult parasite mainly lives in the lumen

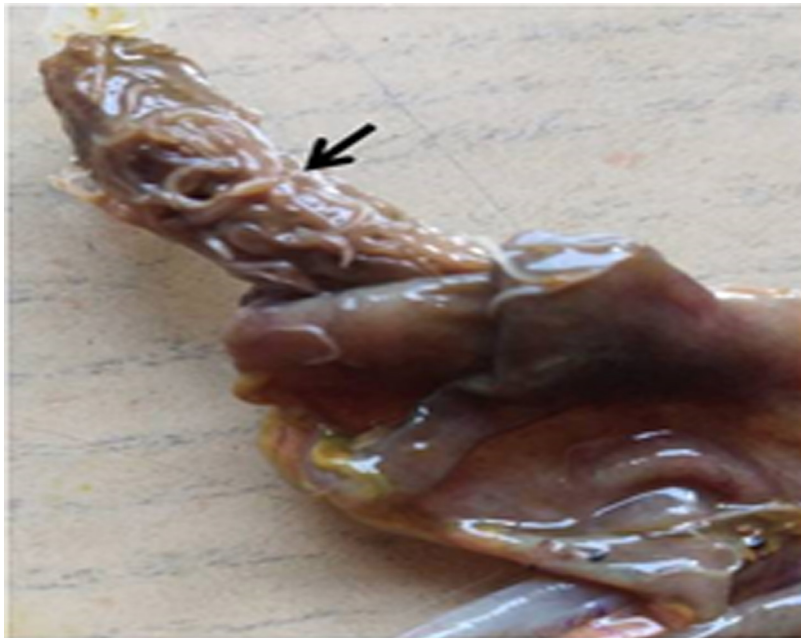of the small intestine (Soulsby, 1982). The unusual location of the adult worms found in this study could be attributed to the fact that when significant numbers of adult worms are present, they may migrate up and down the intestinal lumen (Ikeme, 1971). Mortality due to *A. galli* infection is uncommon in birds, although in very heavy infections death of infected bird may occur due to intestinal obstruction (Puttalakshamma *et al.*, 2008; Katoch *et al.*, 2012).

The worms collected from the caeca were identified as *Heterakis gallinarum*. These worms completely occluded the lumen of caecum (Fig. 2). Microscopically, both male and female worms had a mouth with three lips and the oesophagus had a well developed posterior bulb containing a valvular apparatus (Fig. 4). The male worms had unequal and dissimilar spicules with bent tail. *Heterakis gallinarum* lives in the lumen of caecum and its entire development occurs without any migration in the intestinal wall. So, they cause only mild pathogenic effect in the infected birds. However, it plays the role as a carrier of *Histomonas meleagridis*, the causal protozoa of enterohepatitis "blackhead" of turkeys (Crespo *et al.*, 2018). The caecum of the dead bird also showed pathological changes including congestion and haemorrhages of the mucosa. This could be due to multiple parasitic infections in the caecum.


Examination of the intestinal contents revealed the presence of *A. galli* and *Capillaria* spp eggs along with *Eimeria* spp oocyst. *Ascaridia galli* eggs had thick, smooth shells and were oval in shape.



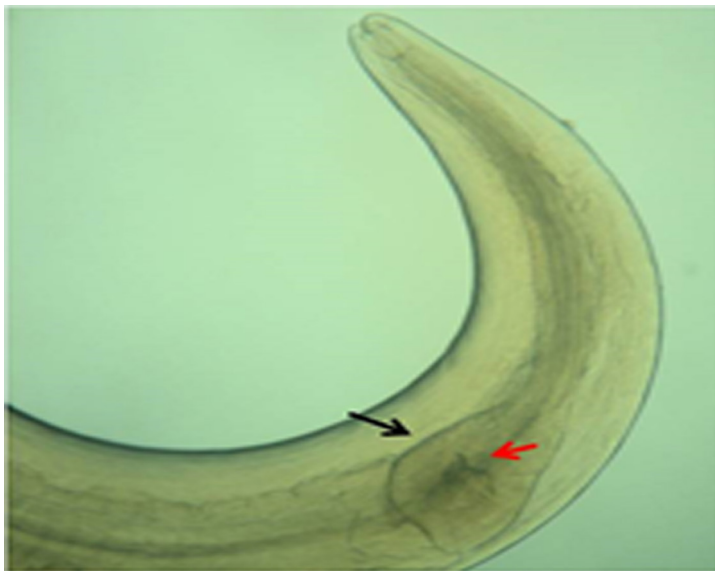**Fig.1: *Ascaridiagalli* worms seen in the gizzard**



**Fig. 2: Caecal lumen fully packed with *Heterakis gallinarum* worms (arrow)**



**Fig.3: *Ascaridia galli* head end showing three lips (arrow head) and club shaped oesophagus (arrow) (40X)**



**Fig. 4: *Heterakis gallinarum* head end (40X) showing oesophagus with prominent posterior bulb (black arrow) containing valvular apparatus (red arrow)**

*Capillaria* eggs were easily identified by the presence of transparent plug at both ends with thick shell and barrel shape. *Eimeria* oocysts were identified based on the spherical shape with two layered wall which containing undifferentiated mass as sporont in the centre. *Capillaria* is a minute, thread-like worm that infects the oesophagus, crop and intestine of chickens. It cannot be seen with the naked eye. The adult worms feed on blood and tissue and cause severe damage to the affected chicken. Many *Capillaria* species have indirect life cycles and require intermediate hosts, such as earthworms, beetles and cockroaches (Morishita and Schaul, 2007). In this study, no adult *Capillaria* worms were recovered. This could be owing to the small size and easy disintegration during post mortem.

Several researchers have reported that the desi birds in the rural free ranging system may be infected with more than one or two gastrointestinal parasites (Hange *et al.*, 2007; Puttalakshamma *et al.*, 2008; Sreedevi *et al.*, 2016). The desi birds are usually raised in the backyard system; with the farmers not following any scientific method of management like feeding or medication. Therefore, these birds are more susceptible to mixed parasitic infections than the birds raised in intensive farming system (Sreedevi *et al.*, 2016).

## REFERENCES

- Ananda, K.J., Kavitha Rani, B., Revanna, S.P. and Udupa, G. (2016). Prevalence of gastro-intestinal parasites of backyard chickens (*Gallus domesticus*) in and around Shimoga. *Journal of Parasitic Diseases*, **40**(3):986-990.
- Bhat, S.A., Khajuria, J.K., Katoch, R., Wani, M.Y. and Dhama, K. (2014). Prevalence of endoparasites in backyard poultry in North Indian region: a performance based assessment study. *Asian Journal of Animal and Veterinary Advances*, **9**:479-488.
- Brar, R.S., Kumar, R., Leishangthem, G. D., Banga, H. S. and Singh, N. D. (2016). *Ascaridia galli* induced ulcerative proventriculitis in a poultry bird. *Journal of Parasitic Diseases*, **40**(2):562-564.
- Crespo, R., Franca, M.S., Fenton, H. and Shiva prasad, H.L. (2018). Galliformes and Columbiformes in Pathology of Wildlife and Zoo Animals. Academic press. 747-773.
- Hange, R.R., Raote, Y.V. and Jayraw, A. K. (2007). Prevalence of helminth parasites in desi fowl (*Gallus gallus domesticus*) at Parbhani. *Journal of Parasitic Diseases*, **31**(1):61-64.
- Ikeme, M.M. (1971). Effects of different levels of nutrition and continuing dosing of poultry with *Ascaridia galli* eggs on the subsequent development of parasite populations. *Parasitology*, **63**: 233-250.
- Katakam, K., Nejsun, P., Kyvsgaard, N., Jorgensen, C. and Thamsborg, S.M. (2010). Molecular and parasitological tools for the study of *Ascaridia galli*

- population dynamics in chickens. *Avian Pathology*, **39**:81-85.
- Katoch, R., Yadav, A., Godara, R., Khajuria, J.K., Borkataki, S. and Sodhi, S.S. (2012). Prevalence and impact of gastrointestinal helminths on body weight gain in backyard chickens in subtropical and humid zone of Jammu, India. *Journal of Parasitic Diseases*, **36**(1):49-52.
- Kulkarni, G.M., Narladkar, B.W. and Deshpande, P.D. (2001). Helminthic infections in desi fowl (*Gallus gallus domesticus*) in Marathwada region. *Journal of Veterinary Parasitology*, **15**:137-139.
- Morishita, T.Y. and Schaul, J.C. (2007). Parasites of Birds. In: Flynn's Parasites of Laboratory Animals. Ed: Baker D.G. Second Edition American College of Laboratory Animal Medicine. *Blackwell Publishing*, pp: 249.
- Percy, J., Pias, M., Enetia, B.D. and Lucia, T. (2012). Seasonality of parasitism in free range chickens from a selected ward of a rural district in Zimbabwe. *African Journal of Agricultural Research*, **7**(25):3626-3631.
- Permin, A., Esmann, J. and Hoj, C. (2002). Ecto-endo and haemoparasites in free-range chickens in the Goromonzi District in Zimbabwe. *Preventive Veterinary Medicine*, **54**(3): 213–224.
- Puttalakshamma, G.C., Ananda, K.J., Prathiush, P.R., Mamatha, G.S. and Suguna Rao. (2008). Prevalence of gastrointestinal parasites of poultry in and around Bangalore. *Veterinary World*, **1**(7):201-202.
- Soulsby, E.J.L. (1982). Helminths, Arthropods and Protozoa of Domesticated Animals. 7th edn., Baillière Tindall, London. pp: 809
- Sreedevi, C., Jyothisree, C.H., Rama Devi, V., Annapurna, P. and Jeyabal, L. (2016). Seasonal prevalence of gastrointestinal parasites in desi fowl (*Gallus gallus domesticus*) in and around Gannavaram, Andhra Pradesh, *Journal of Parasitic Diseases*, **40**(3):656–661.