

Persistent hymen with mucus accumulation in a crossbred heifer

S. Satheshkumar^{1*}, S. Raja², S. Senthil Kumar³, V. Prabakaran², R. Rajkumar²,
M. Saravanan³ and N. Premalatha⁴

*Department of Veterinary Gynaecology and Obstetrics
Veterinary College and Research Institute
Tamil Nadu Veterinary and Animal Sciences University
Orathanadu – 614 625, Thanjavur, Tamil Nadu, India*

Hymen normally appears as a circular constriction between vagina and vulva. However varying degrees of persistence, from thin band to complete imperforate structure, may occur in all species due to segmental defects of paramesonephric ducts (Roberts, 1971). Complete obliteration of vaginal canal due to imperforate hymen was reported earlier in crossbred (Kumar *et al.*, 2017), pure bred (Kumar *et al.*, 2020) and buffalo heifers (Singh *et al.*, 2010 and Kumar *et al.*, 2016) with varying degrees of mucus accumulation. The present report places on record a case of persistent hymen with voluminous mucus accumulation in a crossbred heifer.

Case history and Clinical Observations

A Jersey crossbred heifer (2.5 years) was referred to the Gynaecology section of Veterinary Clinical Complex, Veterinary College and Research Institute, Orathanadu, Tamil Nadu with the history of urinary incontinence, in appetite and straining for the past one week after being inseminated by a quack. Anamnesis revealed that animal was exhibiting oestrus signs without vaginal discharge and was inseminated thrice

previously.

Per rectal examination revealed a massive enlarged structure extending from the vaginal region to the level beyond the pelvic brim. The texture of the structure did not resemble that of pregnant uterus. Cervix was not palpable and hence suspected of abnormality in urinary bladder based on the history. There was no reduction in the mass even after emptying the urinary bladder by catheterization.

Exploration of vagina by speculum revealed a complete obliteration of vaginal canal beyond the urinary meatus, about 11 cm from the external genitalia (Fig.1). Based on the observations, the condition was diagnosed as 'Imperforate or Persistent Hymen' as per the classification of Roberts (1971). Two punctured points could be observed in the middle of the hymen which would have been caused by the faulty inseminations.

Ultrasonographic investigation with trans-rectal probe (Sonoscape S2V, China) was carried out which revealed a massive accumulation of fluid with echoic spots (resembling purulent debris) extending from vaginal region posteriorly to uterine horns anteriorly (Fig.2). Cervix was difficult to distinguish as it was extensively dilated with fluid.

^{1*} Professor and Head, Corresponding author Email: drsatheshkumar6@rediffmail.com

² Assistant Professor

³ Assistant Professor, Teaching Veterinary Clinical Complex

⁴ Professor and Head, Department of Veterinary Medicine

Treatment and Discussion

Vaginal speculum was passed and held in position against the septum. A sterile intrauterine catheter was passed through the septum and thick cloudy mucus started flowing out following the catheterization. To facilitate easy and complete evacuation,

suction pump was employed and about 15 litres of mucus was removed. After the fluid evacuation, per rectal examination revealed that the uterine contours palpable within the pelvic cavity. Ultrasonographic examination showed a clear band of tissue across the vaginal canal posterior to cervical region (Fig. 3a).

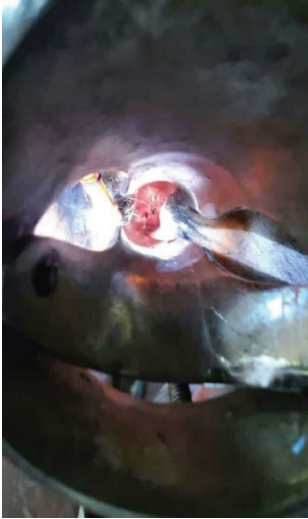

Fig.1: Visualization of hymen through vaginal speculum

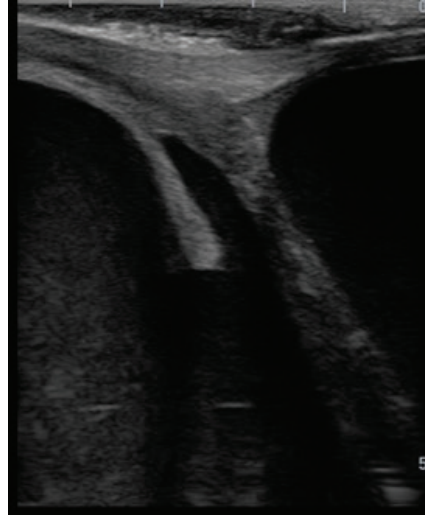


Fig.2: Ultrasonographic imaging of uterus and cervix with accumulated mucus

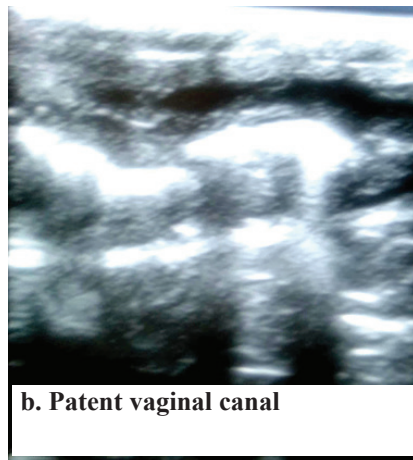
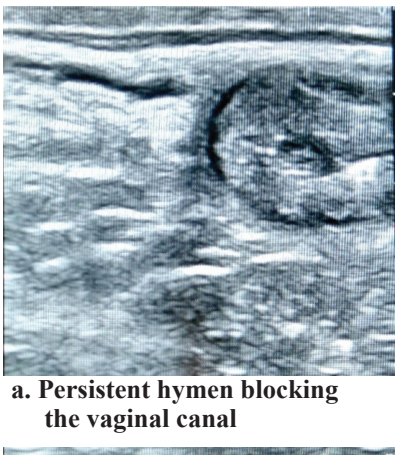


Fig.3: Ultrasonographic images of vaginal passage before and after surgery

The complete blockage of the vaginal canal due to the congenital anomaly resulted in accumulation of uterine and cervical secretions and formation of mucometra, mucocervix and mucovagina as described by Parkinson (2001). Previously Kumar *et al.* (2017) reported only mucocervix and mucovagina in association with persistent hymen in a crossbred heifer. However, Kumar *et al.* (2016) had documented a case of imperforate hymen along with development of pyometra, pyocervix and pyovagina in a Murrah buffalo heifer.

As a correction measure, a circular incision along the entire outer border of the persistent hymen was preferred as described by Roberts (1971). Under epidural anaesthesia, endotracheal tube meant for small animal anaesthesia was inserted through the opening created by the intrauterine catheter. The cuff was positioned anterior to the septum and inflated and thus the tube was fixed in position. The septum was retracted back near the vulval opening by pulling the tube. Holding the tube in position, circumferential resection of the septal tissue was performed using the BP blade. The incised wound was cleaned and vaginal canal was doused with potassium permanganate solution. Emollient of povidone iodine and cetrimide cream were applied around the entire vaginal canal. A surgical gauze tampon smeared with streptopenicillin powder was inserted and positioned at the site of incision to prevent adhesion. Antibiotics (Inj. Streptopenicillin 5gm; im), antihistaminics (Inj. Chlorpheniramine maleate 8 ml; im) and anti-inflammatory (Inj. Flunixin 7 ml; im) drugs were administered for five days. Seven days post-surgery, the tampon

was removed. Examination revealed a free passage of vaginal canal (Fig.3b) and satisfactory healing of the incised site. The uterine horns were empty and totally devoid of mucus accumulation. Sexual rest was recommended for two cycles.

Previous reports documented evacuation of 800ml to four litres of accumulated mucus in similar cases of imperforate hymen (Singh *et al.*, 2010, Kumar *et al.*, 2016, 2017 and 2020) but in the present case, around 15 litres of accumulated mucoid fluid was evacuated which indicated the chronic nature of the condition. The voluminous accumulation of the mucus was due to the cyclical secretions of previous estrus cycles.

Urinary incontinence might be due to obstruction of the urethra caused by the enlarged reproductive tract. After evacuation of the genital contents, urination was restored to normalcy.

The report documented the incidence of persistent hymen associated with massive accumulation of mucus and its successful correction in a crossbred heifer.

ACKNOWLEDGEMENT

The authors thank the Dean, Veterinary College and Research Institute, Orathanadu and the Director of Clinics, TANUVAS, Chennai -7 for their support in documenting the report.

REFERENCES

- Kumar, B., Krishnappa, B., Das, G.K., Sharma, G.C., Yadav, D. and Jan, M.H. (2016). Imperforate hymen

- and subsequent secondary pyometra, pyocervix and pyovagina in Murrah buffalo heifer: A case report. *Buffalo Bulletin*, **35**:19-21.
- Kumar, P., Sharma, A. and Singh, M. (2017). Clinical management of persistent hymen with mucocervix and mucovagina in a crossbred heifer. *Intas Polivet*, **18**:36-37.
- Kumar, P., Jamwal, K., Ghuman, S.S., Sharma, V., Sharma, A. and Singh, M. (2020). Persistent imperforated hymen in Holstein Friesian heifer—A case report. *International Journal of Science, Environment and Technology*, **9**:153-155.
- Parkinson, T.J. (2001). Infertility in the cow: Structural and functional abnormalities, management and non-specific infection. In: Noakes D.E, Parkinson T.J, England G.C.W., editors. *Arthur's Veterinary Reproduction and Obstetrics*. 8. Philadelphia: Saunders; pp. 383-472.
- Roberts, S.J. (1971). *Veterinary Obstetrics and Genital Diseases*, 2nd Edn., CBS Publishers and Distributors, Delhi.
- Singh, G., Singh, P., Pandey, A.K., Kumar, S., Sunder, S., Dutt, R. and Singh, K. (2010). A case report of persistent hymen in a Murrah buffalo. *The Haryana Veterinarian*, **49**:75.