

OCCURENCE OF *Cheilospirura hamulosa* AND *Subulura brumpti* IN A BACKYARD POULTRY (*Gallus domesticus*)

T.A.Vijayalingam^{1*}, N.V. Rajesh² and A. Latchumikanthan³

Veterinary University Training and Research Centre,
Tamil Nadu Veterinary and Animal Sciences University,
Ramanathapuram – 623 503, Tamil Nadu

ABSTRACT

Examination of gastro intestinal tract of 20 carcasses of backyard poultry revealed mucoid material in the lumen of the proventriculus and gizzard. The mucosa of proventriculus and gizzard were thickened. Peeling of the horny gizzard cuticle layer revealed the presence of Cheilospirura hamulosa on the sub-mucosal and muscular surface. The lumen of different parts of the gastrointestinal tract contained tenacious muco-sanguineous content. Caeca was completely filled with tarry red coloured content mixed with Subulura brumpti.

Key words: *Cheilospirura hamulosa*, *Subulura brumpti*, Backyard poultry

Received : 07.12.2022

Revised : 20.02.2023

Accepted : 28.02.2023

INTRODUCTION

Backyard poultry rearing under semi-scavenging system is found to be most suitable to the farmers of this region. It becomes the additional source of income and protein supplement (Latif, 2001). The poultry production under backyard is hindered due to infectious diseases. Parasitic diseases in backyard chickens are common due to scavenging habits in free range (Pandey *et*

al., 1992). Helminthosis considered being one of the most significant constraints on poultry production in humid tropical climatic conditions that are favourable for faster propagation and development of larval stages of parasites (Matta and Ahluwalia, 1981; Kulkarni *et al.*, 2001). The incidence of the occurrence of *Cheilospirura hamulosa* (*C. hamulosa*) and *Subulura brumpti* (*S. brumpti*) in 20 backyard birds (*Gallus domesticus*) of a poultry unit near Ramanathapuram town, Tamil Nadu, India is presented herewith.

MATERIALS AND METHODS

At Veterinary University Training Research Centre (VUTRC), Ramanathapuram detailed necropsy was conducted the

¹Professor and Head, Corresponding author Email id: tavijayalingam@gmail.com

²Assistant Professor

³Assistant Professor, Department of Veterinary Parasitology, Veterinary College and Research Institute, Orathanadu

20 carcasses from a backyard poultry unit. Lesions were recorded. The parasites were collected and preserved in 10 % formalin.

The preserved nematodes from caecum and ventriculus were washed thoroughly with normal saline and preserved in 70 % ethanol and later dehydrated in ascending grades of alcohol *i.e.* 70 %, 90 %, absolute alcohol, cleared in lactophenol (Murthy and Panda, 2015), mounted and identified (Soulsby, 1982).

RESULTS AND DISCUSSION

Gross examination of the carcasses showed mild to moderate muscular depletion and anaemic changes. Internal examination of gastrointestinal tract revealed mucoid material in the lumen of the proventriculus and gizzard. The mucosal surface of proventriculus and gizzard were thickened. Peeling of the horny gizzard cuticle layer revealed the presence of short, pink, coiled nematode parasites (8 Nos) on the sub-mucosal and muscular surface (Fig. 1 and 2). The affected sub-mucosal and muscular surface of the gizzard showed a mild erosion and haemorrhage. The lumen of different parts of the gastrointestinal tract contained tenacious muco-sanguineous content. The mucosa showed mild oedematic changes. Caeca was completely filled with tarry red coloured content mixed with thin, white coloured nematodes (23 worms). The worms collected from the ventriculus were identified as *Cheilospirura hamulosa* (Fig. 3 to 4) and those collected from caecum were identified as *Subulura brumpti* as per the key provided (Soulsby, 1982) Among the 20

birds succumbed, 10 birds had dual infection, 4 birds were affected with *Cheilospirura hamulosa* and remaining 6 birds were affected with *Subulura brumpti* infection.

Cheilospirura hamulosa, also known as the ‘gizzard worm’, is a spirurid nematode parasite of the ventriculus of many passerines, columbiform and free ranging gallinaceous birds (Urquhart *et al.*, 1994). The nematodes attach by their anterior end to the mucosal epithelial cells, mainly the muscular wall of gizzard, initially causing ulceration at the site of attachment (Menezes *et al.*, 2003). Worms in little number can cause only a mild nodular and inflammatory reaction in mucosa. However heavy worm burden leads to severe hyperplasia of proventricular glands. It was also opined by Menezes *et al.* (2003) that *C. hamulosa* can cause complications such as granulomas and nodules, severe anaemia, impotence, and mortality in chickens. In this present study the severity of worm burden causes thickened mucosa of gizzard wall, mild nodular and inflammatory reaction of muscular stomach (ventriculus) and caused about 10 % mortality. (Salam *et al.*, 2009).

Radfar *et al.* (2012) reported that *S. brumpti* was one among the highest parasites prevailed in the backyard poultry. Nagarajan *et al.* (2012) observed haemorrhagic typhilitis in *S. brumpti* infection in Japanese quails. In the present incidence also the content was tarry red in colour in the caeca.

ACKNOWLEDGEMENT

The authors would like to thank Tamil Nadu Veterinary and Animal Sciences

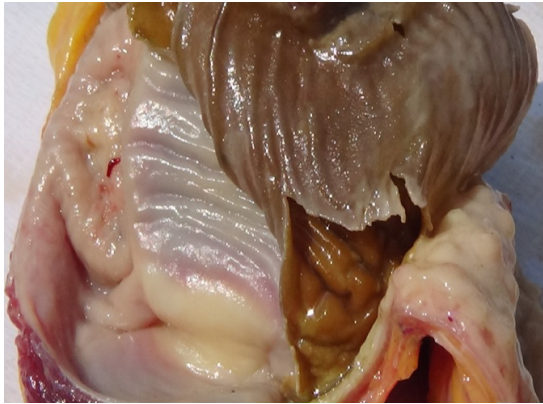


Fig 1. Thickened ventriculus and perforation due to the attachment of anterior head of *Cheilospirura hamulosa*

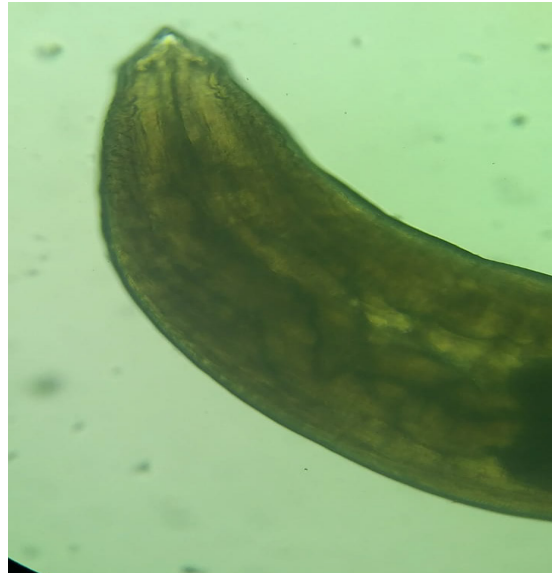

Fig 3. *Cheilospirura hamulosa* female worm with cordon at sides like decorations

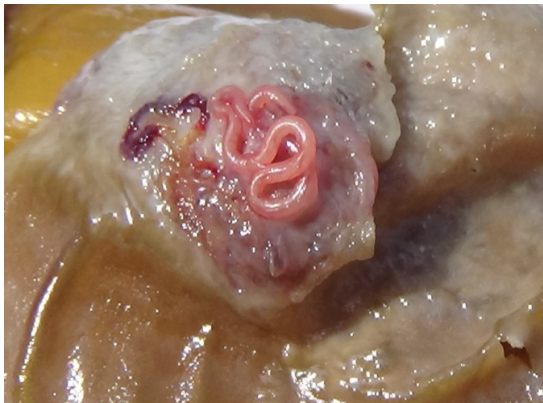

Fig 2. *Cheilospirura hamulosa* lodged in the ventriculus

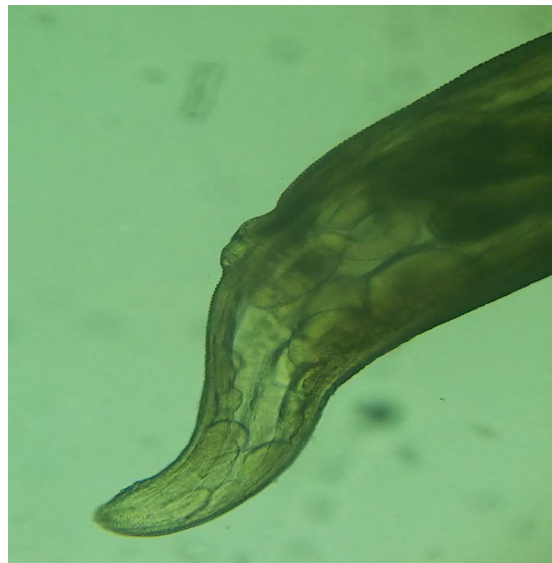


Fig 4. Posterior end of *Cheilospirura hamulosa* female worm

University for the encouragements extended during and after the investigation till it has come as a complete report.

REFERENCES

- Kulkarni, G.M., Narladkar, B.W. and Deshpande, P.D. (2001). Helminthic infections in desi fowl (*Gallus gallus domesticus*) in Marathwada region. *Journal of Veterinary Parasitology*, **15**: 137–139.
- Latif, M.A. (2001). Microcredits and savings of rural household of Bangladesh. *Bangladesh Development Studies*, **27**: 51–71.
- Matta, S.C. and Ahluwalia, S.S. (1981). Note on the survey of gastrointestinal helminths of domestic fowls in UP. *Indian Journal of Animal Science*, **51**: 1013-1015.
- Menezes, R.C., Tortelly, R., Gomes, D.C. and Pinto, R.M. (2003). Pathology and frequency of *Cheilospirura hamulosa* (Nematoda, Acuarioidea) in Galliformes hosts from backyard flocks. *Avian Pathology*, **32**(2): 151-156.
- Murthy, G.S.S. and Panda, R. (2015). A note on concurrent natural parasitism by *Dispharynx spiralis* and *Heterakis gallinarum* in backyard poultry (*Gallus domesticus*). *Journal of Parasitic Diseases*, **40**(4): 1369-1371.
- Nagarajan, K., Thyagarajan, D. and Raman, M. (2012). *Subulura brumpti* infection – An outbreak in Japanese quails (*Coturnix coturnix japonica*). *Veterinary Research Forum*, **3**(1): 67-69.
- Pandey, V.S., Demey, F. and Verhulst, A. (1992). Parasitic diseases: a neglected problem in village poultry in sub-Saharan Africa. In: Pandey, V.S., Demey, F. (Eds.), *Village Poultry Production in Africa*. Rabat, Morocco, 136-141.
- Radfar, M.H., Khedri, J., Adinehbeigi, K., Nabavi, R. and Rahmani, K. (2012). Prevalence of parasites and associated risk factors in domestic pigeons (*Columba livia domestica*) and free-range backyard chickens of Sistan region, east of Iran. *Journal of Parasitic Diseases*, **36**(2): 220-225.
- Salam, S.T., Mir, S.S., Shahnaz, S. and Khan, R.A. (2009). Prevalence and the associated lesions of *Cheilospirura (Acuaria) hamulosa* in the indigenous chicken of Kashmir valley, India. *Journal of Parasitology*, **95**(6): 1436-1439.
- Soulsby, E.J.L. (1982). *Helminths arthropods and protozoa of domesticated animals*. 7th edn. Bailliere Tindall, London, pp 809.
- Urquhart, G.M., Armour, J., Duncan, J.L., Dunn, A.M. and Jennings, F.W. (1994). *Veterinary Parasitology*. Churchill Livingstone Inc, London, pp 82–83.