

SURGICAL MANAGEMENT OF LIPOSARCOMA IN PIGEON

**R. Siva Shankar, T.S. Premavathy, Mohamed Shafiuzaama,
M.G. Mohamed Ali, Mala Shammi, S. Hemalatha**

Department of Veterinary Surgery and Radiology,
Madras Veterinary College, Chennai-600007
Tamil Nadu Veterinary and Animal Sciences University

Liposarcomas are malignant tumours of lipocytes and lipoblasts and are uncommon in pet birds. This is in contrast to lipomas, which are benign neoplasms that are frequently reported in avian species (Reavill, 2001). Anatomic locations of liposarcomas described in birds include the regions surrounding the carpus, pelvic limbs and digits, neck, sternal subcutaneous tissues, uropygeal gland, abdominal cavity, and metastatic foci in the liver (Reavill, 2001) and Doster *et al.*, 1987). Liposarcomas are usually pale yellow subcutaneous masses that are more firm, vascular, and infiltrative than lipomas (Reavill, 2001 and Petrak and Gilmore, 1982). Liposarcomas tend to act more aggressively than lipomas and surgical removal is recommended (Tully *et*

al., 1994, Ritzman *et al.*, 1996 and Berlin, 1988). This article reports the surgical excision of liposarcoma in a pigeon.

A three years old male pigeon weighing 400g (racing homer) was presented to Madras Veterinary College Teaching Hospital with the history of soft tissue growth on the keel region for the past six months and gradually increase in size was noticed. Physical examination revealed large tennis ball size soft tissue mass on the keel region (Fig. 1). Cytological examination revealed the presence of inflammatory cells with serosanguineous background. Radiological examination revealed presence of soft tissue mass on the keel bone with no bony involvement (Fig. 2).



Fig. 1. Large tennis ball size soft tissue on the keel region.

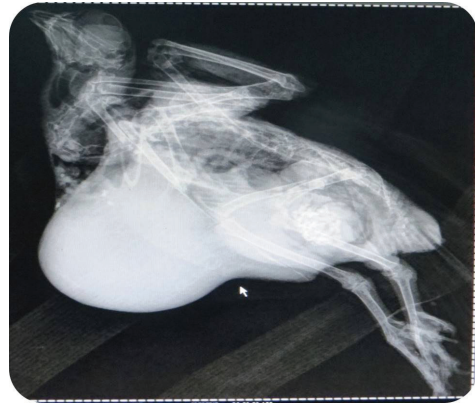

Fig. 2. Radiographic positioning of the bird and presence of soft tissue mass on the keel bone with no bony involvement

Surgical resection of tumour mass was performed under general anaesthesia. Food and water was restricted for 6h and 1-3h prior to surgery. The bird was pre-medicated with Atropine sulphate @ 0.04 to 0.1mg/kg b.wt IV (wing vein) and induced with ketamine @ 25mg/kg b.wt IM and diazepam @ 0.2 mg/kg b.wt IV. General anaesthesia was maintained with 2% Isoflurane in 100% oxygen through mask induction (Fig. 3). The surgical site was prepared aseptically (Fig. 4). The bird was positioned on dorsal recumbency. An elliptical incision was made over the tumour mass on the keel region (Fig. 5). The skin and fascia was removed. The tumour mass was resected from the keel bone (Fig. 6). No gross lesions of metastasis in other organs during the surgery. The subcutaneous tissues were closed in continuous suture pattern with PGA 2-0. The skin was sutured with 2-0 PGA by cross mattress pattern (Fig. 7). No intra-operative complications occurred during the surgery.

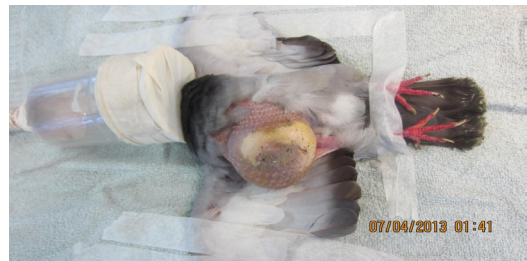

Fig. 3. The bird was prepared for surgery under general anaesthesia.

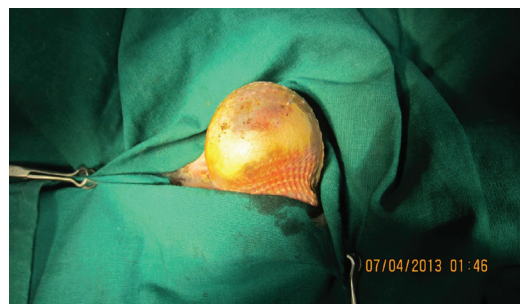

Fig. 4. Surgical site was prepared aseptically.

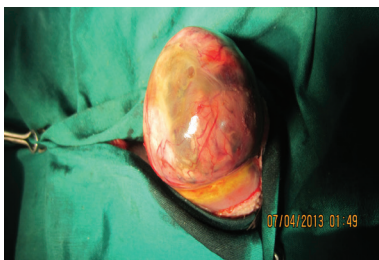

Fig. 5. Elliptical incision was made over the tumour mass on the keel region.

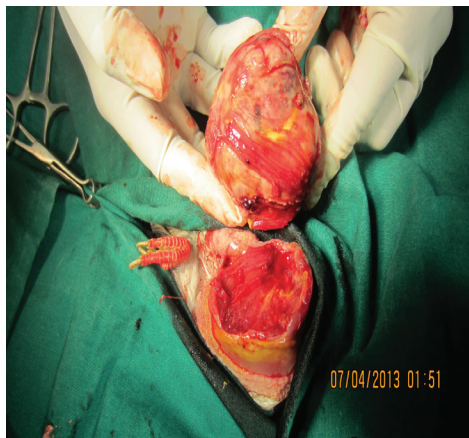

Fig. 6. Surgical resection of the tumour mass.

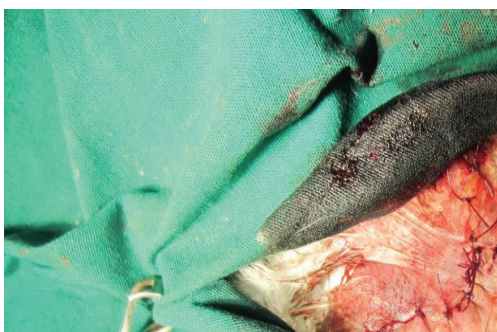

Fig. 7. The skin was closed by cross mattress pattern.

The excised tumour sample was collected in 10% formalin and sent for histopathological examination. Histopathological examination of the tumour mass revealed presence of polyhedral shape, vacuolated multiple fat cells and immature adipocytes. Histopathological examination confirmed liposarcoma (Fig. 8).

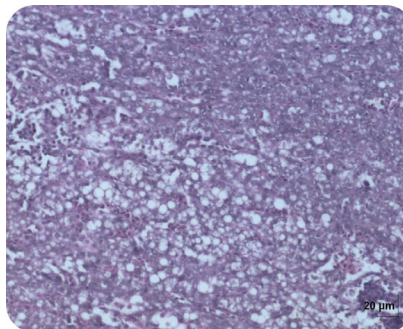


Fig. 8. Presence of polyhedral shape, vacuolated multiple fat cells and immature adipocytes. (Haematoxylin and Eosin stain, 100X).

Post-operatively, Tab Enrofloxacin @ 10mg/kg b.wt for five days and Tab Meloxicam @ 0.2mg/kg b.wt for three days were given orally. Owner was advised to give liquid food and water the day after surgery. The surgical wound was bandaged with mupirocin ointment every two days. No swelling and discharge was noticed. The bird recovered uneventfully within two weeks. There was no recurrence of the growth in a follow-up period of three months.

Lipomas are the most common tumour diagnosed in pet avian species (Campbell, 1986) and are identified most often in budgerigars, rose-breasted cockatoos, amazon parrots, and cockatiels (Reavill,

2004 and Latimer, 1994). Liposarcomas are a malignant variant of lipomas and are rarely diagnosed in psittacine species but have been described in budgerigars, cockatiels, macaws, monk parakeets, a pigeon and a green cheeked conure (Reavill, 2009, Tully *et al.*, 1994 and Ritzman *et al.*, 1996). Liposarcomas have a higher metastatic potential than lipomas and are locally invasive (Reavill, 2009). In many cases a definitive diagnosis of a lipomatous mass is easily made via the use of cytology. It is possible that one may not be able to cytologically differentiate between lipomas and liposarcomas, consequently a surgical biopsy may be necessary to achieve a definitive diagnosis (Reavill, 2004). In this case, cytological evaluation of the aspirated fluid from the tissue swelling was not helpful in finding a diagnosis of liposarcoma. Surgical excision has been reported to be the treatment of choice for treating lipomas in avian species (Harrison, 1986). In this case, the tumour mass was managed by surgical resection and confirmed by histopathological examination.

The signalment, physical examination and microscopic examinations are useful guidelines to aid in diagnosis. Results of fine-needle aspiration can be inconclusive, and complete surgical excision with histopathologic examination is recommended to establish a final diagnosis. In the above case, liposarcoma was successfully managed by surgical excision in a pigeon has been reported. No intra-operative complications occurred during the surgery. The recovery was good.

ACKNOWLEDGEMENT

The authors acknowledge their gratitude to the Dean and Director of Clinics, Madras Veterinary College, for providing necessary facilities.

REFERENCES

- Berlin, O., 1988. On leiomyosarcomas of bone and venous origin and the surgical treatment and prognosis for extremity soft tissue sarcomas. Gothenburg, Sweden: University of Gothenburg.
- Campbell, T., 1986. Neoplasia. In: Harrison GJ, Harrison LR, eds. *Clinical Avian Medicine and Surgery*. Philadelphia, PA, W.B. Saunders, pp: 500-508.
- Doster, A., J. Johnson, G. Duhamel, G. E. Duhamel, T. W. Bargar, P. Y. Chen, Z. Z. Cui, L. F. Lee and R. L. Witter, 1987. Liposarcoma in a Canada goose (*Branta canadensis*). *Avian Dis.* **31**: 918-920.
- Harrison, G. J., 1986. Selected surgical procedures. In: Harrison GJ, Harrison LR, eds. *Clinical Avian Medicine and Surgery*. Philadelphia, PA, W.B. Saunders, pp: 577-595.
- Latimer, K. S., 1994. Oncology. In: Ritchie BW, Harrison GJ, Harrison LR, eds. *Avian Medicine: Principles and Application*. Lake Worth, FL: Wingers Publishing, pp: 654-672.
- Petrak, M. and C. Gilmore, 1982. Neoplasms. In: Petrak M, ed. *Diseases of Cage and Aviary Birds*. Philadelphia, PA: Lea & Febiger; pp: 606-637.

- Reavill, D., 2001. Pet bird oncology. *Proc Anmt Conf Assoc Avian Vet.* Philadelphia, PA, W.B. Saunders, pp: 29-49.
- Reavill, D. R., 2004. Tumors of pet birds. *Vet Clin North Am Exotic Anim Pract.* 7: 537-560.
- Reavill, D., 2009. Tumors of pet birds. Proceedings of the Western Veterinary Conference, Las Vegas, NV.
- Ritzman, T. K., S. B. Hawley and F. Y. Schulman, 1996. Liposarcoma in a green-cheeked conure. *Proc Anmt Conf Assoc Avian Vet.* Tampa, FL, pp: 377-380.
- Tully, T. N., J. M. Morris, R. S. Veazey, J. L. Oliver and T. G. Snider, 1994. Liposarcomas in a monk parakeet (*Myopsitta monachus*). *J Assoc Avian Vet.* 8: 120-124.