

# MANAGEMENT OF SARCOPTIC AND PSOROPTIC MANGE INFESTATION IN RABBITS (*ORYCTOLAGUS CUNICULUS*) WITH INJECTABLE IVERMECTIN

E. Tamileniyan<sup>1</sup>, M. Jeevitha<sup>1</sup>, K. Karthika<sup>2</sup>, A. Latchumikanthan<sup>3</sup>,  
M. Veeraselvam<sup>2</sup>, V. R. Kundave<sup>3</sup>, M. Saravanan<sup>4</sup> and R. Velusamy<sup>5</sup>

Department of Veterinary Medicine  
Veterinary College and Research Institute  
Tamil Nadu Veterinary and Animal Sciences University  
Orathanadu – 614 625, Thanjavur

## ABSTRACT

*This study presents two clinical cases in Chinchilla and Himalayan rabbits, exhibiting symptoms such as alopecia, skin lesions, and ear lesions. Skin scrapings and fecal samples were collected and processed, revealing the presence of Sarcoptes scabiei mites, Psoroptes cuniculi mites, and Eimeria oocysts. Treatment involved subcutaneous administration of Ivermectin (0.2 mg/kg), accompanied by supportive and topical application of Benzyl benzoate. The rabbits displayed clinical improvement, with complete recovery observed within 30 days.*

**Keywords:** Rabbits, Sarcoptic mange, Psoroptic mange, Ivermectin, Oxidative stress

Received : 26.09.2023

Revised : 21.12.2023

Accepted : 18.01.2024

## INTRODUCTION

The rabbits belonging to the family Lagomorphs are raised in numerous countries for meat and fur. Rabbit meat is recommended for human consumption because its high nutritional protein content, calcium, phosphorous, and linoleic acid but low fat and cholesterol levels (Nistor *et al.*, 2013). One of the main challenges to commercial rabbit

rearing is the occurrence of sarcoptic mange caused by *Sarcoptes scabiei* (Prakash *et al.*, 2017). Sarcoptic mange affects a wide range of animal species and humans. *S. scabiei*, commonly referred to as scab mite, is an uncommon and highly contagious illness in lagomorphs such as rabbits (Percy and Barthold, 2001). *Psoroptes cuniculi*, frequently causes itching and crusting of the external ear canals in rabbits, also cause head shaking and drooping of ear pinnae (Sant and Rowland, 2009). This paper underscores the importance of routine clinical assessment of rabbit health. Accurate identification and precise treatment of mite species, especially *S. scabiei* is crucial due to its pathogenic potential to transmit to humans.

<sup>1</sup> UG Student, Veterinary College and Research Institute, Orathanadu

<sup>2</sup> Assistant Professor

<sup>3</sup> Assistant Professor, Department of Veterinary Parasitology

<sup>4</sup> Assistant Professor and Head

<sup>5</sup> Assistant Professor and Head, Department of Veterinary Parasitology

---

## MATERIALS AND METHODS

### Collection and processing of samples

The skin scrapings were collected from a five-month-old female Soviet Chinchilla rabbit (Case No. 1) with a history of weakness, lethargy, alopecia and scaly crusts (Fig.1) and a seven-month-old female Himalayan rabbit (Case No. 2) with a history of alopecia, redness, and swelling over the ear region (Fig. 2) which were brought to the Veterinary Clinical Complex, TANUVAS, Orathanadu, Thanjavur, Tamil Nadu. The skin scraping was treated with 10% Potassium Hydroxide which was heated to dissolve the debris. After centrifugation, sediment was examined for the presence of mites (Soulsby, 1982).

### Treatment of the rabbit

The two rabbits were treated with Ivermectin at a dose rate of 0.2 mg/kg subcutaneously every 7 days for three consecutive weeks, along with supportive treatments. These included Chlorpheniramine maleate @ 0.5 mg/kg, Meloxicam @ 0.5 mg/kg, Vitamin A, D<sub>3</sub>, E and Vitamins B1, B6 and B12 (Tribivet). Additionally, topical application of Benzyl benzoate was advised. Consecutive scraping was analysed during the 15th and 30<sup>th</sup> day of presentation. The owner of the rabbits was advised to present the rabbits every week for review and further investigation. Consequently, no treatment regimen was used to treat coccidiosis.

## RESULTS AND DISCUSSION

The skin scraping from Case No.1 showed the presence of mites and their developmental stages (Fig. 3- 7). These were identified as *Sarcoptes scabiei var cuniculi*. Soundararajan and Iyue (2005) and Arul Prakash *et al.* (2017) have also reported *Sarcoptes* sp. in Soviet Chinchilla rabbits. The eggs of *Sarcoptes scabiei* were transparent, oval, thick-shelled and measured 130 µm × 95 µm. The protonymphs are characterized by four pairs of legs, with the absence of genital apertures. *Sarcoptes scabiei* infestations, which frequently cause mange in rabbits, can be differentiated by the presence or absence of pruritis and a pattern of lesion distribution (Bhardwaj *et al.*, 2012; Arul Prakash *et al.*, 2017). The lesions in the present case were restricted to the hip region. Clinical indications such as the development of redness and alopecia, in addition to crust formation, were identified in the current study and were in agreement with the findings of Chandey *et al.* (2000). The skin scraping from the ear canal (Case No. 2) revealed the presence of *Psoroptes cuniculi* mites with their developmental stages (Fig. 8-11).

Examination of skin scraping on the 15th and 30th day of presentation revealed the absence of *Sarcoptes scabiei* in the rabbit under treatment. Clinically, significant improvement could be observed as early as the seventh day, and the rabbits completely recovered after 30 days. Processing of skin scraping on the 30<sup>th</sup> day of presentation revealed the absence of *Psoroptes cuniculi* in the rabbit under treatment.

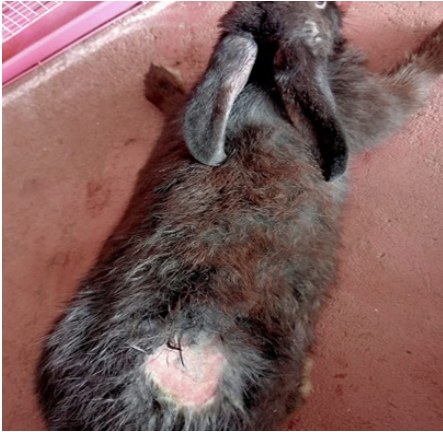The treatment of Sarcoptic mange infestation, *Notoedres*, and *Psoroptes* sp., in rabbits using injectable macrocyclic lactones like Ivermectin was quite effective when administered subcutaneously (Panigrahi *et al.*, 2016). Divisha *et al.* (2020) reported that treatment with ivermectin and topical application of Benzyle benzoate has controlled the mange in rabbits. Our study shows that Ivermectin treatment along with adequate care, cage hygiene, and segregation of the infested rabbit would control mange in rabbits. Vitamin A, D<sub>3</sub>, E were also given intra-muscularly. to minimize the oxidative stress caused by mites (Kanbur *et al.*, 2008).

### CONCLUSION

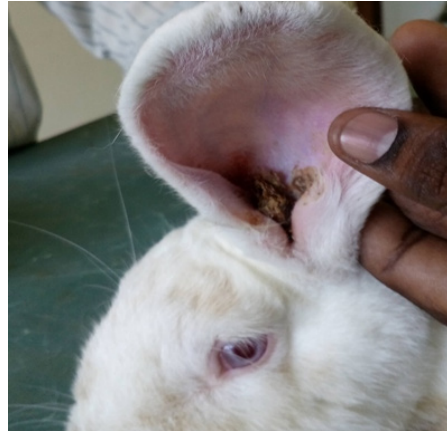Regular clinical assessments are vital for rabbit health. Accurate mite species identification and treatment are critical, especially due to the zoonotic potential of *S. scabiei*. This proactive approach protects both rabbit and human health, highlighting the interconnectedness of human and animal health. Periodic clinical examination, precise diagnosis, and treatment are essential for maintaining this balance.

### REFERENCES

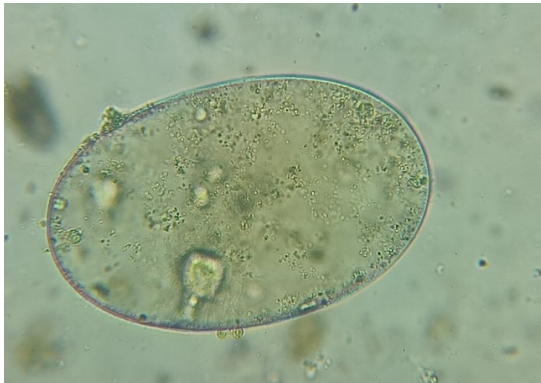- Arul Prakash, M., Soundararajan, C., Nagarajan, K., Tensingh Gnanaraj and Ramesh Saravana Kumar, V. (2017). Sarcoptic mange infestation in rabbits in an organized farm at Tamil Nadu. *Journal of Parasitic Diseases*, **41(2)**: 429 – 432.
- Bhardwaj, R.K., Ahmad Mir, I., Ahmad, O., Kumar, A., Wahid, A., Bhardwaj, D., (2012). An outbreak of mange in rabbits. *Indian Veterinary Journal*, **89(12)**:78.
- Divisha, R., Soundararajan, C. and Arul Prakash, M. (2020). Therapeutic management of concurrent sarcoptic and psoroptic mange infestation in rabbits. *Journal of Entomology and Zoology studies*, **8(1)**: 1041 - 1043.
- Kanbur, M., Atalay, O., Ica, A., Eraslan, G. and Cam, Y. (2008). The curative and antioxidative efficiency of doramectin and doramectin+ vitamin AD3E treatment on *Psoroptes cuniculi* infestation in rabbits. *Research in Veterinary Science*, **85**: 291 – 293.
- Panigrahi, P.N., Mohanty. B.N., Gupta, A.R., Patra, R.C. and Dey, S. (2016), Concurrent infestation of *Notoedres*, Sarcoptic and *Psoropti cacariosis* in rabbit and its management *Journal of Parasitic Diseases*, **40(3)**: 1091 – 1093.
- Sant, R. and Rowland, M. (2009). Skin disease in rabbits, *In Practice*, **31**: 233 – 239.
- Soulsby, E.J.L. (1982). Helminths, Arthropods and Protozoa of domesticated animals. Seventh edn. ELBS, London. Pp. 1 – 772.
- Soundararajan, C. and Iyue, M. (2005). Incidence of mange infestations in rabbits. *Journal of Veterinary Parasitology*, **19(2)**: 161 - 162.



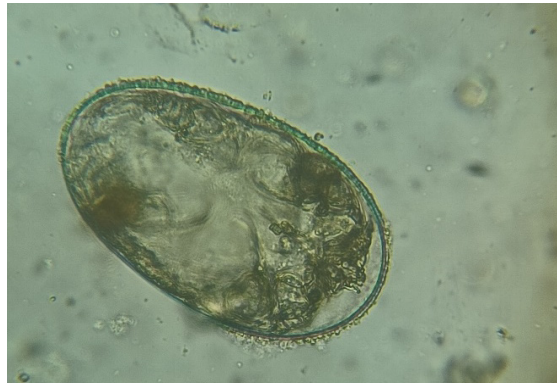**Fig. 1.** Rabbit with alopecia in the hip region



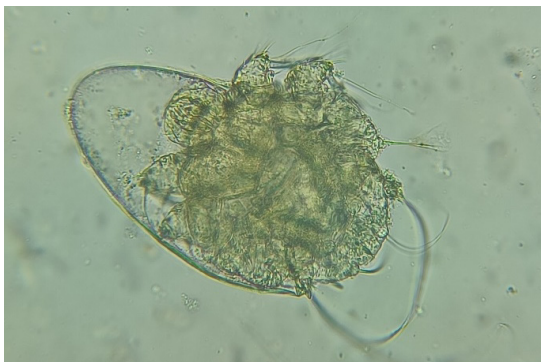**Fig. 2.** Rabbit with crusty ear lesion



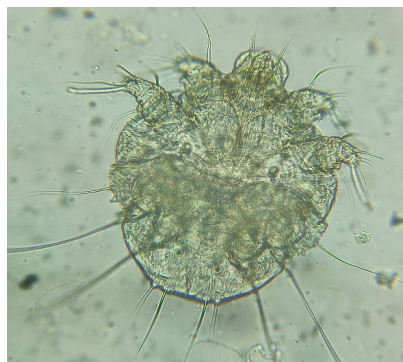**Fig. 3.** Egg of *Sarcoptes scabiei*(100 X)



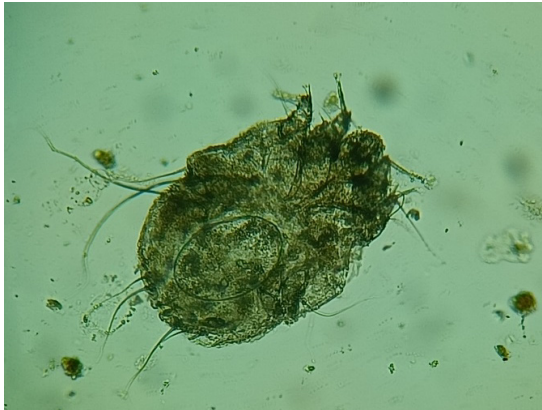**Fig.4.** Larva in *S. scabiei* egg (100 X)



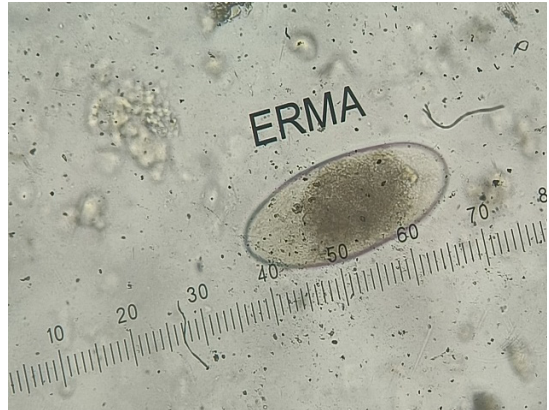**Fig. 5.** Release of *S. scabiei* larva (100X)



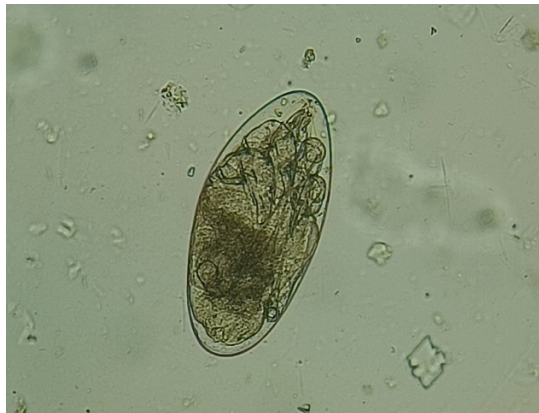**Fig. 6.** Adult *S. Scabiei* mite (100 X)



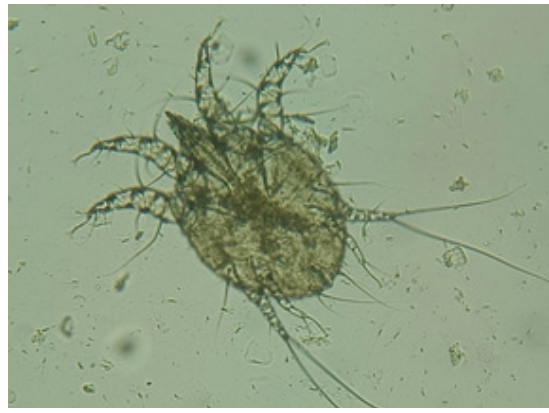
**Fig. 7. Adult female *S. Scabiei* with egg (100X)**



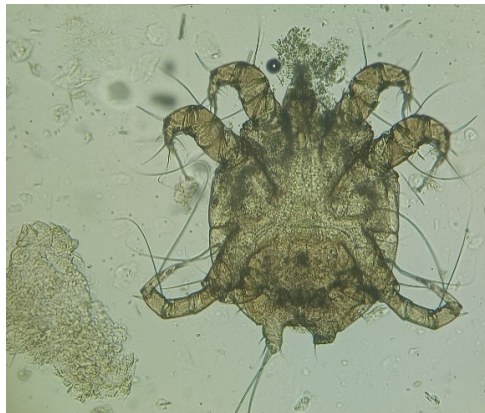**Fig. 8 Egg of *Psoroptes Cuniculi* (100X)**



**Fig.9 Larva in *P. Cuniculi* egg (100X)**



**Fig. 10 Adult Female *P. Cuniculi* mite (100X)**



**Fig. 11 Adult male *P. Cuniculi* mite (*Copulatory tubercle*) (100X)**