

**CONCURRENT INFECTION OF *TETRAMERES SP.*
AND *ECHINOSTOMA SP.* IN NOMADIC DUCKS FROM
THANJAVUR REGION OF TAMIL NADU**

**A. Latchumikanthan^{*1}, E. Tamileniyan², M.K. Vijayasarithi³,
K. Thilagavathi⁴, R. Velusamy⁵ and A. Meenakshisundaram⁶**

*Department of Veterinary Parasitology
Veterinary College and Research Institute
Tamil Nadu Veterinary and Animal Sciences University
Orathanadu – 614 625, Thanjavur District.*

ABSTRACT

*Free range grazing ducks play a major role in rural economy of Asian countries in the form of meat and egg production. The present study reports a mixed infection of *Tetrameres sp.* and *Echinostoma sp.* in nomadic ducks from Orathanadu, Thanjavur district of Tamil Nadu, India. On post-mortem examination of two ducks with a history of enteritis revealed bright red nematodes in the proventricular mucosa and minute flukes in small intestine. *Tetrameres sp.* and *Echinostoma sp.* worms were identified based on morphological characteristics. Intestinal contents also revealed eggs of *Tetrameres sp.* and *Echinostoma sp.* Further snails were collected from the duck rearing areas and confirmed the release of *Echinostome cercariae* and the snails were also identified as *Planorbis sp.* The study emphasizes the significance of mixed helminthic infections in nomadic ducks from Thanjavur, Tamil Nadu.*

Keywords: *Echinostoma sp.*, *Tetrameres sp.*, Ducks, *Planorbis sp.*, Tamil Nadu

Received : 03.03.2024

Revised : 16.05.2024

Accepted : 26.11.2024

INTRODUCTION

Ducks are native indigenous poultry species that has traditionally been raised by small and marginal farmers in India as an additional

income. Duck populations are primarily found in the Eastern, North-eastern and Southern states in which duck farming in India is mainly practiced by nomadic tribes, with a seasonal aspect. Tamil Nadu's duck population resides mainly in the districts of Kancheepuram, Madurai, Thanjavur, Thiruvallur, Tiruchirapalli, Tirunelveli, Vellore and Villupuram, which are noted for paddy cultivation. Ducks are able to feast on snails and fish in the abundant water resources (Gajendran and Karthickeyan, 2011). Geographical location, subtropical climate, waterlogged and low areas across

¹ Assistant Professor,

*Corresponding author : latchupara2010@gmail.com

² B.V.Sc. Student

³ Assistant Professor, Farmers Training Centre, Kancheepuram

⁴ Assistant Professor, Department of Veterinary Pathology, VC&RI, Orathanadu

⁵ Assistant Professor,

⁶ Professor, Department of Veterinary Parasitology, VCRI, Tirunelveli

the country are good locations for raising ducks, but all of these factors additionally promote parasite growth, multiplication, development, and distribution (Farjana *et al.*, 2008). The genus *Echinostoma sp.* (Trematoda: Echinostomatidae) has around 120 species with a global range. *Echinostoma sp.* affects the domestic poultry and water birds with enteritis, diarrhoea whereas nematode *Tetrameres sp.* in proventricular region causes haemorrhages and anaemic disease which decreases growth, egg productivity and sometimes mortality in birds with heavy infection (Soulsby, 1982). This paper deals with the mixed infection of *Tetrameres sp.* and *Echinostoma sp.* in nomadic ducks from Thanjavur Cauvery delta region of Tamil Nadu.

MATERIALS AND METHODS

Two dead ducks of 1 year of age from a duck flock from Thennamanadu, Orathanadu block of Thanjavur district with history of diarrhoea were presented to Department of Veterinary Pathology, VCRI, Orathanadu, TANUVAS for diagnosis of cause of death during July, 2021. The post mortem examination of the ducks revealed that emaciated appearance of carcasses, enteritis, soiled vent, presence of reddish nematode worms embedded in proventricular mucosa and minute flukes also in intestinal mucosa and in caecum. The worms were collected in normal saline solution for morphological identification (Soulsby, 1982). Intestinal contents were also collected for screening of parasites ova/oocysts. Faecal droppings were also collected randomly from other live ducks

and subjected to faecal sedimentation (Soulsby, 1982). The snail vectors were also collected for morphological identification and further confirmation of trematode larval stages. In order to confirm the cercariae from the collected snails by microscopy, the snails were exposed to sunlight in individual glass tubes for 30 min as described by Frahm *et al.* (2019).

RESULTS AND DISCUSSION

Bright red nematodes were identified as *Tetrameres sp.* based on characters like reddish colour, globular shape with pointed anterior and posterior extremities of female worms and uterus filled with embryonated eggs (Fig.1). Similarly, flukes were identified as *Echinostoma sp.* based on characters of size 1cm in length, head collar with 37 spines including either side of 5 corner spines and tandem testes and vitelline glands at the lateral sides (Fig. 2 & 3). Microscopical examination of the intestinal contents revealed slight yellowish oval shaped eggs with compact yolk mass, measuring 110 μm x 65 μm size identified as *Echinostoma sp.* (Fig.4) and colourless oval shaped eggs with thick shell and developed larvinside, eggs measuring 50 μm x 30 μm size identified as *Tetrameres sp.* (Fig. 5) using micrometry. Based on the circular whorls in shells and no operculum, the snails were identified as *Planorbis sp.*, which acts as intermediate host for *Echinostoma sp.* In this study cercaria from snails were identified as *Echinostome cercariae* (Fig. 6 & 7) based on the presence of collar spines in the anterior region.

Ducks raised in the region was typically free-range scavenging with limited housing, rendering them susceptible to parasite infections such as helminthiasis (Gajendran and Karthickeyan, 2011). The present study identified *Echinostoma* sp. in the intestine and caecum of ducks which was similar to the study by Yousuf *et al.* (2009) who reported heavy infection of echinostomes, especially *Echinostoma revolutum* causing emaciation and catarrhal enteritis and death in young ducks. The genus *Echinostoma* possesses a complex life cycle, with intermediate hosts, where we identified the presence of *Echinostome* cercariae in *Planorbis* sp. snails, and definitive hosts being vertebrates such as birds especially ducks. Cercariae released from *Planorbis* sp. snails identified as *Echinostome* cercariae and they possessed head collar with spines which was similar to the findings by Labony *et al.* (2022) in chickens from Bangladesh, but the snail species were *Lymnaea luteola*.

Round worm *Tetrameres* sp. infects about 300 bird species throughout 20 orders, including domesticated and wild fowls. Five species are typically observed in poultry: *T. americana*, *T. crami*, *T. fisispina*, *T. pattersoni* and *T. mohtedai* (Soulsby, 1982). *T. fisispina* is primarily found in wild ducks, geese and water fowl, but also in domestic ducks, pigeons, fowl, turkey, guinea fowl and quails throughout Europe, Asia and Far East (Saif *et al.*, 2003). In this study, *Tetrameres* sp. worms were identified from the proventricular region of nomadic ducks during the post-mortem examination whereas Vimalraj and Latchumikanthan, (2019) reported *Tetrameres* sp. in backyard

chicken from Puducherry and Vijayasarithi *et al.* (2021) reported *Tetrameres mohtedai* in desi-chickens from Cauvery delta region of Tamil Nadu. Oyeka (1989) previously documented up to 54.5% prevalence of *Tetrameres* sp. in poultry farms from Nigeria.

Histopathology of proventricular region showed glandular atrophy and inflammation (Fig. 8) which was similar to the previous findings by Vijayasarithi *et al.* (2021) in domestic chickens affected with *Tetrameres mohtedai*. Generally, *Tetrameres* sp. parasites are considered less pathogenic to birds, but can cause mortality in poultry under stressed conditions and during heavy infections. *Tetrameres* sp. must have been acquired through feeding on intermediate hosts on the ground mainly grasshoppers and cockroaches, where adult worms will develop in the proventriculus. The adult worm feeds on the host's blood, becoming engorged and gravid. This feeding habit may cause serious haemorrhage, congestion, anaemia and death in the infected birds (Vimalraj and Latchumikanthan, 2019). Live birds of the duck flock were randomly examined for parasitic ova in faecal samples which revealed eggs of *Echinostoma* sp. and *Tetrameres* sp. Hence the duck flock was dewormed with fenbendazole @ 5mg/kg body wt. and levamisole @ 7.5 mg/kg body wt. orally. Duck farmers were also advised to deworm their birds regularly to avoid economic loss. This study highlighted the mixed infection of *Tetrameres* sp. and *Echinostoma* sp. in native ducks. Further molecular studies at the species level identification of parasites and also for snail species are warranted.

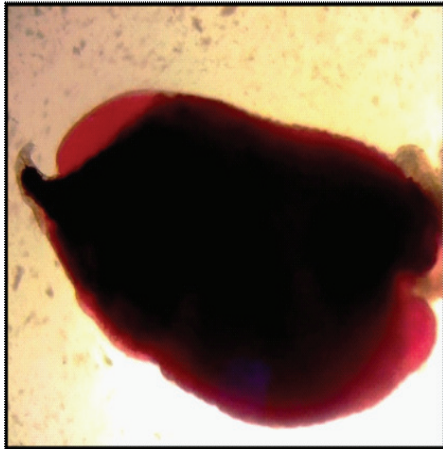


Fig. 1. Adult female Tetrameres sp. (x100)

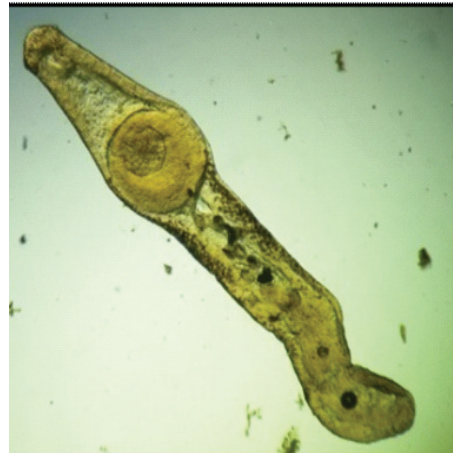

Fig. 2. Echinostoma sp. collected from the intestine of ducks (x100)

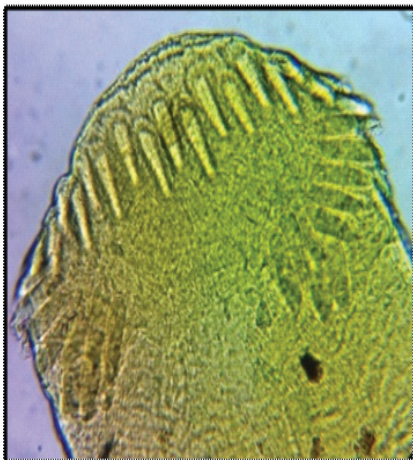

Fig. 3. Echinostoma sp. showing the head collar spines (x400)

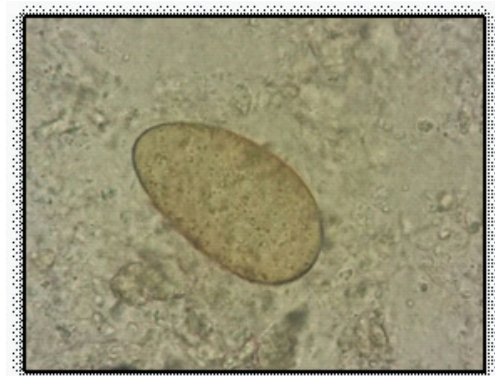

Fig. 4. Egg of Echinostoma sp. (x400)

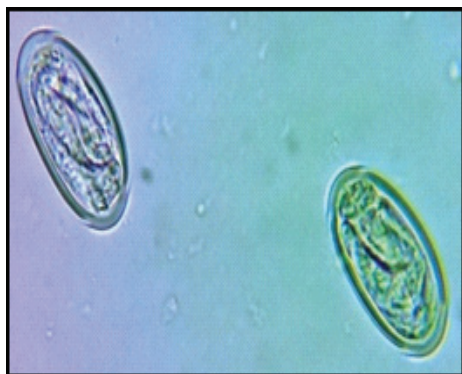

Fig. 5. Eggs of Tetrameres sp. with larva inside (x400)

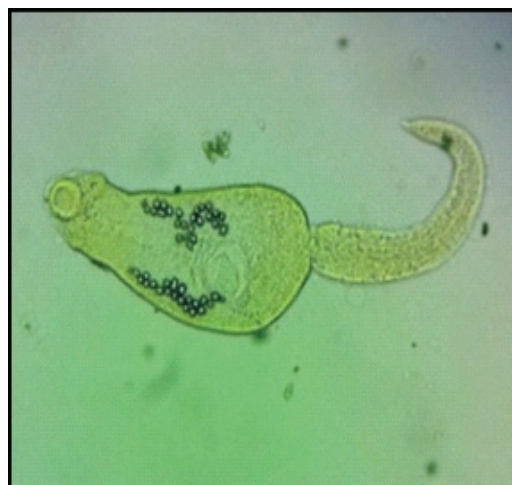


Fig. 6. Echinostome cercariae released from Planorbis sp. snails (x100)

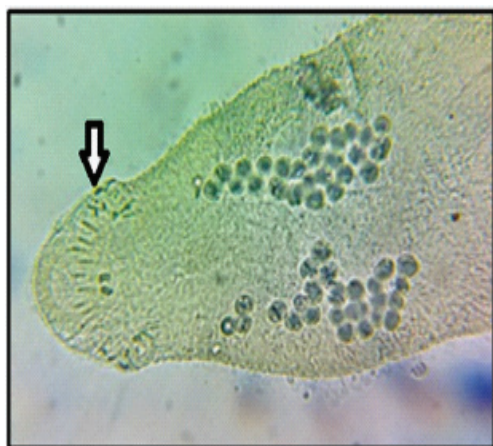

Fig. 7. Echinostome cercariae showing head collar spines (arrow) (x400)

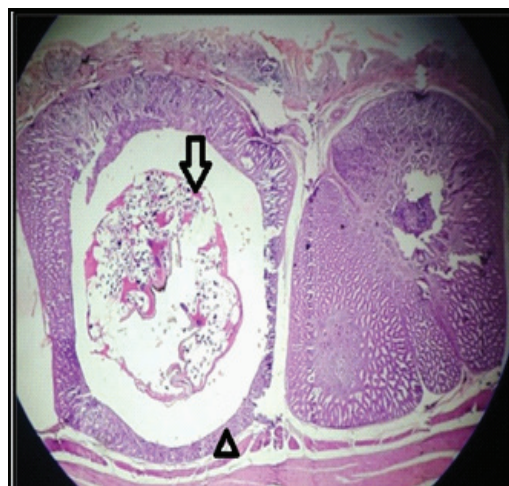


Fig. 8. Histopathology of duck proventriculus with cross section of Tetrameres (arrow) and atrophy of glandular epithelium (arrow head) H&E (x100)

CONCLUSION

Based on the necropsy findings and parasitological examination, it was diagnosed as concurrent infection of Tetrameres sp. and Echinostoma sp. in native ducks. This highlights the importance of mixed helminthic infection and regular deworming for helminths in ducks.

CONFLICT OF INTEREST

The authors do not have any conflict of interest for this article.

ACKNOWLEDGEMENT

The authors are thankful to the Dean, Veterinary College and Research Institute, Orathanadu, Thanjavur for the facilities provided to carry out this study. We also thankfully acknowledge the Dept. of Veterinary Pathology, VCRI, Orathanadu for providing the parasitic specimens for the study.

REFERENCES

- Farjana, T., Islam, K.R. and Mondal, M.M.H. (2008). Population density of helminths in ducks: effects of host's age, sex, breed and season. Bangladesh. *Journal of Veterinary Medicine*, **6** (1): 45-51.
- Frahm, S., Anisuzzaman, A., Prodjinotho, U.F., Vejzagic, N., Verschoor, A. and Prazeres da Costa, C. (2019). A novel cell-free method to culture *Schistosoma mansoni* from cercariae to juvenile worm stages for in vitro drug testing. *PLoS Neglected Tropical Diseases*, **13** (1): e0006590.
- Gajendran, K. and Karthickeyan, S.M.K. (2011). Indigenous technical knowledge in duck production in Tamil Nadu. *Indian Journal of Traditional Knowledge*, **10**: 307-310.
- Labony, S.S., Paul, S., Alim, M.A., Hossain, M.S., Inoue, T., Ritu, S.Z., Alam, M.Z., Alam, M., Kawada, H., Hasan, M.M., Hatta, T., Tsuji, N. and Anisuzzaman, A. (2022). Genetic analysis, pathology and vectors of echinostomiasis, a zoonotic helminth infection in chickens in Bangladesh. *Poultry Science*, **101** (3): 101682.
- Oyeka, C.A. (1989). Prevalence of intestinal helminths in poultry farms in Anambra state Nigeria. *Bulletin of Animal Health and Production Africa*, **37**: 217-220.
- Saif, Y.M., Faldy, A.M., Calnek, B.W., Beard, C.W., Swayne, D.E., Barnes, H.J., McDougald L.R. and Glissin, J.R. (2003). *Diseases of Poultry*, 11th edn., Iowa State Press, 937-939.
- Soulsby, E.J.L. (1982). *Helminths, Arthropods and Protozoa of Domesticated Animals*, 7th edn., Bailliere and Tindall, The English Book Society, London. pp. 300-302.

- Vijayasarithi, M.K., Latchumikanthan, A., Velusamy, R., Thilagavathi, K. and Meenakshi Sundaram, A. (2021). Occurrence and pathogenicity of *Tetrameres mohtedai* infection in desichickens from Cauvery delta region of Tamil Nadu. *Indian Journal of Veterinary and Animal Sciences Research*, **50** (6): 83-86.
- Vimalraj, P.G. and Latchumikanthan, A. (2019). *Tetrameres* sp. (Spiruridae) from backyard chicken (Galliformes: Phasianidae) in Puducherry - A First Report. *Environmental Contaminants Reviews*, **2** (2): 15-16.
- Yousuf, M.A., Das, P.M., Anisuzzaman and Banowary, B. (2009). Gastrointestinal helminths of ducks: Some epidemiologic and pathologic aspects. *Journal of Bangladesh Agricultural University*, **7**: 91-97.