

BILATERAL EPISIOTOMY FOR SUCCESSFUL PER VAGINAL DELIVERY OF TERATOLOGICAL TWIN FETUSES IN A DOE WITH VULVAL STENOSIS

Radhika S^{*1}, Srinivas M², Chandra Prasad B³ and Nagarjuna N⁴

*Department of Veterinary Gynaecology and Obstetrics
NTR College of Veterinary Science
Sir Venkateswara Veterinary University
Gannavaram – 521102, Andhra Pradesh, India*

ABSTRACT

A full-term pregnant doe was presented with a history of dystocia. Ultrasonographic examination revealed the presence of two dead fetuses. On obstetrical examination, vulval stenosis was confirmed. Bilateral episiotomy was performed and twin dead fetuses were delivered per-vaginum by traction. Among the dead male twins, the first fetus had only prognathism second one had prognathism and a severe degree of congenital lordosis. Post-operative treatment was followed resulting in an uneventful recovery of the doe.

Keywords: Dystocia, Episiotomy, Prognathism, Vulval stenosis.

Received : 27.06.2024

Revised : 28.11.2024

Accepted : 04.12.2024

INTRODUCTION

Vulval stenosis is a defect of the caudal reproductive tract and these animals conceive normally and progress through normal pregnancy but result in dystocia that can be resolved by episiotomy or caesarean section (Roberts, 1986). Perusal of literature regarding dystocia due to infantile vulva or

vulval stenosis was frequently reported in heifers (Jackson, 1995) but rarely in does (Hemalatha *et al.*, 2018). The present report places on record a rare case of dystocia due to combination of vulval stenosis in a doe along with teratological twin fetuses.

CASE HISTORY AND OBSERVATIONS

A 14-month old, full-term pregnant nulliparous doe was presented to the large animal obstetrical ward with a history of ruptured fetal membranes and unproductive straining since 48 hrs. On physical examination, the doe was dull, anorectic, dehydrated with elevated temperature and presence of putrefied vaginal discharge. On clinical observation, the fetal ear was

¹Assistant Professor, Department of Veterinary Gynaecology and Obstetrics, NTR College, Gannavaram

*Corresponding author Email id: radhikanaidu8121@gmail.com

²Professor and Head, Department of Veterinary Gynaecology and Obstetrics, NTR College, Gannavaram

³Assistant Professor, Department of Veterinary Clinical Complex, NTR College, Gannavaram

⁴Veterinary Assistant Surgeon, Atkuru, Krishna Dist.

protruded from the narrow vulval orifice (Fig.1). Obstetrical examination revealed that only three fingers could be passed into the vulval opening indicating vulval stenosis. Trans-abdominal ultrasonographic examination of the doe revealed the presence of two fetuses with absence of movement and heart beat. In the present case, vulval stenosis was the definite cause of dystocia. As the fetal parts were presented at the vulval orifice, it was presumed that cervix was completely dilated and hence episiotomy technique was opted instead of C-section to deliver the dead fetuses.

TREATMENT

The doe was administered with 250 ml of 5% dextrose fluid intravenously. Epidural anaesthesia was induced with administration of 2 ml of 2 % lignocaine HCl (4 mg/kg body weight) in the lumbosacral site. The surgical site was aseptically prepared by clipping the hair and liberal application of Povidone iodine solution. Further, ring block was advocated by administering 5 ml of 2% lignocaine HCl around the vulval region. As per the standard procedure, the upper third of the vulvar labium was incised at the junction between the mucosa and skin in the shape of a slight arc in a dorsolateral direction (Noakes *et al.*, 2018). Thus, a incision was made at 2 o'clock position on the dorso lateral aspect of the right vulval lip using scalpel blade (size no.22), and the same was performed on the opposite vulval lip at 10 o'clock position to widen the vulval passage (Fig.2). The birth canal was thoroughly lubricated with lukewarm 2% sodium carboxy methyl cellulose solution.

After lubrication, detailed obstetrical examination revealed the presence of a dead fetus in anterior longitudinal presentation, dorso-sacral position with right carpal flexion. The postural abnormality was corrected by using repulsion and manual manipulations of the right knee joint and the fetus was delivered by mild traction. On visual observation of the dead male kid revealed the presence of prognathism (Fig.3). Subsequent examination of the birth canal revealed the presence of second fetus in anterior longitudinal presentation, dorso-sacral position with bilateral carpal flexion. In similar manner, the second dead fetus was also repelled into the birth canal and its malposture was corrected by mutational operation. Further, examination revealed space constraint between the normal maternal pelvis and the deformed fetal pelvis. For its clearance, the doe was placed in dorsal recumbency and rotation with traction of the fetus was adopted for the delivery of the teratological fetus (Fig.3). Clinical examination revealed that the second male kid had prognathism defect, and had a marked inward curvature of the lumbar spine (Congenital lordosis) with exposed intestines and deformed pelvis (Fig.3).

After successful per-vaginal delivery of teratological twin fetuses, simple continuous sutures were applied to the episiotomy incisions (Fig.4). Post-operative treatment was given with Inj. Ceftriaxone (10 mg/kg b.wt; i m) once in a day for 5 days and Inj. Flunixin meglumine (2.2 mg/kg b.wt; i m) for 3 days. The suture line was applied with antiseptic (Oint Povidone

iodine). Post-operatively, the doe had an uneventful recovery when reported for suture removal after 10 days (Fig.5).

DISCUSSION AND CONCLUSION

Vulval stenosis is one of the maternal cause of dystocia in farm animals. Earlier reports opined that episiotomy was the technique of choice to relieve dystocia due to the vulval stenosis. Episiotomy technique was to incise the vulval lips to increase its diameter for safe per-vaginal delivery (Noakes *et al.*, 2018). Congenital

stenosis of vulva resulting in dystocia and its successful management through episiotomy was recorded in does previously (Hemalatha *et al.*, 2018). However, the present case is rare due to combination of vulval stenosis and teratological twin fetuses in a doe which was successfully relieved by using bilateral episiotomy technique.

It was concluded that episiotomy is the best technique of choice to relieve dystocia due to vulval stenosis with dilated cervix in order to facilitate safe per-vaginal delivery.

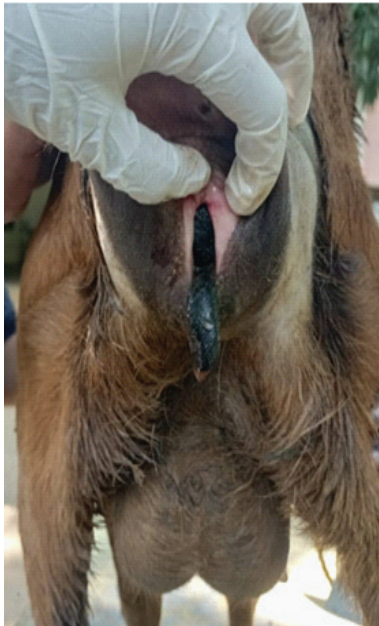


Fig.1:Vulval stenosis

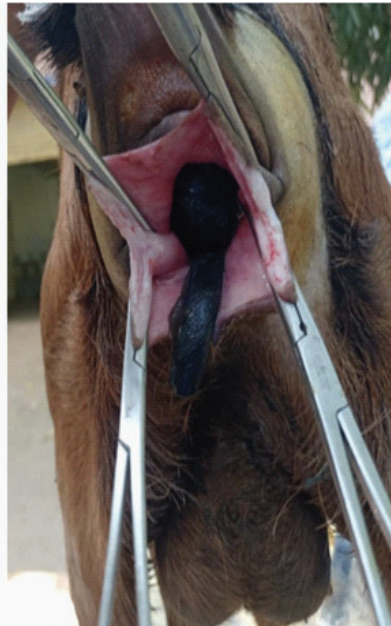


Fig.2: Episiotomy Incisions on vulval lips



Fig.3:Teratological twin fetuses
1.Fetus with prognathism
2.Fetus with Prognathism and congenital lordosis

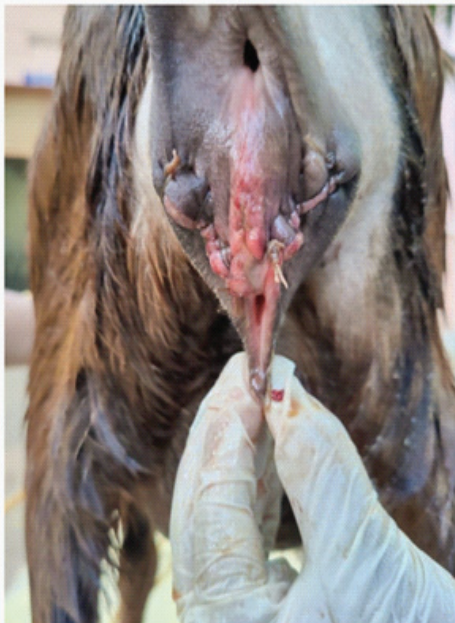


Fig.4: Episiotomy site after suturing

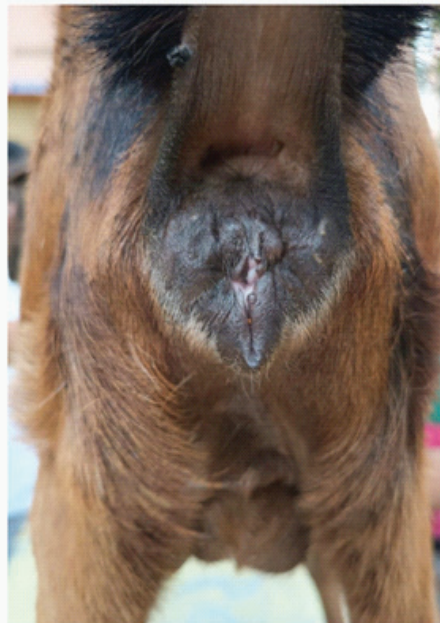


Fig.5: Episiotomy site after suture removal

REFERENCES

- Hemalatha, H., Murugavel, K., Antoine, D., Kantharaj, S. and Raju, M.S. (2018). Episiotomy to relieve dystocia due to infantile vulva in a goat. *The Indian Journal of Animal Reproduction*, **39**(2):74-75.
- Jackson, P.G.G. (1995). Dystocia in the cow: In: *Handbook of Veterinary Obstetrics*. 1st ed. W.B.Saunders Co.Ltd., Philadelphia,,p 30-69.
- Noakes, D.E., Parkinson, T.J. and England, G.C. (2018). *Arthur's Veterinary Reproduction and Obstetrics-E-Book*:Elsevier Health Sciences.p.273.
- Roberts, S.J. (1986). Chapter X, Diagnosis and treatment of the various types of dystocia In: *Veterinary Obstetrics and Genital Diseases (Theriogenology)*, 3rded Ithaca, New York. p346-347.