

## SURGICAL CORRECTION OF PNEUMOVAGINA BY MODIFIED CASLICK'S OPERATION IN A THOROUGHBRED MARE

T. Sarath<sup>1</sup>, R. Pranavgeethan<sup>2</sup>, S. SenthilKumar<sup>3</sup>, A. Thangamani<sup>4</sup>,  
A. Reshma<sup>5</sup>, R. Rajkumar<sup>6</sup> and S. Manokaran<sup>7,\*</sup>

*Veterinary Clinical Complex  
Veterinary College and Research Institute  
Tamil Nadu Veterinary and Animal Sciences University  
Salem-636112.*

### ABSTRACT

*Pneumovagina is a prevalent condition in older Thoroughbred mares, characterized by the abnormal entry of air into the vagina which leads to chronic endometritis. Poor vulvar conformation in such mares predisposes them to infections, leading to chronic reproductive issues like subfertility. The mare was presented with history of purulent vaginal discharge and inappetence for past one week. Based on the physical, clinical and ultrasonographic examinations, the condition was confirmed as pneumovagina with uterine distension and endometritis. The treatment included antibiotics based on microbial sensitivity, uterine lavage, and performed Caslick's operation, where the vulvar lips were surgically sutured and reduced the length and diameter of vulva. After postoperative therapy, the mare recovered uneventfully. A follow-up wind-sucker test was negative, and there were no signs of pneumovagina. Caslick's operation proved to be a successful intervention for managing recurrent endometritis due to pneumovagina in Thoroughbred mares. This case emphasizes the importance of timely surgical correction in preventing further reproductive complications.*

**Keywords:** Thoroughbred mare, pneumovagina, endometritis, Caslick's operation

Received : 18.11.2024

Revised : 05.02.2025

Accepted : 12.02.2025

---

<sup>1</sup>Associate Professor and Head,

<sup>2</sup>UG Scholar

<sup>3</sup>Professor, Dept. of Animal Nutrition

<sup>4</sup>Assistant Professor,

<sup>5</sup>Assistant Professor,

<sup>6</sup>Assistant Professor, Veterinary Clinical Complex

<sup>7</sup>Professor and Head, Department of Veterinary  
Gynaecology and Obstetrics

\*Corresponding author Email: smanokaran1976@  
gmail.com

### INTRODUCTION

Pneumovagina is the accumulation of air in the vagina, which can be either intermittent or continuous (Newcombe, 2011). The pneumovagina may be normal for mares immediately after foaling and it is not typical in other situations. The recessed and forward-sloping vulva is a common confirmative change which occurs in aged

Thoroughbred mares and makes the animal more prone for pneumovagina (Baharudin and Sabri, 2019). The changes in anatomical configuration of vulva affects the one-way valve mechanism of the vagino-vestibular sphincter, making it easier for air and faecal material to enter the vagina. The presence of air can lead to further complications such as pneumo and pneumouterus, increasing the risk of genital tract and endometrial infections which manifest as vaginitis, cervicitis, endometritis and ultimately leading to subfertility (Baharudin and Sabri, 2019; Filho *et al.*, 2015). The pneumovagina can be treated with a surgical procedure known as Caslick's operation, which involves suturing the dorsal two-thirds of the vulvar lips reducing the length and diameter of vulva opening (Dascanio, 2021; Arnold and Stout, 2022). The surgical intervention helps to prevent the intake of air and faecal particles in to vagina which effectively prevent the recurrent endometritis associated with pneumovagina in mares.

### **CASE HISTORY AND CLINICAL OBSERVATION**

A 13-year-old female Thoroughbred mare was presented to the Veterinary Clinical Complex, Veterinary College and Research Institute, Salem with a history of copious purulent vulvar discharge and inappetence. The general clinical examination revealed that all the vital parameters were within the normal range. The external examination of the genitalia indicated a recessed anus and a forward- sloping vulva (Fig. 1). Vaginal examination showed a fully dilated cervix

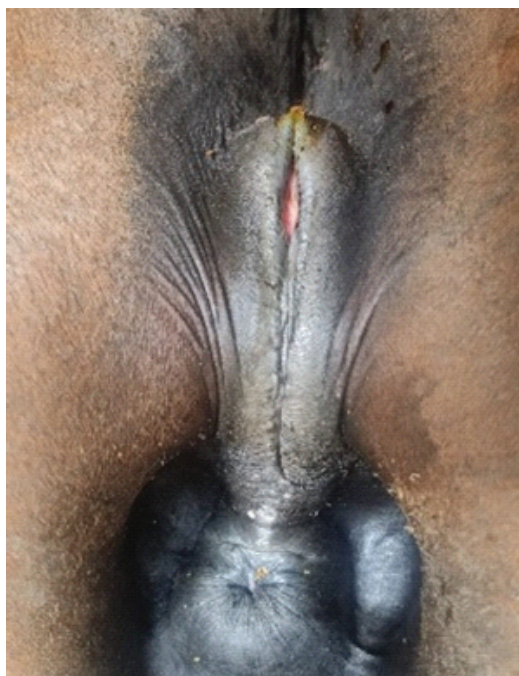
with foul smelling and flocculent purulent discharge. Rectal examination indicated uterine distension and on ultrasonography uterine distension was found to be 3.95 cm in diameter with hyperechoic pus. Furthermore, wind sucker test was performed to identify pneumovagina and it was positive. Based on clinical evaluation and ultrasonography, the case was diagnosed as chronic endometritis due to pneumovagina.

### **TREATMENT AND DISCUSSION**

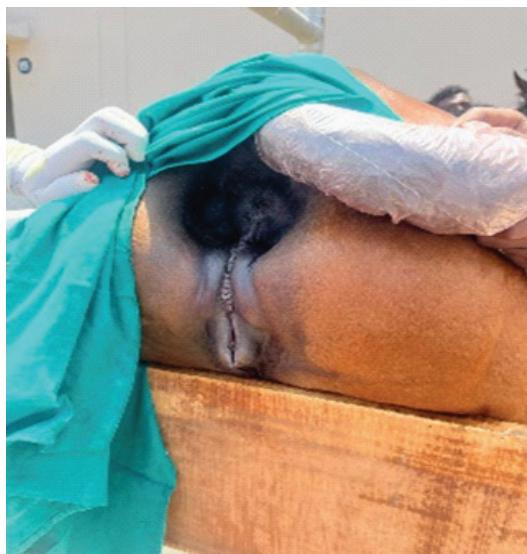A sample of the purulent discharge was collected for microbial culture and antibiotic sensitivity testing. The culture revealed gram-negative cocci bacteria, which were sensitive to enrofloxacin, gentamicin, and ceftiofur. The treatment plan included administration of gentamicin (4 mg/kg), oxytocin (30 IU) and flunixinmeoglumine (1.1 mg/kg) for five days. Additionally, uterine lavage was performed using a 1% potassium permanganate solution. The modified Caslick's operation was performed after resolving clinical signs of endometritis. The site was aseptically prepared, and 2% lignocaine hydrochloride was infiltrated around the mucocutaneous junctions of perineal and vulval region. Further, the mucocutaneous tissue of the vulva was scarified about two-thirds from the dorsal commissure to ventral commissure and suture was applied by using Ford interlock suture pattern using PGA 1.0 and followed by outer skin by interrupted suture pattern using 2-0 nylon suture material(Fig.2). The suture was removed after 10 day of surgery and the animal had uneventful recovery.

The present case highlights the significance of treatment strategy to resolve the recurrent endometritis in mares caused by pneumovagina, particularly in aged Thoroughbred mares with poor vulvar conformation. The surgical correction through modified Caslick's operation proved to be a highly effective method in preventing further complications (Van Ittersum and Van Buiten, 1999). Pneumovagina leads to the entry of air and contaminants, predisposing mares to genital tract infections such as endometritis, which directly impacts health of the animal. In this case, a comprehensive treatment approach, including antibiotic

therapy and uterine lavage, resolve the infection prior to the surgical correction. The mare recovered fully and it was evidenced by the negative wind-sucker test after surgery and absence of recurrence which emphasizes the importance of early diagnosis and treatment in such cases. Timely intervention not only improves the health of the mare but also helps restore reproductive potential, which is crucial especially for breeding animals. The present case highlights the effectiveness of modified Caslick's operation otherwise called n mares with pneumovagina which is major cause for recurrent or chronic endometritis in horse



**Fig. 1** Sunken anus and sloping vulval lips



**Fig. 2** After Caslick's Operation

## ACKNOWLEDGEMENT

The authors are thankful to the Dean and the Associate Professor and Head, Veterinary Clinical Complex, Veterinary College and Research Institute, Salem, Tamil Nadu Veterinary and Animal Sciences University, India for providing the necessary facilities to carry out this study.

## CONFLICT OF INTEREST

The authors declare no conflict of interest.

## REFERENCES

- Arnold, L. and Stout, T. (2022). Indications for and how to perform Caslick's operation in mare. *UKVETEQUINE*, 6(1).
- Baharudin, F. and Sabri. J., (2019). Prevalence, influential factors, and oestrus behaviour of mares with pneumovagina in a tropical region. *Advances in Animal and Veterinary Sciences*, 7. 937 – 943.
- Dascanio, J.J. (2021). Caslick operation or Vulvoplasty, *Equine Reproductive procedures* (2 Edn.). Hoboken NJ: Wiley-Blackwell, pp.191-194.
- Filho, D.L.J., Dall'Acqua, P.C., Mariano, R.S.G., Basile, R.C., Oliveira, M.G., Bonato, D.V. and Vrisman, D.P. (2015). Pneumovagina and urovagina in mares – literature Review. *Nucleus Animalium*, 7: 71-80.
- Newcombe, J.R. (2011). Why are mares with pneumovagina susceptible to bacterial endometritis? a personal opinion. *Journal of Equine Veterinary Science*, 31(4), 174-179.
- Van Ittersum, A.R., and Van Buiten, A. (1999). The prevention of pneumovagina and the effect of the Caslick operation on fertility: a retrospective study. *Tijdschriftvoordiergeneeskunde*, 124(9), 281–283.