

TRANSCERVICAL ALLANTOCENTESIS IN THE MANAGEMENT OF HYDRALLANTOIS IN A CROSSBRED COW

P.S. Sibhi¹, S.Raja^{2*}, D. Gopikrishnan³, M. Murugan⁴, V. Prabakaran⁵,
M. Palanisamy⁶ and M. Selvaraju⁷

*Department of Veterinary Gynaecology and Obstetrics
Veterinary College and Research Institute
Tamil Nadu veterinary and Animal Sciences University
Namakkal, India 637 002*

ABSTRACT

A pluriparous crossbred cow was presented with sudden bilateral abdominal distension. Based on gynaeco-clinical and ultrasonographic investigation, the case was diagnosed for hydrallantois. Medical termination of the pregnancy was initiated using Cloprostenol sodium and dexamethasone. An 18G Rusch catheter was fixed trans-cervically in the uterine cavity to allow gradual drainage of fetal fluid. Complete cervical dilation was observed by 48 hrs post treatment, which permitted the extraction of a deceased male fetus

Keywords: Cow, hydrallantois, transcervical allantoecentesis

Received : 11.06.2025

Revised : 27.06.2025

Accepted : 30.06.2025

INTRODUCTION

Hydrallantois is a common dropsical condition in bovines, characterized by a rapid accumulation of watery, amber-coloured fluid inside the allantoic cavity for over five to 20 days in late gestation (Morrow, 1986). Early diagnosis and prompt therapeutic

intervention is essential to ensure life of the dam. Conventional approach by termination of pregnancy carries risk of sudden expulsion of large volume of fetal fluids potentially leading to hypovolemic shock. The present communication places on record a successful management of hydrallantois by transcervical allantoecentesis approach in a crossbred cow.

CASE HISTORY AND OBSERVATION

A pluriparous Holstein Friesian cow in its fourth parity was presented to Obstetrics Unit of Veterinary Clinical Complex, Veterinary College and Research Institute, Namakkal with sudden abdominal enlargement (Fig.1), seven months post-

¹Final year student

²Assistant Professor, Department of Clinics,

*Corresponding Author email: argoraja@gmail.com,

³Assistant Professor

⁴Assistant Professor, Department of Clinics

⁵Professor

⁶Professor and Head

⁷Dean, Veterinary College and Research Institute, Namakkal 637 002

breeding. Upon clinical examination, the cow exhibited bilateral abdominal distension within normal physiological parameters. Mild congestion and edema were noted in the vulva. Rectal examination revealed a distended gravid horn occupying the entire abdominal cavity. Placentomes and fetus were not palpable. Vaginal examination indicated a constricted external os of the cervix. Transrectal ultrasonography revealed a reduced number of enlarged placentomes, along with fetal fluids exhibiting a hyperechoic speckled appearance. The fetus were not visualized during the examination. Based on the clinical and ultrasonographic observations the case was diagnosed for hydrallantois.

TREATMENT AND DISCUSSION

Medical termination of the pregnancy was carried out by administering inj. cloprostenol sodium (500 mcg) and inj. dexamethasone (32 mg) intramuscularly. One-finger dilatation of cervical internal os could be appreciated by 40 h post-treatment. A 18G Rusch catheter along with the stylet was carefully inserted through the cervix and the allantoic sac was gently punctured by creating a small opening. The catheter was fixed within the allantoic sac by inflating the bulb with 10 ml of air using syringe which facilitated gradual and controlled evacuation of uterine fluid (Fig.2). Around 160 litres of uterine fluid were drained over the period of six hours. Intravenous fluid (Ringer's Lactate – 4 lit and DNS -4 lit) was given throughout the period to compensate the ongoing fluid losses. Complete cervical dilation was observed by 48 hours post-

induction, which allowed for relieving of dead male calf by manual traction. The cow was treated with intramuscular injections of streptopenicillin (2.5 g), flunixin meglumine (8 mL), and chlorpheniramine maleate (12 mL). The therapeutic regimen was continued for three consecutive days. The animal resumed normal feeding the next day and the animal was discharged uneventfully on the fourth day.

Examination of the delivered fetus indicated an estimated gestational age of approximately eight months. When fetal abdomen was explored, fetal kidney was found to be enlarged and revealed minimal fluid accumulation upon sectioning (Fig.3). Histopathological analysis indicated mild hydronephrotic changes, characterized by distended tubules lacking cuboidal epithelium (Fig.4). The fetal membrane, which was manually removed exhibited hyperplasia of the cotyledons and some adventitious areas. Analysis of the fetal fluid revealed elevated levels of urea (34.6 mg/dL), creatinine (10.11 mg/dL), and potassium (6.08 mEq/L) relative to those in the dam.

The management of hydrallantois varies depending on the stage and severity of the condition. In mild cases, it may go undiagnosed until abortion, premature birth, or normal parturition occurs. However, in severe cases, the condition is characterized by an excessive accumulation of fluid, often accompanied by a poorly viable or defective fetus (Roberts, 1986). Increased hydraulic pressure on the diaphragm due to massive abdominal enlargement could cause

breathing difficulties which necessitates prompt attempt on uterine evacuation and pregnancy termination through the use of prostaglandins or caesarean section. Rapid expulsion of large volumes of allantoic fluid from the uterus could lead to hypovolemic shock due to splanchnic pooling of blood (Misri, 2001). The allantocentesis performed using a Rusch catheter facilitated the gradual removal of excess allantoic fluid, thus avoiding sudden expulsion of voluminous fluid (Manokaran *et al.*, 2011; Prabakaran *et al.*, 2018). In conclusion, the successful management of hydrallantois in cattle requires induction of parturition followed by transcervical allantocentesis for gradual

removal of allantoic fluid, simultaneous intravenous fluid replacement and relieving of deceased fetus. This case illustrated effective treatment of bovine hydrallantois through a combined approach of parturition induction and controlled transcervical allantocentesis.

ACKNOWLEDGEMENT

The authors thank the Dean, Veterinary College and Research Institute, Namakkal and the Director of Clinics, TANUVAS, Chennai -7 for the facilities provided for the study.




Fig.1. Bilateral abdominal distention

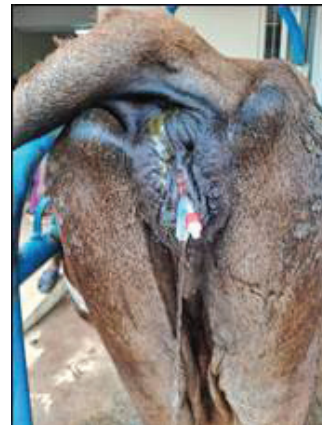

Fig.2. Transcervical Fixation of Catheter

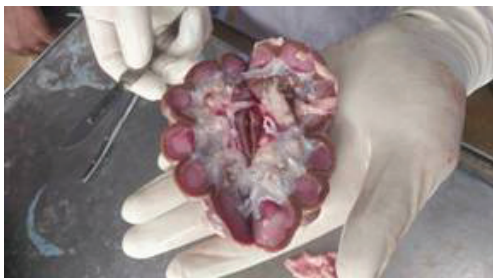

Fig.3. Dissected fetal kidney

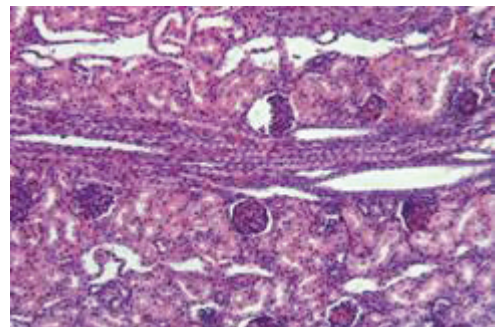


Fig.4. Histopathology of fetal kidney showing distention of renal tubules

REFERENCES

- Manokaran, S., Ravikumar, K., Ezakial Napoleon, R., Palanisamy, M. and Selvaraju, M. (2011). Hydrallantois in a non-descript buffalo: a case report. *The Indian Journal of Field Veterinarians*, 7:69.
- Misri, J. (2001). Hydrallantois in a goat. *Indian Veterinary Journal*, 78:255–256.
- Morrow, A.D. (1986). Current Therapy in Theriogenology. WB Saunders Company.
- Prabaharan, V., Sukumar, M., Jayaganthan, P., Raja, S., Rajkumar, R. and Palanisamy, M. (2018). Clinical management of hydrallantois due to fetal meningocele in a non-descriptive cow. *International Journal of Science, Environment and Technology*, 7(6):2004–2010.
- Roberts S J. 1986. Veterinary Obstetrics and Genital diseases. 3rd ed. David and Charles Inc, North pomfret Vermont 05053: 223-225.