

A CASE REPORT OF *TOXOCARA CATI* INFECTION IN A DOMESTIC SHORTHAIR CAT FROM UDUMALPET, TAMIL NADU: CLINICAL AND ZONOTIC IMPLICATIONS

T. Rama¹, M. Palanivelrajan^{2*}, N. Rani³, V. Naveenkumar⁴ and D. Chandrasekaran⁵

*Veterinary Clinical Complex
Veterinary College and Research Institute
Tamil Nadu Veterinary and Animal Sciences University
Udumalpet – 642205*

ABSTRACT

*Toxocariasis is a parasitic zoonotic disease of public health significance, especially in children, causing visceral and ocular larva migrans. While *Toxocara canis* in dogs is well-documented, *T. cati* in cats also poses a notable risk but remains underreported, underscoring the need for greater attention to feline sources. This paper reports a case of *T. cati* infection in a domestic cat diagnosed at the Veterinary Clinical Complex, Veterinary College and Research Institute, Udumalpet, Tamil Nadu. A 4-month-old female domestic shorthair kitten was presented with a history of inappetence and vomiting with white-coloured worms expelled in the vomitus for the past two days. Clinical examination revealed that the animal was moderately dehydrated and visible mucous membranes were slightly pale. The faecal examination by direct smear and flotation did not reveal the presence of ova of parasites. Based on the morphological features of the adult worms recovered from the vomitus, it was identified *T. cati*. This report is made to highlight the epidemiological and zoonotic significance of *T. cati*, besides to emphasize the importance of deworming and personal hygiene, to prevent transmission of parasitic diseases from animal to man.*

Keywords: Deworming, sanitation, *Toxocara cati*, vomiting, zoonotic disease

Received : 17.06.2024

Revised : 19.09.2025

Accepted : 29.10.2025

¹Assistant Professor,

²Associate Professor, Department of Veterinary Medicine, *Corresponding Author Email: palanivelrajan.m@tanuvas.ac.in& palanivet@gmail.com

³Professor, Department of Veterinary Parasitology,

⁴Assistant Professor,

⁵Professor and Head,

INTRODUCTION

Zoonotic diseases pose significant and persistent public health challenges, highlighting the critical role of veterinary surveillance in early detection and control (Sharan *et al.*, 2023). Among them, toxocariasis is a globally prevalent yet

underrecognized helminthic zoonosis caused by *Toxocara canis* in dogs and *Toxocara cati* in cats. This infection has major veterinary and public health relevance due to its ability to cause severe outcomes in humans, including visceral and ocular larva migrans and its association with allergic disorders and cognitive impairments (Chen *et al.*, 2018; Nikopoulou *et al.*, 2025).

A meta-analysis encompassing 253 datasets from 71 countries estimated the global seroprevalence of human toxocariasis at 19.0%, corresponding to approximately 1.4 billion individuals exposed to *Toxocara spp.* (Rostami *et al.*, 2020a). In dogs, the global prevalence of *T. canis* has been reported at 11.1%, with notably higher infection rates in stray and young animals. Regional variability is considerable, with prevalence ranging from 6.4% in the Western Pacific to 19.2% in the Eastern Mediterranean (Rostami *et al.*, 2020b). The greater attention directed toward canine toxocariasis is attributed to the role of dogs as prominent environmental contaminators and their frequent close contact with humans, thereby facilitating zoonotic transmission (Mubarak *et al.*, 2023). Conversely, *T. cati* in felines although equally zoonotic, is often unnoticed in public health frameworks. This disparity may stem from the solitary nature of cats, underdiagnosis due to the subclinical nature of adult infections and limited routine deworming practices, especially in stray populations (Overgaauw and Knapen, 2013). However, epidemiological evidence indicates a significant burden of infection in cats, with a global pooled prevalence of 17.0%. Stray cats exhibit a prevalence of

28.6%, while kittens (≤ 12 months) show 27.7%, highlighting the susceptibility of young animal (Rostami *et al.*, 2020a).

T. cati follows a direct life cycle, with transmission via ingestion of embryonated eggs, infected paratenic hosts or transmammmary routes (Traversa, 2012). Cats act as definitive hosts, harboring adult worms in the small intestine. Toxocariasis is diagnosed in animals by detecting eggs through faecal flotation, whereas in humans, serological tests like ELISA targeting TES antigens are preferred due to the larvae's migratory nature and absence of eggs in stool (Fillaux and Magnaval, 2013). However, cross-reactivity with other helminths may affect specificity, requiring confirmatory testing or clinical correlation in endemic areas.

Toxocariasis in dogs has been widely reported across India, particularly in stray dog populations in urban areas, with prevalence rates indicating a significant zoonotic risk (Traub *et al.*, 2005; Sudhakar *et al.*, 2013). Studies on *T. cati* in cats have also been conducted, with reports highlighting its presence in both domestic and stray cats, notably in regions such as Tamil Nadu and Maharashtra (Traub *et al.*, 2005; Thomas and Jeyathilakan, 2014; Bhangale *et al.*, 2021). However, a substantial research gap exists, particularly in cats, where limited data on prevalence, transmission dynamics, and effective control measures hinders a comprehensive understanding. In contrast to dogs, there is a lack of studies focusing on the rural and remote areas where stray cat populations may contribute to environmental contamination, posing a growing public health concern.

This report discusses a clinical case of *Toxocara cati* infection in a domestic kitten, detailing the clinical presentation, parasitological findings, and potential zoonotic implications. Enhanced understanding of the epidemiology, lifecycle, transmission, and diagnostic approaches of *T. cati* is essential for formulating effective control strategies and mitigating the broader public health impact of this neglected zoonosis.

MATERIALS AND METHODS

A 4-month-old female domestic shorthair kitten was presented with the history of inappetence and vomiting at Veterinary Clinical Complex, Veterinary College and Research Institute, Udumalpet. During the clinical examination, condition of the animal was dull and depressed, rectal temperature and heart rate was normal, visible mucous membrane was pale pink, moist and white-colored worms were expelled from vomitus. The kitten had no prior history of deworming or vaccination. Faecal samples were collected and examined by direct smear and flotation techniques for parasite eggs. Vomited worms were collected in sterile container containing normal saline for further study. The worms were processed as per standard nematode clearing procedure and examined under binocular research microscope for specific identification.

RESULTS AND DISCUSSION

In this study, a case of toxocariasis infection was confirmed in a kitten. The household comprised two kittens, including

the affected one, both with regular outdoor access and no history of deworming which increases the risk of *T. cati* transmission.

Both male and female *T. cati* worms were recovered from the vomitus of the affected kitten. Clinical examination revealed a normal rectal temperature (100.4°F), slightly pale mucous membranes and moderate dehydration was observed. Morphological features of the adult worms observed include two broad, arrowhead-shaped cervical alae at the anterior end and three distinct labial lips (Figure 1). The male worm measured approximately 3 cm in length with a curved posterior end and visible spicules, while the female measured around 4 cm with a straight posterior end and a uterus filled with unembryonated eggs. These morphological characteristics differ notably from those of *T. leonina*, in which female worms possess long, narrow cervical alae and the male lacks the finger-like projection at the posterior end. These features are consistent with standard descriptions of *T. cati* morphology (Figure 1a and 1b), confirming the specific identification. These findings are consistent with previously published literature on *T. cati*. Gibbons (2010) described the characteristic broad, arrowhead-shaped cervical alae and three distinct labial lips, which were clearly observed in our specimens, supporting species-level identification. Traversa (2012) highlighted the significance of sexual dimorphism, noting features such as the curved posterior end and spicules in males and the egg-filled uterus in females; these features were also distinctly present in our samples. Mahdy

et al. (2020) documented similar body measurements and reproductive structures in *T. cati* recovered from felines, which further corroborates the morphometric and diagnostic observations made in the current study.

In this study, *T. cati* eggs could not be detected in the faecal sample, despite the presence of adult male and female worms in the vomitus. This observation confirms the findings of earlier studies suggesting that the absence of eggs may result from the prepatent period, during which adult worms are present but egg production has not yet commenced (Lesniak *et al.*, 2017). Additionally, it is possible that the female worms were immature or not yet gravid, or that egg shedding was intermittent and below the detection level through conventional faecal examination methods. These explanations underscore the importance of morphological examination in suspected cases with negative faecal results.

T. cati, a common ascarid of domestic and stray felines, is a globally prevalent parasite with significant zoonotic potential. Infection in cats occurs through ingestion of embryonated eggs from contaminated environments, consumption of infected paratenic hosts (e.g., rodents, birds) or via trans-mammary transmission in kittens (Bakhshani *et al.*, 2019). Infected cats, particularly those asymptomatic, contribute substantially to environmental contamination by shedding eggs that can remain viable in soil for extended periods, increasing the likelihood of transmission to other felines through contaminated surfaces or prey (Overgaauw and Knapen,

2013). This environmental contamination also poses a significant zoonotic challenge, particularly in urban settings where human–cat interactions are frequent and sanitation may be compromised.

Humans, especially children, become unnatural/aberrant hosts through ingestion of embryonated eggs via contaminated soil, water, or fomites. Once inside the human host, larvae do not mature but migrate through tissues, leading to severe clinical manifestations. Visceral larva migrans (VLM) is characterized by hepatomegaly, eosinophilia, fever and pulmonary signs, while ocular larva migrans (OLM) may result in unilateral visual impairment, retinal granulomas or blindness (Magnaval *et al.*, 2001; Chen *et al.*, 2018; Nikopoulou *et al.*, 2025). Covert toxocariasis, a more subtle presentation, includes fatigue, respiratory symptoms, and behavioral changes, potentially linked to chronic immune stimulation.

Despite its public health importance, feline-associated toxocariasis remains underreported compared to canine infections. This discrepancy is largely due to the asymptomatic nature of adult cat infections, limited routine veterinary screening and lack of awareness among clinicians (Rostami *et al.*, 2020a). Moreover, the intermittent or low-level shedding of eggs complicates faecal-based diagnostics, leading to diagnostic underestimation (Lesniak *et al.*, 2017).

To mitigate the zoonotic risk posed by *T. cati*, comprehensive control strategies are essential. These include routine

deworming of domestic cats, particularly kittens, using broad-spectrum anthelmintics, along with proper disposal of feline feces to prevent soil contamination. Promoting personal hygiene, especially hand washing after soil contact or pet handling, washing hands thoroughly with soap and water after contact, especially before eating, after feeding, or after cleaning up cats. The practice of washing hands after touching cats habitats or equipment, such as cages and toys and before preparing food. Maintaining pet's hygiene through regular grooming, bathing, and cleaning their environment also helps prevent worm infection and implementing public education campaigns can significantly reduce transmission.

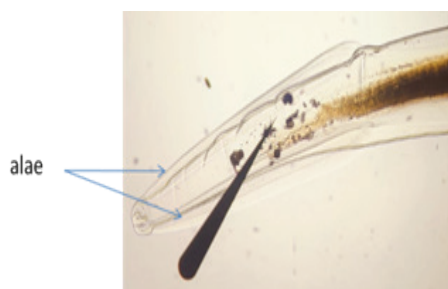CONCLUSION

The present report revealed that the clinical and zoonotic significance of *Toxocara cati* infection in felines, particularly given its potential to cause severe manifestations such as visceral and ocular larva migrans in humans. Although faecal examination did not reveal the presence of *Toxocara* spp. eggs, adult worms recovered from the vomitus were

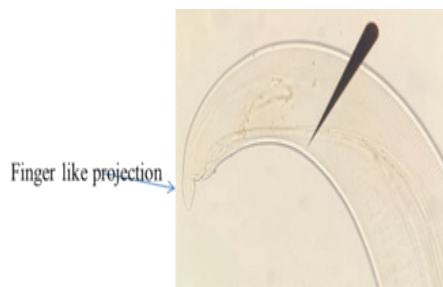
morphologically identified as *T. cati*, highlighting the limitations of sole reliance on faecal diagnostics. The findings reinforce the critical need for regular anthelmintic interventions, stringent hygiene practices and responsible pet ownership to reduce environmental contamination and human exposure. Public education initiatives and targeted awareness campaigns are essential to enhance understanding of feline-mediated zoonosis. Moreover, increased epidemiological surveillance and focused research on feline toxocariasis are imperative for the formulation of evidence-based strategies that support integrated One Health approaches to parasite control and public health protection.

ACKNOWLEDGEMENT

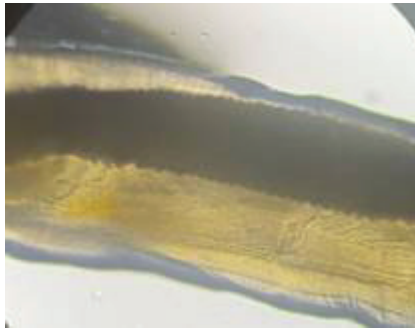
The authors are thankful to the Dean, Veterinary College and Research Institute, Tamil Nadu Veterinary and Animal Sciences University, Udumalpet, the Professor and Head, Veterinary Clinical Complex, Veterinary College and Research Institute, Udumalpet and the Director of Clinics, Tamil Nadu Veterinary and Animal Sciences University, Chennai for facilities rendered.



(a)



(b)



(c)

Fig.1. a. Males and females have two broad, arrow head shaped lateral cervical alae at the anterior end, and three “lips” (one dorsal and two subventral lips); b. Males have a short finger-like projection at the posterior end. c. eggs filled uterus in female worms (magnification: 10X)

REFERENCES

- Bakhshani, A., Maleki, M., Haghparast, A., Shirvan, S P. and Borji, H. (2019). A survey on *Toxocara cati* eggs on the hair of stray cats: a potential risk factor for human toxocariasis in Northeastern Iran. *Comparative Immunology Microbiology and Infectious Diseases*, **64**:10-13.
- Bhangale, G.N., Narladkar, B.W. and Tayde, R.S. (2021). Systematic review and meta-analysis on the risk potential of zoonotic toxocariasis from soil contamination of public places in India. *Veterinary Parasitology: Regional Studies and Reports*, **24**: 100560.
- Chen, J., Liu, Q., Liu, G.H., Zheng, W.B., Hong, S.J., Sugiyama, H., Sugiyama, H., Zhu, X.Q. and Elsheikha, H. M. (2018). Toxocariasis: a silent threat with a progressive public health impact. *Infectious diseases of poverty*, **7**: 59.
- Filliaux, J. and Magnaval, J.F. (2013). Laboratory diagnosis of human toxocariasis. *Veterinary Parasitology*, **193**(4): 327-336.
- Gibbons, L.M. (2010): Keys to the Nematode Parasites of Vertebrates. Supplementary Volume CAB International, Wallingford (UK). 416. ISBN-13: 978-1-84593-571-9.
- Lesniak, I., Heckmann, I., Heitlinger, E., Szentiks, C.A., Nowak, C., Harms, V., Jarausch, A., Reinhardt, I., Kluth, G., Hofer, H. and Krone, O. (2017). Population expansion and individual age affect endoparasite richness and diversity in a recolonising large carnivore population. *Scientific Reports*, **7**: 41730.
- MagnaVal, J.F., Glickman, L.T., Dorchie, P. and Morassin, B. (2001). Highlights of human toxocariasis. *The Korean journal of parasitology*, **39**(1): 1-11.

- Mahdy, O.A., Mousa, W.M., Abdel-Maogood, S.Z., Nader, S.M., and Abdel-Radi, S. (2020). Molecular characterization and phylogenetic analysis of *Toxocara* species in dogs, cattle and buffalo in Egypt. *Helminthologia*, **57**(2): 83-90.
- Mubarak, A.G., Mohammed, E.S., Elaadli, H., Alzaylaee, H., Hamad, R.S., Elkholy, W.A. and Youseef, A.G. (2023). Prevalence and risk factors associated with *Toxocara canis* in dogs and humans in Egypt: A comparative approach. *Veterinary medicine and science*, **9**(6): 2475-2484.
- Nikopoulou, A., Sideras, L., Peristeri, A.M., Ligda, P., Akritidou, O. and Sotiraki, S. (2025). Human toxocarosis: presenting a case report of eosinophilic myocarditis associated with *Toxocara canis* infection and a literature review. *Microbiology Research*, **16**(3): 58.
- Overgaauw, P.A.M. and Knapen, F. (2013). Veterinary and public health aspects of *Toxocara* spp. *Veterinary Parasitology*, **193**(4): 398-403.
- Rostami, A., Sepidarkish, M., Ma, G., Wang, T., Ebrahimi, M., Fakhri, Y., Mirjalali, H., Hofmann, A., Macpherson, C.N.L., Hotez, P.J. and Gasser, R. B. (2020a). Global prevalence of *Toxocara* infection in cats. *Advances in Parasitology*, **109**: 615-639.
- Rostami, A., Riahi, S. M., Hofmann, A., Ma, G., Wang, T., Behniafar, H., Taghipour, A., Fakhri, Y., Spotin, A., Chang, B.C.H., Macpherson, C.N.L., Hotez, P.J. and Gasser, R.B. (2020b). Global prevalence of *Toxocara* infection in dogs. *Advances in Parasitology*, **109**: 561-583.
- Sharan, M., Vijay, D., Yadav, J.P., Bedi, J.S. and Dhaka, P. (2023). Surveillance and response strategies for zoonotic diseases: a comprehensive review. *Science in One Health*, **2**: 100050.
- Thomas, D. and Jeyathilakan, N. (2014). Detection of *Toxocara* eggs in contaminated soil from various public places of Chennai city and detailed correlation with literature. *Journal of parasitic diseases*, **38**(2): 174-180.
- Traub, R.J., Robertson, I.D., Irwin, P.J., Mencke, N. and Thompson, R.A. (2005). Canine gastrointestinal parasitic zoonoses in India. *Trends in parasitology*, **21**(1): 42-48.
- Traversa, D. (2012). Pet roundworms and hookworms: A continuing need for global warming. *Parasites and Vectors*, **5**: 91.