

**A RARE PRESENTATION OF *SCHISTOSOMUS REFLEXUS*
WITH POUCHED HINDQUARTERS IN A
CROSSBRED JERSEY COW**

**M. Palanisamy¹, S. Raja^{*2}, D. Gopikrishnan³, M. Murugan⁴, V.
Prabakaran⁵ and M. Selvaraju⁶**

*Department of Veterinary Gynaecology and Obstetrics
Veterinary College and Research Institute
Tamil Nadu Veterinary and Animal Sciences University
Namakkal - 637 002*

ABSTRACT

A case of pouched schistosomus reflexus in a crossbred Jersey cow was delivered per vaginam with obstetrical assistance. This report emphasizes the significance of timely obstetrical intervention in managing dystocia due to congenital anomalies.

Keywords: Crossbred Jersey cow, dystocia, *Schistosomus reflexus*

Received : 06.10.2025

Revised : 16.10.2025

Accepted : 31.10.2025

INTRODUCTION

Congenital anomalies in domestic animals are relatively uncommon but are of considerable clinical and economic significance, particularly when they result in dystocia. Among these anomalies, schistosomus reflexus is one of the most frequently reported fetal monstrosities in cattle, buffaloes, goats, and swine

(Suthar *et al.*, 2011; Ravikumar *et al.*, 2014). It is a severe developmental defect characterized by marked ventral curvature of the spinal column, ankylosed rigid limbs, malformation of the pelvis, and exposure of the thoracic and abdominal viscera (Roberts, 1971). The condition often results in dystocia, which poses serious risks to the survival of both dam and fetus. *Schistosomus reflexus* is typically sporadic and considered a non-genetic, non-hereditary anomaly, arising during embryogenesis (Ozsoy *et al.*, 2009). Its incidence is low, but due to the severity of malformations, it often requires obstetrical interventions such as fetotomy or caesarean section (Palanisamy *et al.*, 2018). Rare variations in this anomaly include encapsulation of body parts by reflected or inverted skin, forming pouch-like structures

¹Professor and Head

²Assistant Professor, Department of Clinics,

*Corresponding author Email id: argoraja@gmail.com

³Assistant Professor,

⁴Assistant Professor, Department of Clinics

⁵Professor

⁶Dean, Veterinary College and Research Institute,
Namakkal - 637 002

(Mansour *et al.*, 2017; Prakash *et al.*, 2021). Such cases are seldom reported and this highlights the importance of documenting such unusual presentations. The present case describes a rare manifestation of pouched schistosomus reflexus in a crossbred Jersey cow which was delivered per vaginam with mutational operation.

CASE HISTORY AND OBSERVATION

A full-term pregnant crossbred Jersey cow in its second parity was presented to the Obstetrics Unit of the Veterinary Clinical Complex, Veterinary College and Research Institute, Namakkal, with a history of water bag ruptured five hours back with no progress, and the dam exhibited signs of exhaustion. Upon clinical examination, the cow was found to be dull and depressed, remaining in sternal recumbency. The rectal temperature was recorded at 102°F. Marked vulvar edema and congestion were also observed. Vaginal examination revealed a dry, edematous birth canal with a fully dilated cervix. The fetus was lodged in the birth canal, with fetal viscera extended into the passage. The fore and hind limbs were not palpable. Careful manipulation revealed ankylosed fetal joints and exposure of abdominal contents through the vulva. Based on the clinical examination, the condition was diagnosed as dystocia due to fetal monstrosity.

TREATMENT AND DISCUSSION

The cow was restrained in a hindquarter-elevator for ease of handling the dystocia. Epidural anaesthesia was induced by administering 3 ml of 2% lignocaine

hydrochloride at sacro-coccygeal space to control the straining. An obstetrical lubricant using medium viscous carboxy methyl cellulose solution @ 2 per cent was used to facilitate delivery. The malformed fetus was extracted per vaginam using a long obstetrical eyehook with careful obstetrical operation; briefly, the stump of the fetus was pulled with the help of eye hook and the fetus was delivered by forceful traction. Following delivery, the dam was treated with intravenous administration of 20% dextrose (1 L), oxytocin (30 IU), streptopenicillin (5 gm) and chlorpheniramine maleate (10 mL) intramuscularly for three days. The cow made an uneventful recovery.

On gross examination, the fetus weighed 18.5 kg and displayed severe congenital malformations. There was acute angulation of the spinal column, ankylosis of the joints, rigid limbs, exposure of abdominal viscera, and partial thoracic viscera. The diaphragm was incomplete, the lungs were hypoplastic, and the abdominal viscera were congested. The rumen appeared distended (Fig. 1). The unique feature in this case was the presence of a thick, whitish, glistening membranous sac enclosing the pelvis and hind limbs. On incision, the inner surface of the sac was covered with hair coat, confirming that it was an inverted pouch of abdominal skin (Fig. 2). This rare manifestation was therefore diagnosed as pouched schistosomus reflexus.

The uniqueness of this case lies in the presence of an encapsulating membranous pouch covering the head, pelvis and fore limbs. Similar but rare presentations have been reported previously,

such as encapsulation of the head and forelimbs within reflected skin (Prakash *et al.*, 2021) and complete coverage of fetal parts by membranous sacs (Mansour *et al.*, 2017). However, in this case, the inverted abdominal skin had fused with the opposite side, forming a distinct pouch that enclosed not only the hindquarters but also the forelimbs and hindlimbs. This rare manifestation justifies the classification as pouched schistosomus reflexus.

Schistosomus reflexus is a well-documented congenital anomaly in ruminants, characterized by severe ventral curvature of the spine, ankylosed limbs, malformed pelvis, and exposure of thoracic and abdominal viscera (Ravikumar *et al.*, 2014; Palanisamy *et al.*, 2018). While most cases require fetotomy or caesarean section due to the size and rigidity of the malformed fetus, smaller-sized monsters, as in this report, may be delivered per vaginam with appropriate obstetrical assistance (Selvaraju *et al.*, 2020). Similar cases have been described in buffaloes (Kumar *et al.*, 2015) and goats (Suthar *et al.*, 2011), highlighting the cross-species occurrence of this anomaly.

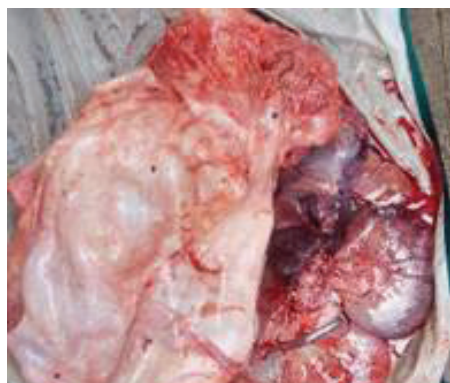

Fig.1. Encapsulating membranous pouch around the schistosomus reflexus fetus

Cutaneous malformations associated with fetal monstrosities are considered extremely rare among congenital anomalies. The etiology of schistosomus reflexus remains unclear but is generally considered non-genetic and non-hereditary, likely arising during embryonic development (Ozsoy *et al.*, 2009). Environmental, nutritional, and teratogenic factors may contribute, though further studies are necessary to clarify the pathogenesis (Mansour *et al.*, 2017; Palanisamy *et al.*, 2018). This report adds to the limited documentation of such rare congenital anomalies in cattle. Prompt recognition of dystocia caused by fetal monstrosities and timely obstetrical intervention are crucial to safeguard maternal health and ensure recovery.

ACKNOWLEDGEMENT

The authors gratefully acknowledge the Dean, Veterinary College and Research Institute, Namakkal, and the Director of Clinics, TANUVAS, Chennai, for the facility provided for the study.

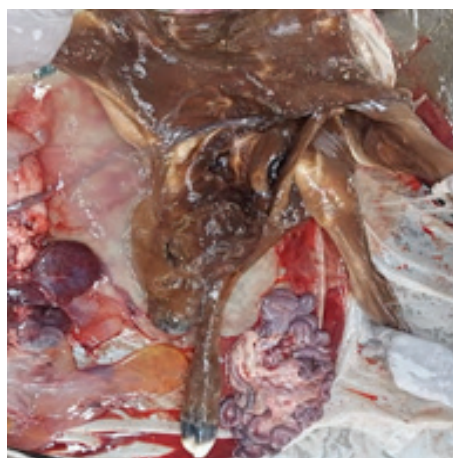


Fig .2. Inverted pouch of abdominal skin on exploration of pouch

REFERENCES

- Kumar, P., Nanda, A.S. and Singh, P. (2015). Schistosomus reflexus in a buffalo: a case report. *Buffalo Bulletin*, **34**(1):113-116.
- Mansour, N., Almadaly, E., Karen, A. and Ramoun, A. (2017). Schistosomus reflexus fetus in a cross-breed Egyptian cow: a case report. *Global Veterinarian*, **18**(2):105-107.
- Ozsoy, S.Y., Oto, C. and Hazirolu, R. (2009). Schistosoma reflexum in a dog. *Veterinary Journal Ankara University*, **56**:225.
- Palanisamy, M., Manokaran, S., Vikramachakravarthi, P., Napoleon, R.E., Selvaraju, M. and Prakash, S. (2018). Dystocia due to schistosomus reflexus in a Holstein Friesian crossbred heifer. *Indian Veterinary Journal*, **95**(2):51-52.
- Prakash, S., Prabakaran, V., Raja, S. and Satheshkumar, S. (2021). A rare case of pouched Schistosomus reflexus in a crossbred cow. *Indian Journal of Veterinary and Animal Sciences Research*, **51**(1):90-94.
- Ravikumar, K., Selvaraju, M., Kumaresan, A., Sivaraman, S., Prakash, S. and Lavanya, C. (2014). Dystocia due to schistosomus reflexus along with vaginal tear in a Tellicherry doe. *Indian Veterinary Journal*, **91**(9):99-100.
- Roberts, S.J. (1971). *Veterinary Obstetrics and Genital Diseases*. 2nd ed., CBS Publishers and Distributors, Delhi, pp.284-285.
- Selvaraju, M., Prakash, S., Varudharajan, V., Ravikumar, K., Palanisamy, M., Gopikrishnan, D., Senthilkumar, K. and Manokaran, S. (2020). Obstetrical disorders in farm animals: a review. *The Pharma Innovation Journal*, SP-**9**(9):65-74.
- Suthar, D.N., Sharma, V.K., Dabas, V.S. and Bhoi, D.B. (2011). Per-vaginal handling of Schistosomus reflexus as a cause of dystocia in a goat. *Veterinary World*, **4**(7):330.