Indian J. Vet. Pathol., 50(4) : 291-299, 2026: DOI: https://doi.org/10.56093/b928xd65

REVIEW ARTICLE

Small ruminant lentiviruses: Current perspective on pathogenesis, pathology and diagnostic approaches

Pawan Kumar[1*], Sreelakshmi P.[1], Monika Bhardwaj[2], Shweta Valecha[1], Hiteshwar Singh Yadav[1], Sonali Mishra[3], Kumar K. [1], Siddharth Gautam[1], Vidya Singh[1] and Rajveer Singh Pawaiya[1]

[1]Division of Pathology, ICAR- Indian Veterinary Research Institute, Izatnagar, Bareilly, Uttar Pradesh-243122 (INDIA)
[2]Department of Veterinary Microbiology, COVAS, CSKHPKV, Palampur, Himachal Pradesh-176062 (INDIA)
[3]Department of Veterinary Pathology, COVAS, CSKHPKV, Palampur, Himachal Pradesh-176062 (INDIA)

***Address of correspondence**
Dr. Pawan Kumar, Senior Scientist, E-mail: chauhan2k1@gmail.com
ORCID ID: 0000-0002-0024-8925, 0009-0002-9002-6695

Received: 25-6-26; Accepted: 10-8-26

ABSTRACT

Small ruminant lentiviruses (SRLVs) are important retroviral pathogens of sheep and goats belonging to the genus Lentivirus within the family *Retroviridae*. These viruses are responsible for two major chronic diseases in small ruminants viz. maedi-visna (MV) and caprine arthritis encephalitis (CAE). SRLV infections are characterized by prolonged incubation periods, lifelong persistence, and progressive multisystemic inflammatory lesions affecting the respiratory, nervous, mammary, and musculoskeletal systems. Transmission occurs primarily through respiratory secretions and ingestion of infected colostrum or milk, while transplacental and semen-mediated transmission have also been documented. SRLVs establish persistent infection through integration of proviral DNA into host cells of the monocyte–macrophage lineage, leading to chronic immune-mediated pathology. Viral genetic diversity, antigenic variation, and the ability to infect multiple domestic and wild ruminant species complicate disease control and raise concerns regarding animal health and wildlife conservation. Diagnosis relies on a combination of serological, molecular, pathological, and immunohistochemical approaches, each contributing to improved detection and characterization of infection. Despite advances in diagnostic technologies, effective control remains challenging because of viral persistence, latent infections, and the absence of effective antiviral therapies or commercially successful vaccines. This review summarizes the current understanding of SRLV pathogenesis, pathology, and diagnostic strategies, while highlighting existing challenges for its control.

Keyword: Caprine arthritis encephalitis, Diagnosis, Maedi, Visna, Pathology, Small ruminant lentiviruses (SRLV)

INTRODUCTION

Small ruminant lentiviruses (SRLVs) belong to the genus Lentivirus within the family *Retroviridae* and causes important disease of sheep and goats viz. maedi-visna (MV) and caprine arthritis encephalitis (CAE). Besides lentiviral diseases, retroviruses also caused neoplastic diseases such as ovine pulmonary adenocarcinoma (OPA) and enzootic nasal adenocarcinoma in sheep[1,2,3]. Usually MV is more commonly observed in sheep, and CAE in goats but both species are susceptible to SRLVs infection and show varied range of pathological lesions. These lentiviral diseases are chronic and progressive in nature and produce multi-systemic pathologies. Spread of the infection to the susceptible population usually occurs through aerosol and milk or colostrum, but transmission through placenta and semen is also reported[4]. The prevalence is substantially higher in farms following practice of feeding lambs or kids from pooled colostrum or milk from the tank[5].

SRLVs refers to two distinct viruses viz. MV virus (MVV) and CAE virus (CAEV). Both are put together as SRLVs due to their extensive genetic relatedness[6]. Natural infections involving sheep and goats, as well as mixed infections with multiple viral subtypes, have been reported in several countries[7]. Furthermore, SRLV infections have been documented in wild ruminant species including ibex, mouflon, and chamois[8,9,10]. Isolated reports of mixed pathological lesions of Maedi and OPA/ Mycoplasmosis are also reported[11-13]. SRLVs replicate in the cells of the monocyte-macrophage lineage and establish lifelong persistence through integration of proviral DNA into the host genome. Disease development is primarily mediated by chronic inflammatory responses induced by infected macrophages and lymphocytes in the lungs, mammary glands, central nervous system, and joints[14].

The diagnosis of SRLV infection relies on a combination of serological, molecular, and pathological techniques, while histopathology and immunohistochemistry (IHC) provide valuable support in confirming infection and characterizing tissue lesions[12,14,15].

How to cite this article : Kumar, P., Sreelakshmi, P., Bhardwaj, M., Valecha, S., Yadav, H.S., Mishra, S., Kumar, K., Gautam, S., Singh, V. and Pawaiya, R.S. 2026. Small ruminant lentiviruses: Current perspective on pathogenesis, pathology and diagnostic approaches. Indian J. Vet. Pathol., 50(4) : 291-299.

Despite significant advances in diagnostic methodologies, effective control of SRLV infections remains challenging because of viral persistence, prolonged latent infection, antigenic variation, and the existence of genetically diverse viral strains. Currently, no effective antiviral therapy or commercially successful vaccine is available for the prevention or treatment of SRLV infections.

Etiological agent: SRLVs

The genome of SRLVs consists of a single-stranded, positive-sense RNA molecule approximately 8.4–9.2 kb in length. SRLVs genome contain three major structural genes, viz. *gag*, *pol*, and *env*, flanked by long terminal repeat (LTR) at both the 5′ and 3′ ends[7] (Fig. 1). The *gag* gene encodes the structural proteins of the viral core (matrix, capsid, nucleocapsid proteins); *pol* gene encodes viral enzymes (reverse transcriptase, integrase, protease); and *env* gene encodes the envelope glycoproteins responsible for receptor recognition, host-cell attachment, and membrane fusion. In addition, SRLVs also possess accessory genes, such as *rev*, *vif*, and *vpr-like* gene. The *rev* gene facilitates the nuclear export of incompletely spliced viral transcripts and is essential for efficient viral replication[16,17]; *vif* gene counteract host antiviral restriction factors belonging to the APOBEC3 family and enhance the viral survival and replication[18]; and *vpr-like* gene have role in intracellular trafficking and nuclear localization of pre-integration complex[19]. LTRs present at both 5′ and 3′ ends play a critical role in viral replication by regulating transcription, integration, and polyadenylation of viral transcripts.

Mature SRLV virions are enveloped particles composed of an outer lipid bilayer derived from the host cell membrane and embedded viral surface glycoprotein and transmembrane glycoprotein. SRLVs are reported to have extensive genetic diversity and exhibit high mutation rates. The genetic diversity of SRLVs arises primarily from the error-prone nature of reverse transcription as reverse transcriptase enzyme lacks proofreading activity and leads to frequent nucleotide substitutions and the accumulation of mutations, which ultimately leads to production of heterogeneous population of closely related SRLV variants, referred as viral quasispecies[20,21].

SRLVs: Genotypes and subtypes

Phylogenetic analysis of SRLVs sequences reported from various countries classified SRLVs into five groups (A, B, C, D, and E) based on two long segments, the *gag-pol* (1.8 kb) and the *pol* segment (1.2 kb)[22]. According to HIV classification standards, the nucleotide sequences among these genotypes and subtypes vary by 25-35% and 15-27%, respectively[23]. Genotype A comprises classical MVV strains and several related variants, whereas Genotype B includes the classical CAEV strains. The remaining genotypes (C, D, and E) are less common and are primarily restricted to specific geographical regions within Europe[24,25,26,27,28]. Genotype A is reported to be most heterogenous group comprising of 27 subtypes (A1-A27), whereas Genotype B (subtypes B1-B5) is genetically less diverse as compared to Genotype A[29,30]. The genetic variants circulating among Indian sheep and goat population hitherto remains unknown as only partial sequences targeting the LTR region had been amplified and showed homology with sequences generated from European countries[15].

Epidemiology and transmission of SRLV diseases

Worldwide scenario: A comprehensive analysis of worldwide serological studies demonstrated that SRLV infections are most prevalent in Europe (40.9%) followed by North America (21.8%), Asia (20.4%), Africa (16.7%), and Central and South America (1.7%)[31]. At the flock level, prevalence is generally much higher than individual animal prevalence because infected animals often remain asymptomatic for prolonged periods while continuing to transmit the virus to susceptible population. Among Asian countries, China, Iran, Turkey, Jordan, and Lebanon have reported substantial levels of infection in sheep and goat populations. Similarly, serological surveys conducted in Taiwan, Bangladesh, and Malaysia have demonstrated varying levels of CAEV exposure, reflecting the widespread distribution of SRLV

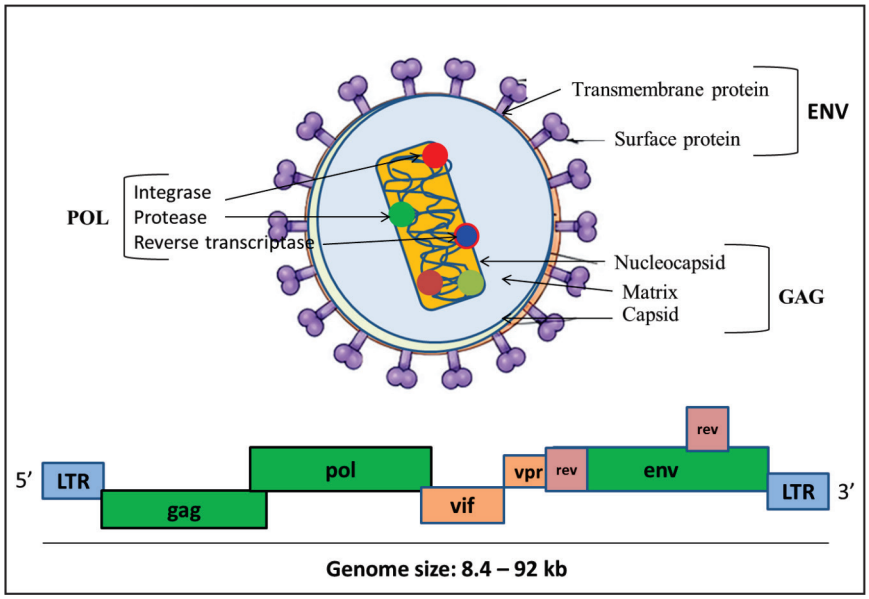

Fig. 1. SRLV genome organization and protein composition (gag, pol, env).

infections throughout the region[32,33]. Australia and New Zealand, have successfully maintained free status from these infections through rigorous surveillance and control programmes. In Iceland outbreak of MV resulted in death of 1 lakh sheep and more than half a million animals culling in order to eradicate MVV[6].

Indian scenario: The history of SRLV infection in India dates back to the 1960s, when maedi-like pulmonary lesions were reported in sheep and goats, although the etiological agent could not be conclusively identified[34]. First report of CAEV antibodies in sera of small ruminant in India reported by Singh et al.[35], where they detected 18 % sero-positivity by AGID and ELISA. Other serological studies conducted in different regions of northern India have reported prevalence rates ranging from 12.17% to 29.16% in sheep and goats[14,15]. Lower prevalence rates have also been reported from Mathura and Andhra Pradesh[36.37]. Molecular detection of proviral DNA of MVV using PCR-based assays has yielded positivity rates ranging from 6.85% to 10.65%, confirming active viral circulation within these populations. Recent investigations have also highlighted the occurrence of mixed infections involving SRLVs and other respiratory pathogens such as jaagsiekte sheep retrovirus (JSRV) and *Mycoplasma* spp.[11] (Table 1).

Transmission: Transmission of SRLVs occurs through both horizontal and vertical routes. Horizontal transmission occurs primarily through prolonged close contact and inhalation of respiratory secretions containing infected monocytes and macrophages, particularly in intensive production systems[40]. Consequently, flock density, ventilation, housing conditions, and management practices substantially influence transmission dynamics[40]. Vertical transmission primarily occurs through the ingestion of infected colostrum and milk. The lactogenic route is considered the most important mechanism for maintaining infection within affected flocks as infected macrophages and monocytes with proviral DNA present in the mammary glands and serve as major sources of virus for newborn lambs and kids[5,41]. In addition, intrauterine transmission has also been reported, however, the epidemiological importance of prenatal transmission remains controversial and appears to be less significant than colostral and milk-borne transmission[42]. SRLV nucleic acids have been detected in semen, indicating the possibility of venereal transmission[43]. Similarly, contaminated instruments and management procedures involving blood transfer may contribute to mechanical transmission under field conditions.

Pathogenesis of SRLVs

The cellular receptor for the SRLVs remains incompletely understood as studies suggested that different SRLV strains may employ distinct cellular receptors, explaining differences in host range, tissue tropism, and pathogenicity[44]. Viral entry in the cell is initiated by interaction between envelope glycoproteins and host-cell receptors, followed by membrane fusion and release of the viral core into the cytoplasm. MHC II, CD4 and CXCR4 proteins suggested as possible receptors for the SRLVs, but none of these have been reported to be the main receptor. It is reported that C type lectins part of the mannose receptor family may act as alternative SRLV receptor as MVV gains entry into the cell via mannosylated residues on its envelope proteins[45].

SRLVs are reported to replicate in the monocyte-macrophage lineage cells and infection to T lymphocytes does not lead to productive infection[46]. Macrophages and dendritic cells are considered the principal target cells for viral replication and dissemination[47,48]. Following entry, the viral RNA genome undergoes reverse transcription to form proviral DNA, which subsequently integrates into the host genome. This integrated provirus establishes a lifelong infection and serves as a template for future viral replication. Although circulating monocytes are readily infected and may harbour integrated proviral DNA, viral replication remains largely restricted until these cells

Table 1. Occurrence/prevalence of SRLVs in Indian sheep and goat population.

S. No.	SRLV infection	Occurrence/ prevalence	Sample type	Methodology	References
1.	CAEV	18 %	Serum	AGID & ELISA	Singh *et al.*[35]
2.	CAEV	3.3 %	Serum	ELISA	Waseem *et al.*[36]
3.	MVV	4.28 %	Serum	ELISA	Didugu *et al.*[37]
4.	CAEV	4.5 %	Serum	ELISA	Didugu *et al.*[37]
5.	SRLVs	12.17 %	Serum	ELISA	Mishra *et al.*[38]
6.	MVV	6.85 %	Lung	Nested PCR	Mishra *et al.*[38]
7.	SRLVs	19.58 %	Serum	ELISA	Kumar *et al.*[14]
8.	MVV	10.41 %	Blood, lung, nasal swabs, mammary gland	Nested PCR	Kumar *et al.*[14]
9.	SRLVs	29.16	Serum	ELISA	Valecha *et al.*[15]
10.	MVV	10.65 %	Blood, lung, mammary gland, joints, brain	Nested PCR	Valecha *et al.*[15]
11.	MVV	2.66 %	Milk	Nested PCR	Yadav *et al.*[39]

differentiate into mature macrophages. This phenomenon has led to the description of infected monocytes as "Trojan horses" that disseminate the virus throughout the host organs while avoiding immune elimination[49].

Viral integration is followed by viral transcription by promoter elements located within the LTR, resulting in the synthesis of viral RNA and proteins that assemble into progeny virions. Newly formed virions bud from the host-cell membrane and mature through proteolytic processing of viral proteins[4,19]. The pathological lesions produced by SRLV infection are largely immune-mediated rather than the direct result of viral cytopathic effects. The infected macrophages within target organs cause continuous antigenic stimulation and recruit mononuclear inflammatory cells to affected tissues through the production of cytokines, chemokines, and other inflammatory mediators. The lungs, mammary glands, joints, and central nervous system represent the principal target organs. Persistent accumulation of lymphocytes, macrophages, and plasma cells within these tissues leads to chronic inflammation, tissue remodeling, and progressive loss of organ function. The resulting chronic inflammatory microenvironment contributes to the development of interstitial pneumonia, non-suppurative mastitis, proliferative arthritis, and encephalomyelitis that are characteristic of SRLV infections[12,14].

Pathology of SRLVs associated diseases

Maedi (ovine progressive pneumonia): Maedi represents the respiratory form of MVV infection, and is the most common clinical manifestation in sheep. The disease is characterized by chronic, progressive, non-febrile interstitial pneumonia that primarily affects adult sheep older than two years of age. Although goats may also develop respiratory disease but the pulmonary lesions are generally more severe and more frequently reported in sheep[5,50]. Clinical signs of maedi often become apparent only after years of subclinical infection and early manifestations include exercise intolerance and reduced physical performance, which progresses to dyspnoea, tachypnoea, abdominal breathing, nostril dilatation, neck extension, and open-mouth breathing. The affected animals show marked weight loss and cachexia despite normal appetite[5].

The lungs of the maedi affected sheep are enlarged, heavy, and fail to collapse upon opening of the thoracic cavity. Affected lungs appear pale grey to pink, firm, rubbery, and diffusely consolidated along with rib impressions on the pleural surface. Mediastinal and tracheobronchial lymph nodes are reported to be enlarged due to chronic lymphoid hyperplasia[51]. Histological hallmark lesion of maedi include chronic lymphocytic interstitial pneumonia, prominent lymphoid follicle formation around bronchioles and blood vessels, and marked thickening of alveolar septa due to infiltration of lymphocytes, plasma cells and macrophages (Fig. 2). Progressive interstitial fibrosis and smooth muscle hyperplasia also reported as consistent finding in many studies. Occurrence of the maedi on basis of histological lesions in the pulmonary affection contributes around 5-6.5%[14,52,53]. The lymphoid follicles in lungs are composed predominantly of CD4+ and CD8+ T lymphocytes[44].

Visna (Neurological Form): Visna represents the neurological manifestation of MVV infection and neurological signs include progressive hind-limb weakness, ataxia, incoordination, paresis, and eventual paralysis. As the disease progress, affected animals may become recumbent and lose weight progressively. Grossly, the pathological lesions are usually absent, however, some cases may exhibit meningeal thickening, granular changes within the choroid plexus, grey discoloration of the brainstem and cerebellum, or focal areas of softening and discoloration within periventricular regions of the brain and spinal cord[54]. Development of chronic non-suppurative encephalomyelitis is main histological lesion observed in visna[55]. Based upon histology, three patterns of lesion have been described *viz*. vascular pattern (perivascular cuffing with lymphocytes and macrophages), infiltrative pattern (diffuse infiltration of MNCs within neural tissues), and malacic pattern (demyelination, tissue degeneration, focal necrosis)[56].

MVV associated lesions also develop in mammary gland and joint tissues. Involvement of mammary gland is considered important manifestations of SRLV infection after the respiratory form[57]. It occurs in both sheep and goats, and characterized by chronic, bilateral and non-painful indurative mastitis often accompanied by enlargement of the supramammary lymph nodes (Fig.2). Histological lesions are characterized by chronic non-suppurative interstitial mastitis with extensive infiltration of lymphocytes, plasma cells, and macrophages around mammary gland acini and lactiferous ducts[54,58]. MVV nucleic acid have been detected in the milk samples of the Indian goats indicating mammary gland involvement[39]. Arthritic form is not commonly reported in MVV infection of sheep, but lesions in carpal and tarsal joints reported in some cases. Microscopically, the joint tissue showed infiltration of MNCs in the synovial membrane and villous hypertrophy[4,5,59].

Caprine arthritis encephalitis (CAE): CAE is characterized by the presence of neurological and arthritic form. Neurological form usually seen in kids between 2-4 months of age and initial clinical signs include ataxia, weakness, lameness, and incoordination, which may progress further to paresis, paralysis, recumbency, and occasional paddling movements[60]. Focal areas of discoloration within the white matter of the brain and spinal cord are frequently observed gross lesion (Fig.2).

Histopathological lesions characterized by chronic non-suppurative leukoencephalomyelitis with perivascular cuffing, demyelination, gliosis, astrocytosis, and infiltration of macrophages and lymphocytes. The lesions are largely confined to white matter tracts and resemble those observed in visna.

Arthritic form of CAE is usually seen in adult goats (older than 1 year) and affected animals exhibit progressive lameness, stiffness, reluctance to move, weight loss, poor body condition, and reduced productivity. Carpal joints in particular show swelling/enlargement due to thickening of the synovial membrane, distension of the joint capsule, accumulation of synovial fluid, and hypertrophy of periarticular tissues[61]. Microscopic lesions include chronic proliferative synovitis characterized by synovial cell hyperplasia, villous hypertrophy, fibrosis, and infiltration of lymphocytes, macrophages, and plasma cells[62]. Progressive destruction of joint structures contributes to chronic pain and lameness. Besides arthritis and encephalitis, CAEV affected animals also show lesions in respiratory and mammary gland similar to those observed in MVV. Pulmonary lesions include chronic lymphocytic interstitial pneumonia, whereas mammary lesions are characterized by chronic indurative mastitis[61]. Few reports also indicated that renal tissues are also affected in CAE, showing glomerulonephritis, amyloid deposition, interstitial nephritis, fibrosis, and lymphocytic fibrino-necrotizing arteritis[63].

Diagnosis of SRLVs

Different diagnostic tests (serological, nucleic acid based, protein based) are available for detection of SRLVs for surveillance and control programmes but a single gold test to confirm the disease at early stage is lacking due to absence of overt clinical signs. So, a combination of molecular and serological techniques is usually employed to diagnose the disease at early stage[64] (Fig. 3).

Clinical and pathological diagnosis: Affected animals with characteristics clinical signs and symptoms can be suspected for SRLV infections. Clinical signs and symptoms viz. chronic progressive pneumonia, indurative mastitis, proliferative arthritis, and non-suppurative encephalomyelitis are most common. As the clinical incubation period is very long for these diseases and clinical disease develops only in few infected animals, the clinical findings alone are insufficient for definitive diagnosis. Necropsy and histopathological findings with characteristic gross and microscopic lesions may provide valuable diagnostic information.

Serological tests: The immune response against the SRLVs is non-protective but by detecting the antibodies in the serum, it is possible to diagnose the disease at flock level. Different serological tests viz. AGID, ELISA, Western blotting (WB), radioimmunoprecipitation assay (RIPA), and radioimmunoassay (RIA), etc. are available for the SRLV diagnosis[26,65,66]. AGID was the World Organization of Animal Health (WOAH) for recommended test for routine disease screening at early stage, however, after the development of ELISA assays, AGID is used for confirmatory diagnosis only[67]. Commonly used antigens for the development of the serological assays include envelope glycoprotein gp135, p28 capsid antigen of MVV and p35 capsid antigen of CAEV[66,68]. Serological tests are rapidly used in the SRLV surveillance and control programmes because they are relatively inexpensive, practical, and suitable for large-scale screening of small ruminant populations. Sometimes ELISAs provide unsatisfactory results due difference between the viral antigen in the kit/test, and the antigens expression at different stages of the infection, as antibody response against capsid and matrix protein (p16, p28, p25) prevails during the early stages and antibody responses are mounted against the envelope glycoproteins (gp135 and gp46) at later stage[67,69]. Similarly, difference between the strains circulating

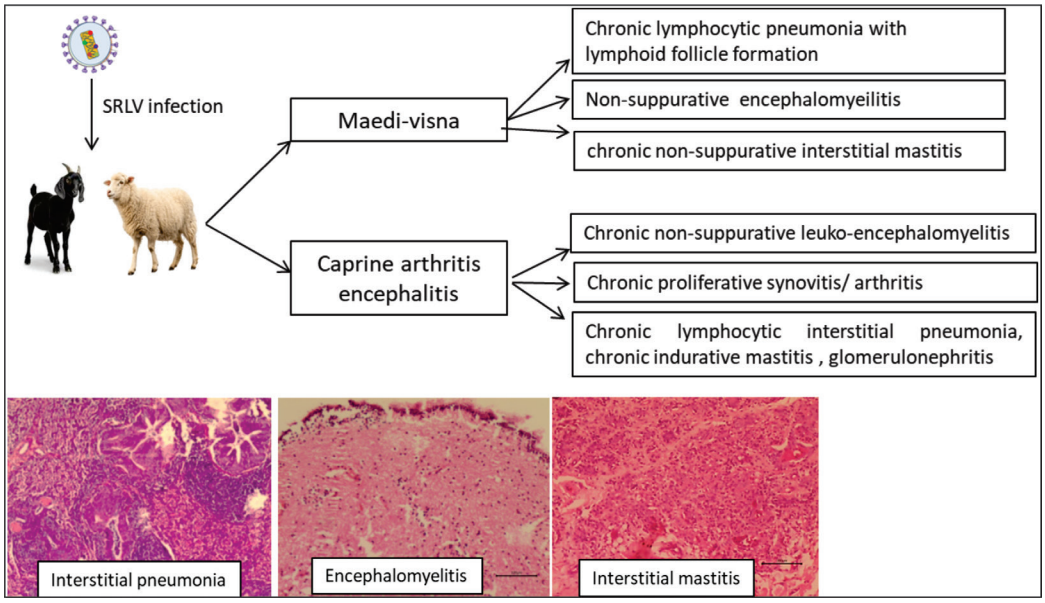

Fig. 2. Pathology of SRLV associated diseases in small ruminants.

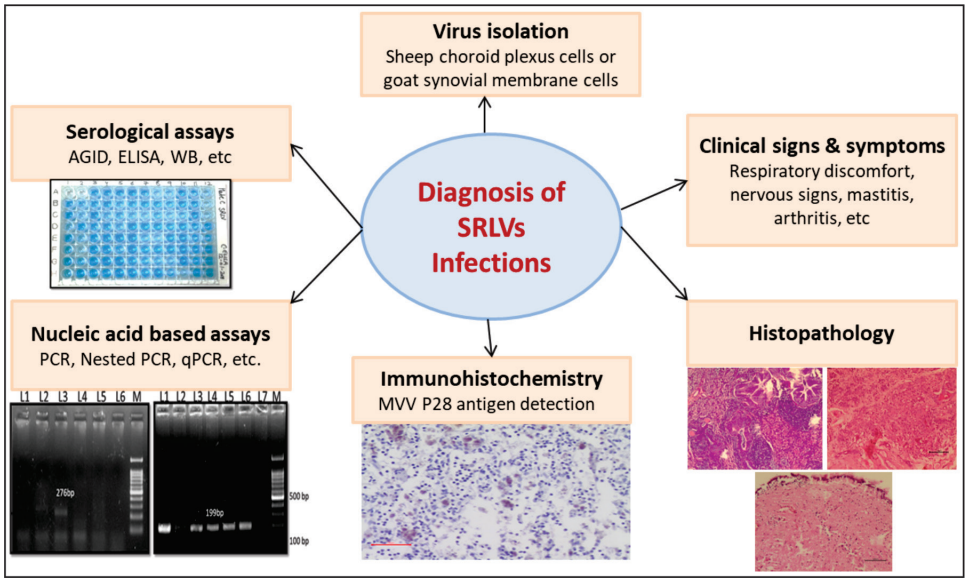

Fig. 3. Diagnostic approaches for the SRLV associated diseases

developed for SRLV diagnosis targeted the *gag* and *pol* genes of MVV and CAEV[72] (Zanoni et al., 1990). Subsequently, numerous assays targeting the *LTR*, *gag*, *pol*, and *env* regions have been described[64]. A major advantage of PCR is its ability to detect infection prior to antibody development. However, diagnostic sensitivity may be compromised by low viral loads, latent infection, and extensive genetic variability among circulating strains. Nested PCR developed for MVV detection showed enhanced sensitivity and specificity, and has been widely applied in epidemiological investigations[73,74]. Real time PCR assays have also been developed to detect low copy numbers of the proviral DNA and it offers improved analytical sensitivity and reduced contamination risk. Despite various advantages of the PCR based assays, detection of the SRLV strains with high mutation is challenging and lead to false-negative results. In addition, the low number of infected circulating cells and uneven distribution of proviral DNA among tissues may reduce diagnostic sensitivity. Combining molecular and serological approaches generally provides the highest diagnostic accuracy. Additionally, techniques such as loop-mediated isothermal amplification (LAMP) and recombinase polymerase amplification lateral flow dipstick (RPA-LFD) have recently been successfully used for CAEV diagnosis[75,76].

IHC: IHC serves as a valuable adjunctive diagnostic tool by enabling the direct demonstration of viral antigens within tissue lesions. Antibodies directed against viral capsid proteins, particularly p28, have been successfully employed to identify infected cells in lungs, mammary glands, lymph nodes, joints, and central nervous system tissues[14,15,58,74]. It is suggested that anti-inflammatory and down regulatory alveolar macrophage retain MVV capsid antigen and may be harbouring a prolonged MVV infection[66]. The technique not only confirms infection but also provides important information regarding viral distribution and lesion pathogenesis.

Virus Isolation: Isolation process of SRLVs in the cell culture is definitive method to demonstrate the virus presence, but it requires presence of living cells in tissue samples. SRLVs may remain in latency, so the development of clear CPE may not always be obtained[77,78]. MVV and CAEV can be isolated by cell culture by using blood leukocytes and milk samples from the seropositive live animal and positive tissues from the necropsied animals (lungs, brain, joint, spleen, udder etc.). For MVV, sheep choroid plexus (SCP) cells can be used for isolation and usually prepared as primary explant cultures from fetal or new-born MVV free lambs. For CAEV, goat synovial membrane (GSM) cell culture can be used. Foetal lamb lung (FLL) and foetal goat lung (FGL) can also be used for the culturing of SRLVs[79] (Oguma *et al.*, 2013). Successful isolation is confirmed through observation of cytopathic effects, detection of reverse transcriptase activity, or positive molecular assays like PCR and FAT[51,79].

CONCLUSION

SRLVs are worldwide in distribution and cause slow progressive diseases in small ruminants with their ability to establish lifelong infections. Unlike many acute viral infections, SRLVs infections have prolonged incubation periods, latent infection, extensive genetic diversity, and persistent viral replication within host macrophages, which makes them difficult to control and at particular region leads to misdiagnosis[26,70]. Milk is reported to impede reliable diagnosis of the SRLVs due to the false positive results and suppressed immune response during lactation[51,71].

Nucleic acid based assays: PCR is widely employed for the detection of proviral DNA in various sample types (blood mononuclear cells, plasma, milk, bronchoalveolar lavage fluid, lungs, brain, mammary gland, synovial tissues, lymph nodes, spleen, liver, kidneys, reproductive tissues, bone marrow) of the SRLV infected animals[64]. The first PCR assays

eradicate from an infected population. So, the success of a control programme can be achieved by employing a multifaceted approach integrating regular surveillance, proper biosecurity measures, restricted flock movement and molecular epidemiological monitoring.

ACKNOWLEDGEMENTS

The authors are thankful to the SERB-DST, Govt. of India and Director, ICAR-Indian Veterinary Research Institute, Izatnagar for providing the necessary facilities for carrying research work on retrovirus associated diseases of small ruminants.

Financial support and sponsorship: No

Conflict of interest: None

Use of artificial intelligence for manuscript preparation: The author confirms that there was no use of AI-assisted technology for assisting in the writing of the manuscript and no images were manipulated using AI.

REFERENCES

1. Palmarini M, Cousens C, Dalziel RG, Bai J, Stedman K. 1996. The exogenous form of Jaagsiekte retrovirus is specifically associated with a contagious lung cancer of sheep. *J Virol* **70:** 1618-1623
2. Pawaiya RVS, Kumar P. 2011. Occurrence of neoplastic diseases in small ruminants in India: an overview. *Indian J Small Ruminants* **17(2):** 151-165.
3. Mishra S, Kumar P, Dar JA, George N, Singh V, Singh R. 2021. Differential immunohistochemical expression of JSRV capsid antigen and tumour biomarkers in classical and atypical OPA: A comparative study. *Biol Rhythm Res* **52(6):** 946-956.
4. Blacklaws BA, Berriatua E, Torsteinsdottir S, Watt NJ, de Andres D, Klein D, Harkiss GD. 2004. Transmission of small ruminant lentiviruses. *Vet Microbiol* **101(3):**199-208..
5. Gomez-Lucia E, Barquero N, Domenech A. 2018. Maedi-visna: current perspectives. *Vet Med* **9:** 11-21.
6. Leroux C, Cruz JCM, Mornex JF. 2010. SRLVs: A genetic continuum of lentiviral species in sheep and goats with cumulative evidence of cross species transmission. *Curr HIV Res* **8:** 94-100.
7. Pisoni G, Bertoni G, Puricelli M, Maccalli M, Moroni P. 2007. Demonstration of coinfection with and recombination by caprine arthritis-encephalitis virus and maedi-visna virus in naturally infected goats. *J Virol* **81:** 4948-4955.
8. Minardi da Cruz JC, Singh DK, Lamara A, Chebloune Y. 2013. Small ruminant lentiviruses (SRLVs) break the species barrier to acquire new host range. *Viruses* **5:** 1867-1884.
9. Olech M, Osinski Z, Kuzmak J. 2020. Seroprevalence of small ruminant lentivirus (SRLV) infection in wild cervids in Poland. *Prev Vet Med* **176:** 104905.
10. Kuhar U, Vengust DZ, Vengust G. 2022. Serological survey of small ruminant lentivirus infections in free-ranging mouflon and chamois in Slovenia. *Animals* **12(8):** 1032.
11. Valecha S, Roopa N, Yadav HS, Singh R, Singh V, Kumar P. 2023. Co-infection of maedi visna virus (MVV) with jaagsiekte sheep retrovirus (JSRV) and mycoplasma in Indian sheep and goats. *Indian J Vet Pathol* **47(1):** 13-17.
12. Rosato G, Abril C, Hilbe M, Seehusen F. 2023. A combined approach for detection of ovine small ruminant retrovirus co-infections. *Viruses* **15(2):** 376.
13. Yadav HS, Neha, Kumar SDV, Singh CP, Jana C, Singh V, Kumar P. 2024. Mixed infection of ovine pulmonary adenocarcinoma and maedi in sheep: A case study. *Indian J Vet Pathol* **48(2):** 196-198.
14. Kumar K, Kumar P, Sindhoora K, Valecha S, Kumar R, Singh V, Singh R. 2022. Detection and immune cell response of natural maedi visna virus (MVV) infection in Indian sheep and goats. *Microb Pathog* **165:** 105467.
15. Valecha S, Yadav HS, Roopa N, Vinaykumar SD, Bhardwaj M, Singh V, Kumar P. 2024. Distribution of maedi-visna virus in different organs of the spontaneously affected small ruminants in India. *Iranian J Vet Res* **25(1):** 41-47.
16. Tiley LS, Brown PH, Le SY, Maizel JV, Clements JE, Cullen BR. 1990. Visna virus encodes a post-transcriptional regulator of viral structural gene expression. *Proc Natl Acad Sci USA* **87(19):** 7497-7501.
17. Toohey KL, Haase AT. 1994. The rev gene of visna virus is required for productive infection. *Virology* **200(1):** 276-280.
18. Harmache A, Russo P, Guiguen F, Vitu C, Vignoni M, Bouyac M, Hieblot C, Pepin M, Vigne R, Suzan M. 1996. Requirement of caprine arthritis encephalitis virus *vif* gene for *in vivo* replication. *Virology* **224(1):** 246-255.
19. Villet S, Bouzar BA, Morin T, Verdier G, Legras C, Chebloune Y. 2003. Maedi-visna virus and caprine arthritis encephalitis virus genomes encode a Vpr-like but no Tat protein. *J Virol* **77(17):** 9632-9638.
20. Haflidadottir BS, Matthiasdottir S, Agnarsdottir G, Torsteinsdottir S, Petursson G, Andresson OS, Andresdottir V. 2008. Mutational analysis of a principal neutralization domain of visna/maedi virus envelope glycoprotein. *J Gen Virol* **89(3):** 716-721.
21. Olech M. 2023. The genetic variability of small-ruminant lentiviruses and its impact on tropism, the development of diagnostic tests and vaccines and the effectiveness of control programmes. *J Vet Res* **67(4):** 479-502.
22. Shah C, Böni J, Huder JB, Vogt HR, Mühlherr J, Zanoni R, Miserez R, Lutz H, Schüpbach J. 2004. Phylogenetic analysis and reclassification of caprine and ovine lentiviruses based on 104 new isolates: evidence for regular sheep-to-goat transmission and worldwide propagation through livestock trade. *Virology* **319(1):** 12-26.
23. Peeters M, Esu-Williams E, Vergne L, Montavon C, Mulanga-Kabeya C, Harry T, Ibironke A, Lesage D, Patrel D, Delaporte E. 2000. Predominance of subtype A and G HIV type 1 in Nigeria, with geographical differences in their distribution. *AIDS Res Hum Retroviruses* **16(4):** 315-325.
24. Gjerset B, Storset AK, Rimstad E. 2006. Genetic diversity of small-ruminant lentiviruses: Characterization of Norwegian isolates of caprine arthritis encephalitis virus. *J Gen Virol* **87(3):** 573-580.
25. Grego E, Bertolotti L, Quasso A, Profiti M, Lacerenza D, Muz D, Rosati S. 2007. Genetic characterization of small ruminant lentivirus in Italian mixed flocks: evidence for a novel genotype circulating in a local goat population. *J Gen Virol* **88:** 3423-3427.
26. Reina R, Grego E, Profiti M, Glaria I, Robino P, Quasso A, Amorena B, Rosati S. 2009. Development of specific diagnostic test for small ruminant lentivirus genotype E. *Vet Microbiol* **138:** 251-257.
27. Giammarioli M, Bazzucchi M, Puggioni G, Brajon G, Dei Giudici S, Taccori F, Feliziani F, De Mia GM. 2011. Phylogenetic analysis of small ruminant lentivirus (SRLV) in Italian flocks reveals the existence of novel genetic subtypes. *Virus Genes* **43:** 380-384.

28. Kuhar U, Barlič-Maganja D, Grom J. 2013. Development and validation of TaqMan probe based real time PCR assays for the specific detection of genotype A and B small ruminant lentivirus strains. *BMC Vet Res* **9(1):** 1-11.
29. Michiels R, Adjadj NR, De Regge N. 2020. Phylogenetic analysis of Belgian small ruminant lentiviruses supports cross species virus transmission and identifies new subtype B5 strains. *Pathogens* **9(3):** 183.
30. Arcangeli C, Torricelli M, Sebastiani C, Lucarelli D, Ciullo M, Passamonti F, Giammarioli M, Biagetti M. 2022. Genetic characterization of small ruminant lentiviruses (SRLVs) circulating in naturally infected sheep in Central Italy. *Viruses* **14(4):** 686.
31. Miguel R, Arrieta M, Rodriguez-Largo A, Echeverria I, Resendiz R, Perez E, Ruiz H, Pérez M, de Andres D, Reina R. 2021. Worldwide prevalence of small ruminant lentiviruses in sheep: A systematic review and meta-analysis. *Animals* **11(3):**784
32. Yang WC, Chen HY, Wang CY, Pan HY, Wu CW, Hsu YH, Su JC, Chan KW. 2017. High prevalence of caprine arthritis encephalitis virus (CAEV) in Taiwan revealed by large-scale serological survey. *J Vet Med Sci* **79(2):** 273-276.
33. Rahman MH, Akther S, Alam MS, Ali MZ, Ahmed S. 2023. Caprine arthritis and encephalitis virus infection in goats of Bangladesh: Serological detection and its associated risk factors. *Vet World* **16(11):** 2256-2263.
34. Rajya BS, Singh CM. 1964. The pathology of pneumonia and associated respiratory disease of sheep and goats. Occurrence of jaagsiekte and maedi in sheep and goats in India. *Am J Vet Res* **25:** 61-71.
35. Singh DK, Paliwal OP, Dubey SC. 1997. Caprine arthritis encephalitis in Indian goats. *Curr Sci* **72:** 702-702
36. Waseem A, Pawaiya RVS, Singh R, Gupta VK, Rajukumar K, Mir MS, Aamir S. 2015. Seroprevalence of caprine arthritis encephalitis virus infection (CAEV) in Indian goats. *Indian J Vet Pathol* **39(1):** 15-19.
37. Didugu H, Sagi S, Reddy CEN, Kishore KN, Reddy MV, Vishnu PG. 2016. First report of Maedi-Visna and Caprine Arthritis-Encephalitis viruses in Krishna district, Andhra Pradesh, *India. J Anim Res* **6(1):** 177-179.
38. Mishra S, Kumar P, Dar JA, George N, Singh R, Singh V, Singh R. 2020. Detection and prevalence of small ruminant lentiviral (SRLV) infections in Indian sheep and goats. *Indian J Vet Path* **44(4):** 207-211.
39. Yadav HS, Neha, Kumar SDV, Singh V, Kumar P. 2024. Detection of maedi visna virus (MVV) in milk samples of Indian goats. *Int J Adv Biochem Res* **SP-8(1):** 143-145.
40. Blacklaws BA, Berriatua E, Torsteinsdottir S, Watt NJ, De Andres D, Klein D, Harkiss GD. 2004. Transmission of small ruminant lentiviruses. *Vet Microbiol* **101(3):** 199-208.
41. Peterhans E, Greenland T, Badiola J, Harkiss G, Bertoni G, Amorena B, Eliaszewicz M, Juste R, Krassnig R, Lafont JP, Lenihan P. 2004. Routes of transmission and consequences of small ruminant lentiviruses (SRLVs) infection and eradication schemes. *Vet Res* **35(3):** 257-274.
42. Araujo JF, Andrioli A, Pinheiro RR, Sider LH, de Sousa ALM, de Azevedo DAA, Peixoto RM, Lima AMC, Damasceno EM, Souza SCR, Teixeira MFDS. 2020. Vertical transmissibility of small ruminant lentivirus. *PLoS One* **15(11):** e0239916.
43. Reina R, Glaria I, Cianca S, Crespo H, de Andres X, Goni C, Lasarte JM, Lujan L, Amorena B, de Andres DF. 2011. Use of small ruminant lentivirus-infected rams for artificial insemination. *Vet J* **189(1):** 106-107.
44. Minguijon E, Gonzalez L, De Las Heras M, Gomez N, Marcia GM, Juste RA, Moreno B. 2013. Pathological and aetiological studies in sheep exhibiting extrathoracic metastasis of ovine pulmonary adenocarcinoma. *J Comp Pathol* **148:** 71-78.
45. Crespo H, Reina R, Glaria I, Ramírez H, de Andrés X, Jáuregui P, Luján L, Martínez-Pomares L, Amorena B, de Andrés DF. 2011. Identification of the ovine mannose receptor and its possible role in Visna/Maedi virus infection. *Vet Res* **42:** 1-10.
46. Gorrell MD, Brandon MR, Sheffer D, Adams RJ, Narayan O. 1992. Ovine lentivirus is macrophagetropic and does not replicate productively in T lymphocytes. *J Virol* **66:** 2679-2688.
47. Ryan S, Tiley L, McConnell I, Blacklaws B. 2000. Infection of dendritic cells by the Maedi-Visna lentivirus. *J Virol* **74(21):** 10096-10103.
48. Crespo H, Bertolotti L, Juganaru M, Glaria I, de Andres D, Amorena B, Rosati S, Reina R. 2013. Small ruminant macrophage polarization may play a pivotal role on lentiviral infection. *Vet Res* **44:** 1-13.
49. Peluso R, Haase A, Stowring L, Edwards M, Ventura P. 1985. A Trojan Horse mechanism for the spread of visna virus in monocytes. *Virology* **147(1):** 231-236.
50. Callado AKC, Castro RSD, Teixeira MFDS. 2001. Small ruminant lentiviruses (CAEV and Maedi-Visna): review and perspectives. *Braz J Vet Res Anim Sci* **21:** 87-97.
51. Barquero N, Gomez-Lucia E, Arjona A, Toural C, Las Heras A, Fernández-Garayzábal JF, Ruiz-Santa Quiteria JA, Doménech A. 2013. Investigation of risk factors associated with infections caused by small ruminant lentiviruses. *J Vet Res* **57(4):** 473-478.
52. Singh R, Kumar P, Singh R, Dhama K, Kumari S, Yadav JP, Kashyap G, Singh KP, Singh V, Sahoo M. 2017. Pathology and polymerase chain reaction detection of ovine progressive pneumonia (maedi) cases in slaughtered sheep in India. *Vet World* **10(11):** 1401-1406.
53. Mishra S, Kumar P, George N, Singh R, Singh V, Singh R. 2018. Survey of lung affections in sheep and goats: a slaughterhouse study. *J Entomol Zool Stud* **6(4):** 118-120.
54. Cecco BS, Henker LC, Lorenzett MP, Molossi FA, Schwertz CI, Baumbach LF, Weber MN, Canal CW, Driemeier D, Pavarini SP, Langohr IM. 2022. An outbreak of visna-maedi in a flock of sheep in Southern Brazil. *Braz J Microbiol* **53(3):** 1723-1730.
55. Benavides J, Fuertes M, Garcia-Pariente C, Ferreras MC, Marín JG, Perez V. 2006. Natural cases of visna in sheep with myelitis as the sole lesion in the central nervous system. *J Comp Pathol* **134:** 219-230.
56. Sigurdsson B, Palsson PA. 1954. Visna of sheep. A slow demyelinating infection. *Brit Exp Path* **39**: 519-528.
57. Lujan L, Garcia Marin JF, Fernandez de Luco D, Vargas A, Badiola JJ. 1991. Pathological changes in the lungs and mammary glands of sheep and their relationship with maedi-visna infection. *Vet Rec* **129(3):** 51-54.
58. Bolea R, Monleón E, Carrasco L, Vargas A, de Andrés D, Amorena B, Badiola JJ, Luján L. 2006. Maedi-visna virus infection of ovine mammary epithelial cells. *Vet Res* **37:** 133-144.
59. Christodoulopoulos G. 2006. Maedi-Visna: Clinical review and short reference on the disease status in Mediterranean countries. *Small Rumin Res* **62:** 47-53.
60. Cork LC, Hadlow WJ, Gorham JR, Piper RC, Crawford TB. 1974. Pathology of viral leukoencephalomyelitis of goats. *Acta Neuropathol* **29:** 281-292.
61. Son GI, Hong EJ, Shin HJ. 2021. Case report: A case of caprine arthritis encephalitis in dairy goat farms in South Korea. *Front Vet Sci* **8:** 773039.
62. von Bodungen U, Lechner F, Pfister H, Vogt HR, Cheevers WP, Bertoni G, Jungi TW, Peterhans E. 1998. Immunohistology of the early course of lentivirus-induced arthritis. *Clin Exp Immunol* **111(2):** 384-390.
63. Murphy BG, Castillo D, Mete A, Vogel H, Goldsmith D, Barro M, Gonzales-Viera O. 2021. Caprine arthritis encephalitis virus is associated with renal lesions. *Viruses* **13:** 1051.

64. Kalogianni AI, Stavropoulos I, Chaintoutis SC, Bossis I, Gelasakis AI. 2021. Serological, molecular and culture-based diagnosis of lentiviral infections in small ruminants. *Viruses* **13(9):** 1711.
65. Ramirez H, Reina R, Amorena B, Andres D, Martinez H. 2013. Small ruminant lentiviruses: genetic variability, tropism and diagnosis. *Viruses* **5(4):** 1175-1207.
66. Herrmann-Hoesing LM. 2010. Diagnostic assays used to control small ruminant lentiviruses. *J Vet Diagn Invest* **22(6):** 843-855.
67. Michiels R, Van Mael E, Quinet C, Adjadj NR, Cay AB, De Regge N. 2018. Comparative analysis of different serological and molecular tests for the detection of small ruminant lentiviruses (SRLVs) in Belgian sheep and goats. *Viruses* **10(12):** 696.
68. de Andres D, Klein D, Watt NJ, Berriatua E, Torsteinsdottir S, Blacklaws BA, Harkiss GD. 2005. Diagnostic tests for small ruminant lentiviruses. *Vet Microbiol* **107:** 49-62.
69. Brinkhof J, Van Maanen C. 2007. Evaluation of five enzyme-linked immunosorbent assays and an agar gel immunodiffusion test for detection of antibodies to small ruminant lentiviruses. *Clin Vaccine Immunol* **14(9):** 1210-1214.
70. Nogarol C, Bertolotti L, Klevar S, Profiti M, Gjerset B, Rosati S. 2019. Serological characterization of small ruminant lentiviruses: A complete tool for serotyping lentivirus infection in goats. *Small Rumin Res* **176:** 42-46.
71. Adjadj NR, Vicca J, Michiels R, De Regge N. 2019. Non-sense of milk testing in small ruminant lentivirus control programs in goats: Comparative analysis of antibody detection and molecular diagnosis in blood and milk. *Viruses* **12(1):** 3.
72. Zanoni R, Pauli U, Peterhans E. 1990. Detection of caprine arthritis encephalitis and maedi-visna viruses using the polymerase chain reaction. *Experientia* **46:** 316-319.
73. Extramiana AB, González L, Cortabarría N, Garcia M, Juste RA. 2002. Evaluation of a PCR technique for the detection of Maedi-Visna proviral DNA in blood, milk and tissue samples of naturally infected sheep. *Small Rumin Res* **44:** 109-118.
74. Preziuso S, Taccini E, Rossi G, Renzoni G, Braca G. 2003. Experimental maedi visna virus infection in sheep: a morphological, immunohistochemical and PCR study after three years of infection. *Eur J Histochem* **47:** 373-378.
75. Huang J, Sun Y, Liu Y, Xiao H, Zhuang S. 2012. Development of a loop-mediated isothermal amplification method for rapid detection of caprine arthritis-encephalitis virus proviral DNA. *Arch Virol* **157:** 1463-1469.
76. Tu PA, Shiu JS, Lee SH, Pang VF, Wang DC, Wang PH. 2017. Development of a recombinase polymerase amplification lateral flow dipstick (RPA-LFD) for the field diagnosis of caprine arthritis-encephalitis virus (CAEV) infection. *J Virol Methods* **243:** 98-104.
77. Johnson GC, Adams DS, McGuire TC. 1983. Pronounced production of polyclonal immunoglobulin G1 in the synovial fluid of goats with caprine arthritis-encephalitis virus infection. *Infect Immun* **41:** 805-815.
78. Pepin M, Vitu C, Russo P, Mornex J, Peterhans E. 1998. Maedi-visna virus infection in sheep: a review. *Vet Res* **29:** 341-367.
79. Oguma K, Tanaka C, Harasawa R, Kimura A, Sasaki J, Goryo M, Sentsui H. 2014. Isolation of maedi/visna virus from a sheep in Japan. *J Vet Med Sci* **76(2):** 211-218.