Indian J. Vet. Pathol., 50(4) : 300-305, 2026: DOI: https://doi.org/10.56093/vjp1xe76

RESEARCH ARTICLE

Histopathological alterations associated with etiological determinants of chronic diarrhoea in adult Dairy Bovines

Nuzhat Hassan[1*], Charanjit Singh Randhawa[1], Kuldeep Gupta[2], Naresh K. Sood[2], Shoor Vir Singh[3], Kundan Chaubey[3] and Ashiq Hussian[1]

Guru Angad Dev Veterinary and Animal Sciences University, Ludhiana-1410 04, Punjab, India

[1]Department of Veterinary Medicine;

[2]Department of Veterinary Pathology;

[3]Department of Microbiology, Central Institute for Research on Goats, India

***Address of correspondence**

Dr Nuzhat Hassan, E-mail: drnuzhatzargar@gmail.com

ORCID ID: 0000-0002-8871-9655, 0000-0002-2946-8585

Received: 2.1.26; Accepted: 18.8.26

ABSTRACT

The study investigated the histopathological markers of various etiologies of chronic diarrhoea in adult dairy cattle and buffaloes, thereby identifying the tissue structural changes and associated cellular abnormalities. Various diagnostic methods, including microscopy and PCR-based molecular techniques, were employed to identify the underlying etiologies associated with histopathological changes. The key finding revealed that chronic diarrhoea in affected bovines is attributed to both non-infectious/infectious factors, as well as dietary complications. Consequent to the specific etiologies, histopathology of intestinal tissue biopsies and postmortem samples revealed mild to chronic enteritis, superficial to chronic inflammation and mucosal shedding. Furthermore, lymph node examination revealed the presence of multinucleated giant cells, lymphoid hyperplasia, chronic inflammation and granulomatous infiltration. The findings underscore the significance of histopathological markers as diagnostic indicators, enabling more precise and targeted management strategies for chronic diarrhoea in dairy animals.

Keywords: Biopsy, Bovines, Chronic diarrhoea, Etiologies, Histopathology

INTRODUCTION

Diarrhoea is the hallmark prodrome of intestinal dysfunction and may or may not be accompanied by additional or secondary clinical symptoms[1]. When diarrhoea persists for over two weeks (>2 weeks), it is categorised as chronic[2]. The clinical manifestation of chronic diarrhoea not only adversely affects the animal's general health but also carries substantial economic consequences[1,3]. These include losses through culling, weight reduction, diminished milk production, increased treatment expenses and an increased risk of transmitting infections to healthy herd mates[4]. The aetiology of chronic diarrhoea can be difficult to identify and requires an expensive diagnostic and therapeutic approach[5]. However, further laboratory testing, particularly histopathological findings, can be explored to enhance diagnostic accuracy.

Recognising the intricate nature of chronic diarrhoea underscores the importance of a comprehensive approach to diagnosis and treatment within the field of animal health[6]. Understanding the diverse factors triggering gastrointestinal dysfunction is crucial. Inflammatory causes, often from infections or irregular physiological processes, significantly affect gut health[7]. Infectious agents like bacteria and parasites play a critical role, particularly in tropical regions, posing challenges to dairy industries due to persistent diarrhoea and diminished body condition among livestock[8]. Despite these challenges, a gap remains in understanding the frequency and distribution of primary and secondary causes of chronic diarrheal diseases in adult cattle and buffalo, particularly in tropical conditions. This study highlights the importance of examining histopathological changes associated with various enteropathies of chronic diarrheal diseases in bovines. The objective is to explore and refine diagnostic protocols, thereby enhancing clinical management strategies for bovines with recurrent or persistent chronic diarrhoea.

How to cite this article: Hassan, N., Randhawa, C.S., Gupta, K., Sood, N.K., Singh, S.V., Chaubey, K. and Hussian, A. 2026. Histopathological alterations associated with etiological determinants of chronic diarrhoea in adult Dairy Bovines. Indian J. Vet. Pathol., 50(4) : 300-305.

MATERIALS AND METHODS

Study population:

The adult dairy cattle and buffaloes (n=101) exhibiting clinical signs of persisting diarrhoea for over a week were selected for the study. These animals were presented to the large animal clinics of the Guru Angad Dev Veterinary and Animal Sciences University (GADVASU), College of Veterinary Science (COVS), in Ludhiana. The study population

include female cross-bred adult dairy bovines (>2 years old) with varying lactation status.

Clinical examination and sampling:

Detailed clinical examinations were performed after a thorough anamnesis of each case. Based on that, a provisional diagnosis was constructed. Appropriate samples (rectal biopsies, ileum and mesenteric lymph node biopsies; necropsy samples) and rectal scrapings were taken from the clinically affected animals, immediately transferred to the clinical diagnostic laboratory and examined for microscopic, molecular and histopathological diagnosis.

Various diagnostic techniques were employed, including parasitic identification techniques for parasite eggs[9], which revealed amphistomes and strongyles in many cases. Diagnosis based on microscopic examination of the cyst morphology predominantly identified *Balantidium coli* cysts[10]. Acid-fast bacilli were identified through Ziehl-Neelsen staining[11]. Molecular diagnosis involved DNA extraction[12] followed by PCR for *Mycobacterium paratuberculosis* using IS900 primers[13] and *Salmonella enterica* subsp. *enterica* detection was confirmed using genus-specific primers[14], as both agents are commonly responsible for chronic diarrhoea in adult animals. Details of these methods have been published[15].

Histopathology:

The rectal biopsies were obtained from a total of forty animals (n=40) using a modified mare uterine biopsy punch. Additionally, postmortem samples (n=40), surgical biopsies of the ileum and mesenteric lymph nodes were performed on adult dairy animals (n=4). The collected intestinal tissue fragments, biopsies and mesenteric lymph nodes were preserved in 10% buffered formalin. After fixation in 10% neutral buffered formalin, the tissue samples were washed overnight with tap water to remove residual fixative. The tissues were embedded in paraffin wax for the subsequent processing steps, utilising Leica Microsystems' Paraplast tissue embedding medium at 56°C. Slices of 4 or 5 microns were cut from the paraffin-embedded tissues. To examine the cellular and tissue structures in detail, the paraffin sections were stained using the standard hematoxylin and eosin method, following the established protocol[16].

The data were analysed using the Statistical Package for the Social Sciences (SPSS), applying one-way analysis of variance (ANOVA) wherever needed. A significance level of $P<0.05$ was set, with results below this threshold considered statistically significant.

RESULTS AND DISCUSSION

The study revealed that affected adult dairy animals (n = 101) experienced recurrent or persistent diarrhoea of varying durations (more than 2 weeks). The investigation identified distinct inflammatory and non-inflammatory etiologies contributing to chronic diarrhoea in affected adult bovines (Fig. 1). Histopathological analysis of rectal biopsy samples from animals with *Balantidium coli*-associated diarrhoea revealed a range of changes, from moderate enteritis to superficial inflammation with mucosal shedding. In some *Balantidium coli*-infected cases, inflammation was accompanied by deep ulceration, presenting a characteristic wedge-shaped pattern (Figs. 2, 3). In animals infected with salmonellosis, distinct histopathological changes in the intestine were observed, including chronic enteritis with plasma cell infiltration, hyperplasia, epithelial sloughing and crypt loss (Figs. 4, 5). Cases of chronic peritonitis exhibited polyp-like projections with widespread chronic enteritis along the intestinal lining, highlighting the distinctive pathological features of this condition (Fig.6). In cases of amphistomiasis, the primary histopathological findings included chronic inflammation, enteritis, granulomatous responses and mucosal hyperplasia, reflecting the diverse pathological effects of amphistome infections (Fig.7).

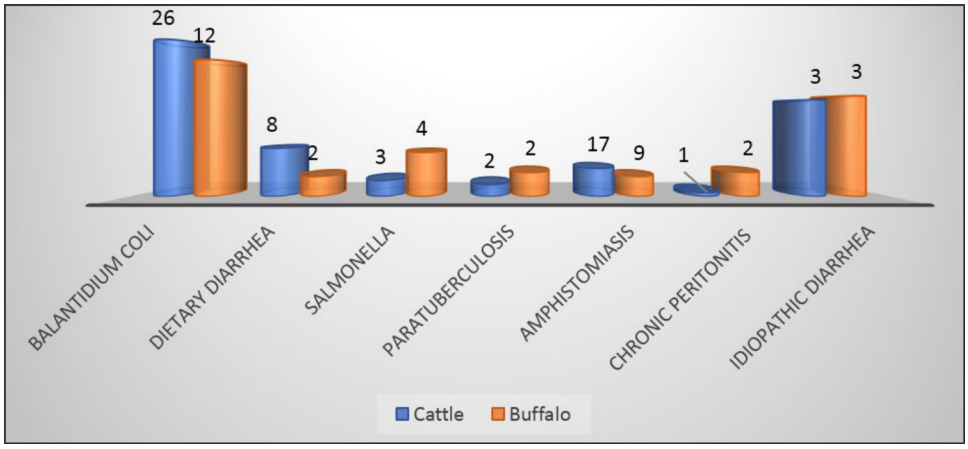

Fig. 1. Identified aetiologies associated with chronic diarrhoea in adult dairy bovines

Rectal biopsies from animals with parasitic or protozoal infections consistently showed goblet cell hyperplasia accompanied by localised inflammation (Figs. 8,9). In contrast, animals with clinical paratuberculosis (Johne's disease) exhibited enteritis, mononuclear cell infiltration and significant granulomatous reactions, highlighting the severity and complexity of the disease. Idiopathic lesions exhibited

chronic enteritis with pronounced infiltration between crypts and inflammation extending beneath the lamina muscularis (Fig. 10). Lymph node lesions in paratuberculosis cases showed characteristic features, including giant cells with lymphoid hyperplasia, marked inflammation, granulomatous infiltration and early-stage cellular hyperplasia (Figs. 11-13). Acid-fast bacilli were detected within large cells and macrophages, confirming mycobacterial infection (Figs. 14, 15).

The findings highlighted the significant histopathological changes in animals with chronic diarrhoea. However, in large animals, comprehensive studies on the underlying causes and associated pathophysiological features of chronic diarrhoea remain limited[3,15]. Our study identified multiple etiologies[16], with *Balantidium coli* infection notably prevalent, confirming its common role in causing chronic diarrhoea in adult bovines in this region[17,18]. Additionally, large amounts of rumen-degradable protein have been implicated in the development of diarrhoea[19,20]. Salmonella infection was confirmed as a bacterial cause of diarrhoea in buffalo and dairy cattle across all age groups[21,22]. Chronic diarrhoea due to amphistomiasis was previously overlooked but has recently been recognised as a significant cause of productivity loss[23]. Bovine paratuberculosis typically presents with intermittent diarrhoea and chronic weight loss[24], while peritonitis has been shown to cause persistent diarrhoea and weight loss in cattle and buffalo[25].

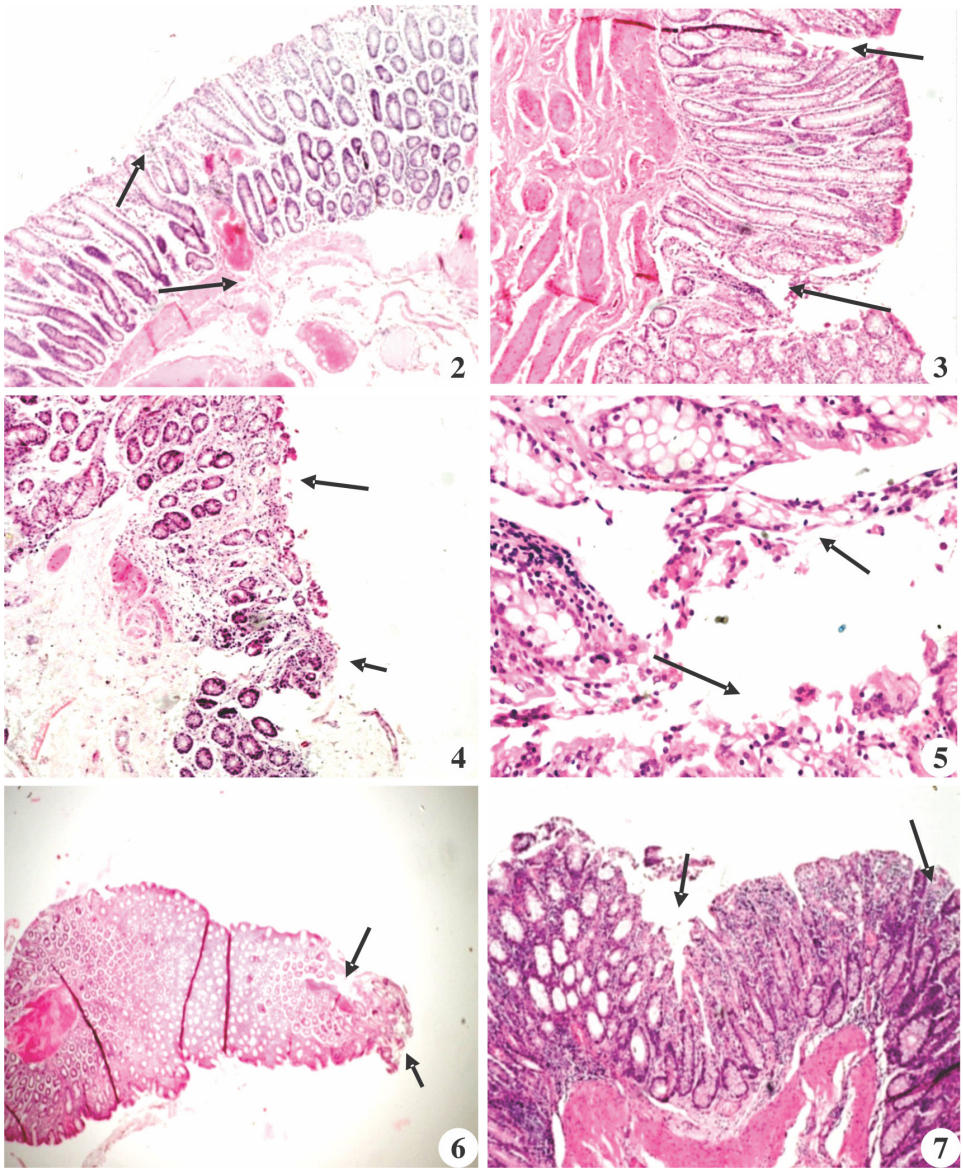

Fig. 2. Section of rectal biopsy shows mild enteritis changes (arrow), H&Ex20X; **Fig. 3.** Section of intestine shows chronic enteritis with marked mucosal hyperplasia, crypt elongation and inflammatory cell infiltration of the lamina propria (arrow), H&Ex40X; **Fig. 4.** Rectal biopsy section shows sloughing of epithelium (arrow), H&Ex10X; **Fig. 5.** Section of intestine shows inflammation associated with deep ulcer and deep wedge H&Ex100X; **Fig. 6.** Section of intestine shows chronic enteritis with mucosal thickening, prominent goblet cell hyperplasia and inflammatory cell infiltration of the lamina propria, H&Ex20X; **Fig. 7.** Section of ileum shows chronic enteritis with mucosal hyperplasia, crypt distortion, epithelial sloughing and dense inflammatory cell infiltration of the lamina propria (arrows), H&Ex20X

Consistent with these observations, our study identified significant histopathological changes in animals affected by chronic diarrhoea. In a concurrent study, animals with diarrhoea associated with amphistomiasis (a parasitic disease of domestic ruminants caused by trematodes) exhibited mucosal hyperplasia and progressive inflammatory cell infiltration in affected intestinal regions, indicating mild, moderate and severe degrees of intestinal damage[26]. Several studies have reported that *Balantidium coli* infections are associated with inflammation, intestinal haemorrhage, and necrosis, attributed to the production of proteolytic enzymes by the parasite[27,28]. Salmonella organisms

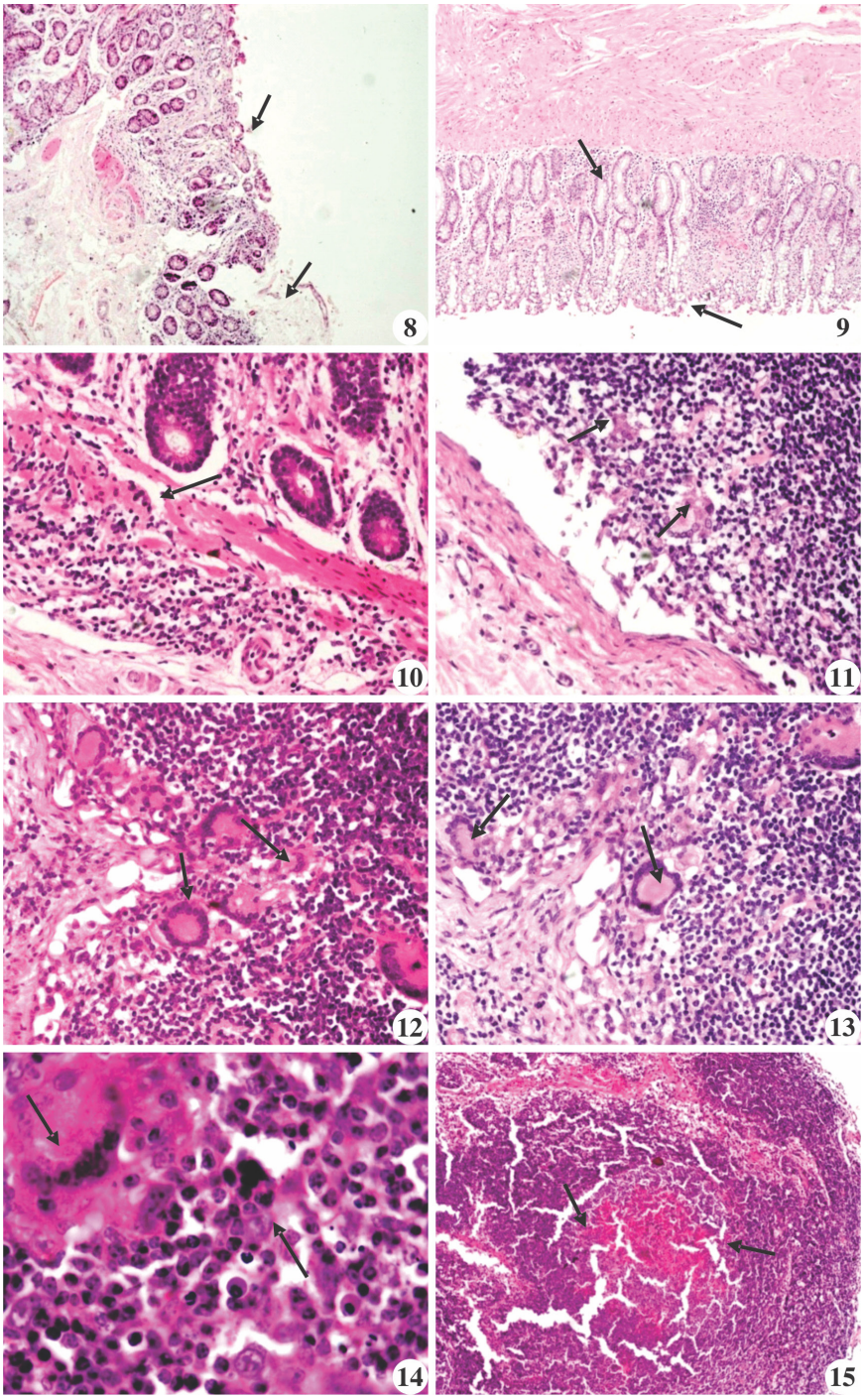

Fig. 8. Section of rectal biopsy shows severe inflammatory changes with the destruction of crypts (arrows) H&Ex10X; **Fig. 9.** Section of rectal biopsy shows chronic inflammatory changes with plasma cells infiltration (arrow), H&Ex10X; **Fig. 10.** Section of ileum shows inflammation below lamina muscularis (black arrow), H&Ex40X; **Fig. 11.** Mesenteric lymph nodes section shows giant cells infiltration (arrow), H&Ex100X; **Fig. 12.** Section of Ileocecal lymph node shows giant cells and hyperplasia (arrow), H&Ex40X; **Fig. 13.** Mesenteric lymph node section shows granulomatous inflammation with dense mononuclear cell infiltration with multinucleated giant cells, suggestive of paratuberculous involvement (arrow), H&Ex40X The section; **Fig. 14.** Section of lymph node shows macrophages and epithelioid cells with foamy plasm (arrow), H&Ex100X; **Fig. 15.** Section of lymph node shows reactive hyperplasia with haemorrhage (arrow) with no primary follicles, H&Ex10X

proliferate and invade the intestinal lamina propria, resulting in fibrin exudation and increased infiltration of macrophages and lymphocytes[29], a pathological pattern consistent with clinical cases of salmonellosis observed in farm settings[30]. Paratuberculosis cases demonstrate histopathological alterations in the submucosal glands, characterised by diffuse inflammatory responses, mononuclear cell infiltration, and degenerative or necrotic changes[31]. Animals affected by Johne's disease exhibit intestinal wall thickening and corrugation, along with enlargement of mesenteric lymph nodes, resulting from extensive mononuclear cell infiltration[32,33]. In a study consistent with our findings, early histological lesions of Johne's disease, including multinucleated Langhans-type giant cells in lymph node sinuses and at the tips of intestinal villi, were observed. These features are considered valuable indicators for disease surveillance in control programs[34]. Histopathological examination of mesenteric lymph nodes is a valuable diagnostic tool for identifying moderate subclinical infections in ruminants from herds with uncertain infection status. Additionally, idiopathic cases showed an increased crypt-to-interstitium ratio, highlighting the complexity and multifactorial nature of these diagnostic challenges[32]. Due to a limited understanding of the causes and mechanisms of chronic diarrhoea, a definitive diagnosis is achieved in only 60-70% of cases, often requiring postmortem histopathological evaluation. The observed severity of clinical symptoms aligns closely with the histologic lesions identified in this investigation, supporting the importance of histopathological examinations in elucidating the underlying aetiology of diarrhoea in these animals.

CONCLUSION

Integrating histopathological findings with other diagnostic methods

may provide a deeper understanding of the causes of chronic enteritis in affected dairy animals. The findings emphasise the importance of a thorough diagnostic approach addressing immediate signs and predisposing etiologies in affected animals with chronic diarrhoea, aiming to reduce severe economic losses associated with this condition.

ACKNOWLEDGEMENT

The authors sincerely acknowledge the Department of Science and Technology (DST) for supporting this research program. We also acknowledge the cooperation and technical support of the Departments of Veterinary Medicine, Microbiology and Pathology at GADVASU, Ludhiana.

Conflict of interest : None

Financial sponsorship: None

Use of artificial intelligence (AI)-assisted technology for manuscript preparation: The authors confirm that there was no use of AI-assisted technology for assisting in the writing of the manuscript and no images were manipulated using AI.

REFERENCES

1. Du W, Wang X, Xu L, Zhou X, Song D and Xu Q. 2023. Editorial: Research Du W, Wang X, Xu L, Zhou X, Song D and Xu Q. 2023. Editorial: Research advances in intestinal diseases and related diarrhoea in animal production. Front. *Vet. Sci* **10**:1201231.
2. Radostits OM, Gay CC, Hinchcliff KW, Constable PD. 2010. Veterinary Medicine. A Textbook of the Diseases of Cattle, Horses, Sheep, Pigs, and Goats, 10th edn. Saunders Elsevier, Philadelphia, pp. 337–342, 349.
3. Osterstock JB, Mansell JL, Roussel AJ.2005. Protothecal enteritis as a cause of protein-losing enteropathy in a bull. *J Am Vet Med Assoc* **227**:1476–1479. doi: 10.2460/javma.2005.227.1476.
4. Raizman EA, Fetrow J, Wells SJ, Godden SM, Oakes MJ, Vazquez J. 2007. The association between *Mycobacterium avium* subsp. paratuberculosis fecal shedding or clinical Johne's disease and lactation performance on two Minnesota, USA dairy farms. *Prev Vet Med* **78**: 179-195 DOI: 10.1016/j prevetmed.2006.10.006.
5. Hassan N, Randhawa CS, Narang D, Singh SV, Sharma S, Singh. S. 2019. Bio-incidence and Bio-type of Mycobacterium avium subspecies paratuberculosis in diarrheic dairy cattle and buffaloes of Punjab area in India. *Indian J Anim Res* DOI: 10.18805/ijar. B-3694.
6. Hassan N, Randhawa CS, Randhawa SS, Narang D. 2018. Chronic diarrhoea due to lymphosarcoma in an adult cow: A sporadic clinical report. *Turkish J Vet Anim Sci* **42**: 669–671DOI: 10.3906/vet-1804-71.
7. Jiminez JA, Uwiera TC, Douglas Inglis G, Uwiera RR. 2015. Animal models to study acute and chronic intestinal inflammation in mammals. *Gut Pathogens* **7**: 29 DOI: 10.1186/s13099-015-0076-y.
8. Peek SF, Mcguirk SM, Sweeney RW, Cummings KJ. 2018. Infectious diseases of the gastrointestinal tract. Rebhun's Diseases of Dairy Cattle, 249–356.
9. Paras KL, George MM, Vidyashankar AN, Kaplan RM. 2018. Comparison of fecal egg counting methods in four livestock species. *Vet Parasitology* **257**:21–27. DOI: 10.1016/j.vetpar.2018.05.015.
10. Samad MA. Balantidiasis. Pashu palon O Chikitsavidya. 1996. (Animal Husbandry and Medicine). Lyric- Epic Prokasoni. Mymensingh, Bangladesh, pp. 765–767.
11. Van Deun A, Hossain M, Gumusboga M, Rieder HL. 2008. Ziehl-Neelsen staining: Theory and practice. *International J Tuberculosis Lung Dis* **12**: 108–110.
12. Van Embden JDA, Cave D, Crawford JT, Dale JW, Eisenach KD, Gicquel B, Hermans P, Martin C, McAdam R, Shinnick TM, Small PM. 1993. Strain Identification of Mycobacterium tuberculosis by DNA Fingerprinting: Recommendations for a Standardised Methodology. *J Clin Microbiol* **31***:* 406.
13. Millar D, Ford J, Sanderson J, Withey S, Tizard M, Doran T, Hermon-Taylor J. 1995. IS900 PCR to detect *Mycobacterium paratuberculosis* in retail supplies of whole pasteurized cow's milk in England and Wales. *Appl Environ Microbiology*, **62**:3446–3452.
14. Cohen ND, Neibergs HL, Mcgruder ED, Whitford HW, Behle RW, Ray PM, Hargis BM. 1993. Genus-specific detection of salmonellae using the polymerase chain reaction (PCR). *J Vet Diagn Investig* **5:** 368–371 DOI: 10.1177/104063879300500311.
15. Hassan, N., Randhawa, C.S. and Zargar, U.R. 2022. Evaluating the hemato-biochemical indices in relation to the different etiologies of chronic diarrhoea in dairy cattle and buffalo. *Comp Clin Pathol* **31**; 585–595. https://doi.org/10.1007/s00580-022-03357-x.
16. Bancroft JD, Stevens A. 1990. Theory and Practice of Histological Techniques. Churchill Livingstone: Edinburgh, pp. 21–119.
17. Randhawa SNS, Singla LD, Randhawa CS. 2010. Chronic cattle diarrhoea due to *Balantidium coli* infection: a clinical report. *J Vet Parasitology* **24**: 197–198.
18. Hassan N, Randhawa C, Randhawa S, Narang D. 2017. Chronic diarrhoea and therapeutic trial with metronidazole in *Balantidium coli-infected* cattle and buffaloes. *International J Livestock Res* **7:**74–81 DOI: 10.5455/ijlr.20170423031718.
19. Davidson S, Hopkins BA, Diaz DE, Bolt SM, Brownie C, Fellner V, Whitlow LW. 2003. Effects of amounts and degradability of dietary protein on lactation, nitrogen utilisation, and excretion in early lactation Holstein cows. *J Dairy Sci* **86**: 1681–1689 DOI: 10.3168/jds. S0022-0302(03)73754–0.
20. Radostits OM, Blood DC,Gay CC. 2007. Doenças Causadas por Bacterias IV, Rio de Janeiro, cap. In: Guanabara K (ed) *Clínica Vet*, IV.19 (597–622).
21. Warnick LD, Kanistanon K, McDonough P, Power L. 2003. Effect of previous antimicrobial treatment on fecal shedding of *Salmonella enterica* subsp. *enterica* serogroup B in New York dairy herds with recent clinical salmonellosis. *Prev Vet Med* **56**: 285–297 DOI: 10.1016/s0167-5877(02)00210-6.
22. Wray C, Davies R. 2004. Salmonella in cattle: Update. *Cattle Practitioner* **12**:313–316.
23. Anuracpreeda P, Wanichanon C, Sobhon P. 2008. *Paramphistomum cervi* antigenic profile adults as recognised by infected cattle sera. *Exp Parasitology* **118**: 203–207 DOI: 10.1016/j.exppara.2007.08.005.
24. Abdullah FFJ, Adamu L, Yin YJ, Osman AY, Haron AW, Saharee A. 2013. Suspected Johne's disease in a herd of dairy cattle: A case report. *IOSR J Agri Vet Sci* **4**: 58–62 DOI: 10.9790/2380-0415862.
25. Tharwat M, Ahmed AF, El-Tookhy OS. 2012. Chronic peritonitis in buffaloes and cattle: Clinical, haematological, ultrasonographic findings and treatment. *J Anim Vet Adv* **11**: 2775–2781 DOI: 10.3923/javaa.2012.2775.2781.

26. Tehrani A, Javanbakht J, Khani F, Hassan MA, Khadivar F, Dadashi F, Alimohammadi S, Amani A. 2015. Prevalence and pathological study of paramphistomum infection in the small intestine of slaughtered ovine. *J Parasitic Dis* **39**: 100–106 DOI: 10.1007/s12639-013-0287-4.
27. Anargyrou K, Petrikkos G, Suller MTE, Skiada A, Siakantaris MP, Osuntoyinbo RT, Pangalis G, Vaiopoulos G. Pulmonary. 2003. B. coli infection in a leukemic patient. *American J Haemat* **73**: 180–183 DOI: 10.1002/ajh.10336.
28. Paul TR, Begum N, Shahiduzzaman M, Hossain MS, Labony SS, Anisuzzaman A, Dey AR. 2019. Balantidiasis, a zoonotic protozoan infection, in cattle and domestic pigs. *Bangladesh J Vet Med* **1** DOI: 10.33109/bjvmjj19fam1.
29. Frizzo LS, Zbrun MV, Soto LP, Bertozzi E, Sequeira GJ, Marti LE, Signorini ML, Armesto RR, Rosmini MR. 2012. Pathogen translocation and histopathological lesions in an experimental model of Salmonella Dublin infection in calves receiving lactic acid bacteria and lactose supplements. *J Vet Sci* **13**: 261–270DOI: 10.4142/jvs.2012.13.3.261.
30. Gelberg HB. 2001. Alimentary system. In: Thomson's Special Veterinary Pathology, 3rd edn (edited by M. D. McGavin, W. W. Carlton & J. F. Zachary). Mosby: St Louis, USA, pp. 1–79.
31. Chaturvedi S, Singh SV, Srivastava AK, Gangwar NK, Kumar N, Rawat KD, Gupta S, Chaubey KK, Singh R, Singh R, Dhama K.2017. Comparative evaluation of FAT, IS900 PCR and microscopy vis-a-vis histopathology for detection of *Mycobacterium avium* subsp. *paratuberculosis* infection in tissues of goats naturally died in herds endemic for Johne's disease. *Indian J Anim Sci* **87**: 685–693DOI: 10.56093/ijans.v 87i6.71061.
32. Maxie MG, Jubb KVF, Kennedy PC, Palmer NC. 2007. Pathology of Domestic Animals, 5th edn, Vol. 2. Saunders Elsevier: London, pp. 222–225.
33. Koets AP, Eda S, Sreevatsan S. 2015. The within-host dynamics of Mycobacterium avium ssp. Paratuberculosis infection in cattle: Where time and place matter. *Vet Res* **46**: 61 DOI: 10.1186/s13567-015-0185-0.
34. Sikandar A, Cheema AH, Adil M, Younus M, Zaneb H, Zaman MA, Tipu MY, Masood S. 2013.Ovine paratuberculosis: A histopathological study from Pakistan. *Journal of Animal and Plant Sciences* **23**: 749–753.hological study from Pakistan. *J Anim Plant Sci* **23**: 749–753.