Indian J. Vet. Pathol., 50(4) : 311-315, 2026: DOI: https://doi.org/10.56093/rvnqmx07

RESEARCH ARTICLE

Pathomorphological and histopathological characterization of hydatid cysts in sheep: Evidence from slaughterhouses in Rayalaseema, Andhra Pradesh

P. Lakshmisai*, K. Jalajakshi, R. Venu and A. Anand Kumar[1]
Department of Veterinary Parasitology, College of Veterinary Science, Sri Venkateswara Veterinary University, Tirupati
[1]Professor & Head, Department of Veterinary Pathology

***Address for correpondence**
Dr. P. Lakshmisai, MVSc Scholar, E-mail: lakshmisaipalluru@gmail.com
ORCID ID: 0009-0001-3859-652X

Received: 13.4.26; Accepted: 13.5.26

ABSTRACT

Hydatidosis is primarily caused by the metacestode stages of *Echinococcus granulosus* also known as cystic echinococcosis (CE), which causes a significant zoonotic parasitic disease. The disease is considered one of the most significant helminthic infections of livestock and humans worldwide and poses major veterinary, public health, and economic concerns. A slaughterhouse study was conducted to determine the histopathological changes in liver and lungs of the sheep infected with hydatid disease across various districts of the Rayalaseema region of Andhra Pradesh, India for a period of 9 months from July 2025 to March 2026. All the infected liver and lungs were processed further for histopathological examination using haematoxylin and eosin (H&E) and iodine staining techniques. To record the pathomorphological changes in organs affected by hydatidosis in slaughtered sheep. Out of 3,683 sheep examined during slaughter, 87 (2.36%) sheep were found to be infected with hydatid cysts. Microscopic examination of cystic fluid revealed the presence of protoscoleces with rostellum, and hook lets in the hydatid sand. Out of 87 collected cyst samples (41 livers and 46 lungs) 39 samples found to be fertile due to the presence of protoscoleces, 28 cysts were found sterile because of absence of protoscoleces and remaining 20 cysts were found to be calcified because of its hard consistency. The study concludes that histopathological examination demonstrated significant and consistent tissue reaction in both lungs and liver, characterized by a trilaminar cyst wall, pericystic fibrosis, inflammatory cell infiltration, hepatocellular degeneration, pulmonary alveolar compression with granuloma formation.

Keywords: Brood capsules, Histopathological changes, Hydatid cysts, Lungs, Liver, Microscopy, Protoscoleces, Slaughtered sheep

INTRODUCTION

Hydatidosis/Cystic echinococcosis (CE) is a meat-borne cyclo-zoonotic disease caused by the larval stage of Echinococcus spp., the smallest dog tapeworm of the family *Taeniidae*, with sheep serving as important intermediate hosts[1,2]. The disease poses major public health and economic concerns due to zoonotic transmission and organ condemnation at slaughter[3]. CE is endemic in regions where livestock rearing and close animal contact are common, and its spread is further influenced by migration of humans and animals[4]. In sheep, the liver and lungs are the most affected organs because larvae reach these organs through the hepatopulmonary circulation[5,6]. Although hydatidosis is prevalent in many parts of India, information on its histopathological changes in sheep from southern regions, particularly Rayalaseema of Andhra Pradesh, is limited. Therefore, the present study was undertaken to investigate the histopathological alterations in the liver and lungs affected by hydatidosis.

How to cite this article: Lakshmisai, P., Jalajakshi, K., Venu, R. and Kumar A.A. 2026. Pathomorphological and histopathological characterization of hydatid cysts in sheep: Evidence from slaughterhouses in Rayalaseema, Andhra Pradesh. Indian J. Vet. Pathol., 50(4) : 311-315.

MATERIALS AND METHODS

Samples collection

A total of 3,683 slaughtered sheep including both males and females were systematically examined during routine post-mortem meat inspection for the presence/absence of hydatid cysts from various abattoirs present in the Rayalaseema region which included Anantapur, Sri Satya Sai, Chittoor, Tirupati, YSR Kadapa, Annamayya, Kurnool and Nandhyal districts. Data collected was analysed for the organ-wise prevalence of cysts.

Gross examination

The livers and lungs specimens affected with hydatidosis were grossly examined for any alterations resulted due to the infection.

Microscopic examination of hydatid cyst fluid

The hydatid cystic fluid was aspirated using 18G needle and a drop of fluid was placed on a

glass slide for the detection of protoscoleces. The viability of cysts were assessed microscopically using 0.1% eosin and 1% iodine stains.

Processing of tissues for histopathology

Tissue samples of hydatid cysts were gathered and preserved in 10% neutral formal saline. Using a standard paraffin embedding procedure, the fixed tissues were cut into 3-5mm thickness and washed thoroughly under water over night prior to dehydration with ascending grades of alcohol, followed by clearing with xylene. The blocks were sectioned 4-5 µm thickness using microtome and stained with routine haematoxylin and eosin (H&E) stain[9]. The DPX mounted slides were examined for lesions and captured using light microscope.

RESULTS

In this period of study, out of 3,683 slaughtered sheep examined 87 sheep were found to be infected with hydatid cysts among all the districts. Of which 41 livers cysts (1.11%) and 46 lung cysts (1.25%) were identified. Among all districts, Tirupati exhibited the highest prevalence of hydatidosis with 1.85% prevalence of hepatic involvement and 2.35% prevalence of pulmonary tissue involvement showing a comparatively higher burden of infection in this region. Whereas, in Nandyal district showed the lowest liver infection 0.31%, while lung infection was relatively higher 1.23% suggesting organ-specific variation. The organ wise prevalence of hydatidosis infection during this study was shown in Table 1 and Fig 1.

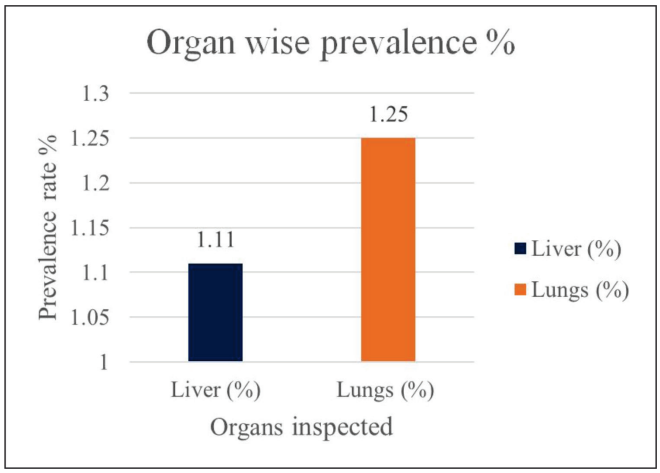

Fig. 1. Graph showing the organ wise prevalence of hydatidosis in the Rayalaseema region

Table 1. Organ wise prevalence of hydatidosis in sheep of Rayalaseema region of Andhra Pradesh.

District	No. examined	Liver, n (%)	Lungs, n (%)
Anantapur	563	4 (0.71)	7 (1.24)
Sri Sathya Sai	424	2 (0.47)	3 (0.70)
Chittoor	392	5 (1.27)	6 (1.53)
Tirupati	595	11 (1.85)	14 (2.35)
YSR Kadapa	546	9 (1.64)	4 (0.73)
Annamayya	412	4 (0.97)	5 (1.21)
Kurnool	427	5 (1.17)	3 (0.70)
Nandyal	324	1 (0.31)	4 (1.23)
Total	3683	41 (1.11)	46 (1.25)

Gross examination of organs

On gross examination, affected organs revealed single to multiple hydatid cysts ranged from small to larger sized cysts 2-6 cms containing white fluid filled cavities, fully or partially embedded inside the liver and lungs (Fig. 2 and Fig. 3). These cysts were soft to touch on palpation, and some were calcified and hard to cut. The hepatic regions surrounding the cyst showed clearly marked diffuse pale-coloured areas of necrosis with some dark congested regions showing petechial haemorrhages and hepatomegaly. The pulmonary regions infected with CE showed marked congestion with large sized cysts than the liver.

Microscopic examination

Microscopic examination of cystic fluid derived the flame cell activity of the protoscoleces in clusters and brood capsules with protoscoleces (Fig. 4). Viability evaluation was done on staining with 0.1% eosin stain and results revealed that live ones were unstained whereas, the dead ones had taken up the stain and marked in pink colour (Fig. 5). The iodine-stained sections showed with clear refractile nature of the protoscoleces (Fig. 6).

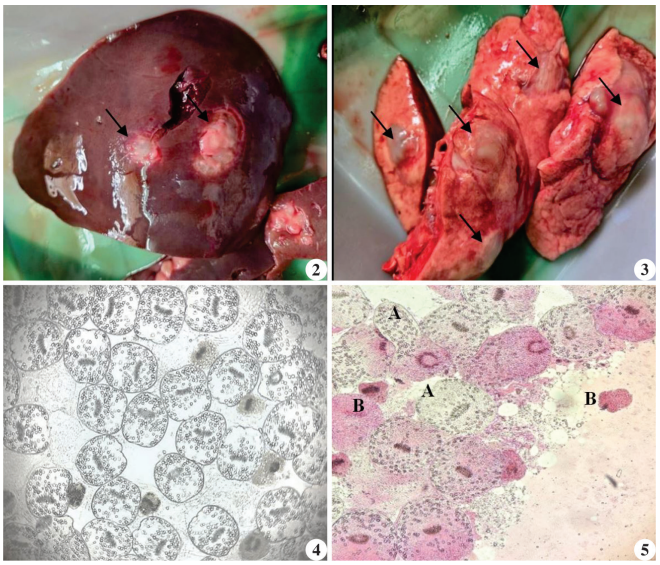

Fig. 2. Liver showing hydatid cysts (arrows) with pathological lesions; **Fig. 3.** Lung sections with multiple cysts (arrows); **Fig. 4.** Depicting clusters of protoscoleces (100X); **Fig. 5.** Eosin stain test for the protoscoleces viability A. Note unstained live protoscolices. B. Note pink stained dead protoscoleces (100X)

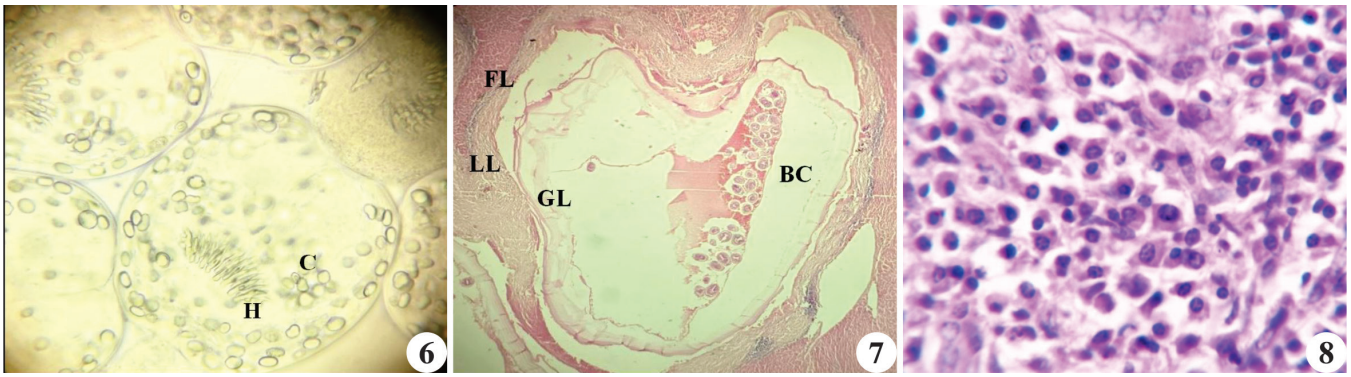

Fig. 6. Iodine stained mature invaginated protoscoleces with hooklets (H) and calcareous bodies (C) (400X); **Fig. 7.** Liver sections showing three layers of the cyst (Germinal layer [GL], acellular laminated membrane [AL] and fibrous layer [FL], Broode capsule [BC]wall with infiltration of inflammatory cells (H&E, 40X); **Fig. 8.** Liver section showing multifocal microscopic infiltration of lymphoplasmacytic inflammatory reaction (H&E, 1000X).

Histopathological sections

The resulted histopathological sections from the liver, showed a clear demarcation of three layers of the cyst with inner germinal layer/endocyst with attached protoscoleces and brood capsules, middle acellular laminated membrane/exocyst and outer fibrous layer/pericyst (Fig. 7). The pericyst provides protection to the cyst and the other two layers supplement nutrition to the hydatid cyst. A zone of inflammatory reaction observed with infiltration of monocytes, lymphocytes, plasma cells with moderate to dense fibrous tissue formation (Fig. 8). Necrosis (chronic venous congestion) was observed in the tissues present adjacent to the hydatid cyst (Fig. 9). Some of the liver microscopic sections revealed calcified tissue adjacent to the cyst wall (Fig. 10).

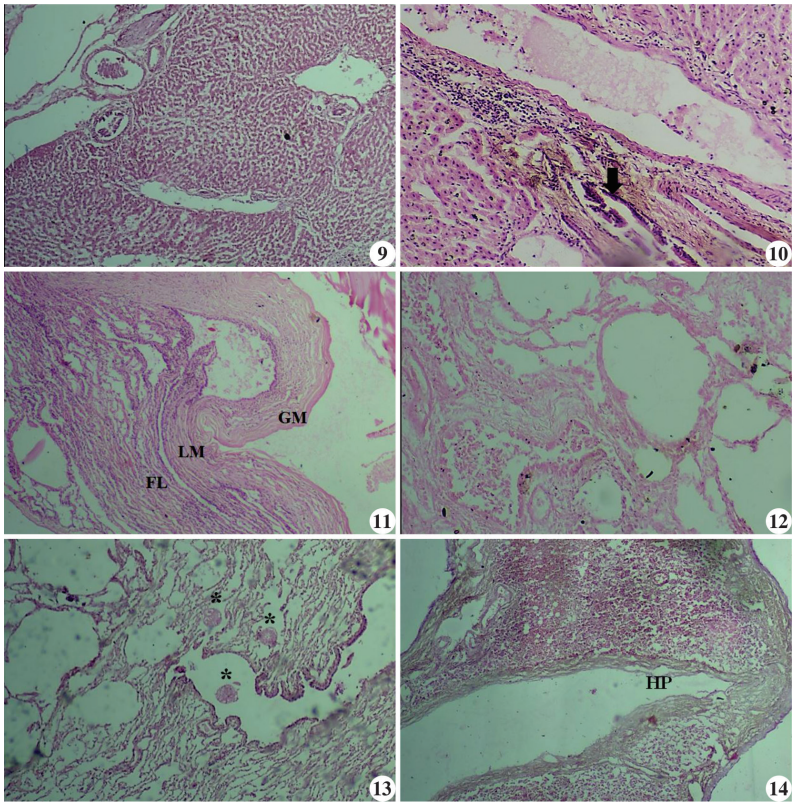

Fig. 9. Liver section showing congestion and necrosis of tissue adjacent to the cyst formation (H&E, 100X); **Fig. 10.** Liver section showing infiltration of inflammatory cells and calcification (arrow) surrounding the cyst wall development (H&E, 100X); **Fig. 11.** Lung section showing three layers of the hydatid cyst; germinal layer (GM), laminated membrane (LM) and fibrous layer (FM) (H&E, 40X); **Fig.12.** Lung section showing atelectasis, congestion due to the cyst development in the alveoli (H&E, 100X); **Fig. 13.** Lung section with migrating protoscoleces (*) with inflammatory cells surrounding (H&E, 40X); **Fig. 14.** Lung section showing hemosiderin pigment deposition (HP) surrounding the cyst wall (H&E, 40X)

Lung sections showed similar structure as of liver with trilaminar layers of the cyst (Fig. 11). In addition to this, lungs showed collapsed alveolar tissues with congestion of blood vessels due to the pressure created during the cyst development (Fig. 12). In some lung sections free migrating protoscoleces were observed with inflammatory cells infiltration around the surrounding tissue with multifocal microscopic lympho-plasmocytic infiltration (Fig. 13). Other lung sections showed deposition of hemosiderin pigment all over the cyst wall (Fig. 14).

DISCUSSION

Cystic echinococcosis is recorded as one of the neglected tropical diseases reported by WHO, 2021[10]. Of the 3,683 slaughtered sheep examined, 87 (2.36%) sheep of which 41 livers (1.11%) 46 lungs (1.25%) were found infected with hydatid cysts, across various districts of Rayalaseema region of Andhra Pradesh**.** Since liver and lungs were the first organs to receive the circulating blood during which protoscoleces enters these organs and development of cyst takes place[6,11].

Higher prevalence of CE was recorded in the lungs compared to liver in sheep could be associated with the immune competence of the host and rigid consistency of the organ (liver) resist the cyst development to larger sizes[13]. In contrast the pulmonary tissue contains greater capillary bed and the consistency of the organ makes the cysts to wider distribution, gives more space to develop[11]. The results indicated that there was no significant difference among districts and the organ-wise prevalence of hydatidosis. Indicating that hydatid cysts were uniformly distributed across all the districts[12,13]. Grossly, hydatid cysts in liver ranged from single to multiple cysts of varying sizes on visceral surfaces. Most of the cysts were smaller in size and some were large cricket ball sized. Some cysts were partially embedded protruding from the liver parenchyma and others were fully embedded with only a part of visible cyst wall. These observations on distribution of cysts were similar with the research findings of above authors[8,12]. Gross examination of the infected lungs revealed variable-sized, greyish white, unilocular to multilocular fluid-filled cysts embedded within the lung parenchyma ranging from small nodules to large space-occupying cysts[14]. The lung cysts were predominantly located in the diaphragmatic lobes, either as solitary or multiple lesions involving one or more pulmonary lobes[15]. The liver cysts were firm on palpation, often surrounded by a zone of hardened hepatic parenchyma[16]. In addition to that, liver surrounding tissues showed severe congestion, hepatomegaly, haemorrhages and pale areas of necrosis. These findings were corelated with the author [17] who recorded the similar details. Microscopic examination of cystic fluid confirmed the presence of protoscoleces with a characteristic two rows of hooks[18]. Viability of protoscoleces was confirmed with eosin stain was accordance with the author [19]. In iodine staining the refractile appearance of protoscoleces was related with the findings of earlier scientist[20].

Histopathological examination of the sections of the liver and lungs associated with hydatid cyst revealed a characteristically trilaminar structure, consisting of an innermost germinal (nucleated) layer, a middle acellular laminated layer composed of concentrically arranged collagen fibres, and an outer host-derived adventitial layer of fibrous connective tissue[12]. The adventitial layer was composed of densely packed fibroblasts, inflammatory cells, and granulation tissue, representing the host's protective response to the expanding parasitic cyst[21]. The protoscoleces structural details were clearly perceptible[15]in the histology sections. The liver sections also showed histopathological changes like congestion, infiltration of inflammatory cells and mononuclear cells mainly eosinophils and lymphocytes, chronic venous condition (Nutmeg appearance of the liver). Hepatocytes exhibited degeneration, with cytoplasmic vacuolation and nuclear pyknosis at the periphery of the cysts, with severity inversely proportional to the distance from the cyst wall[11,12]. Focal to extensive fibrosis and cirrhotic changes were observed in the hepatic parenchyma surrounding the cysts[22]. Increased numbers of Kupffer cells with sinusoidal congestion, bile duct proliferation, and areas of hepatic necrosis were also recorded in heavily infected livers[23]. Mononuclear inflammatory cell infiltration, predominantly lymphocytes and plasma cells, was distributed throughout the pericystic zones, with occasional eosinophils, reflecting both innate and adaptive immune responses of the host[24]. Focal calcification was also observed in some hepatic cysts, associated with degenerative changes in the cyst wall[12].

Histopathological changes observed in the lung cyst sections were similar as the liver cyst sections showing three layers i.e., inner germinal layer, middle lamellated/ laminated and outer fibrous layer. The germinal layer consists of brood capsules which were distinct in the cyst wall with free floating protoscoleces[22]. Lung sections adjacent to the hydatid cyst showed alveolar rupture, atelectatic or emphysematic areas with congestion, haemorrhages, mega alveoli formation, hyperplasia of bronchiolar epithelium. Infected lungs on rupture of the cyst showed collapsed condition with distortion of the laminated layer and adventitial layer present in the alveoli. Some of the sections revealed developing protoscoleces attached to the cyst wall. In few sections calcification was observed surrounding the cyst wall. In the lungs, significant histopathological changes were observed in the adjacent parenchyma, including dilatation and compression of pulmonary alveoli, extensive inflammatory cell infiltration comprising lymphocytes, eosinophils, neutrophils, and macrophages around the peri-cystic zone with necrotic areas[23]. Compact granuloma formation with a fibrous capsule was noted surrounding the cysts, along with fibrin-rich exudate leading to hyaline deposition in the alveolar walls. Bronchiolar epithelial proliferation was evident in sections adjacent to expanding cysts[24].

Previous studies have reported that simultaneous liver and lung involvement is comparatively less common than single-organ localization. Some scientist[26] reported that synchronous pulmonary and hepatic hydatid disease occurs only in about 4–25% of hydatid cases. Similarly[24] described concurrent liver and lung hydatid cysts as a relatively rare presentation despite both organs being the principal predilection sites. Studies on sheep hydatidosis have also demonstrated predominance of either hepatic or pulmonary localization independently[25]. Therefore, the absence of concurrent liver and lung infection in the present investigation does not contradict the established pathogenesis of hydatidosis but rather reflects variations

in host–parasite interaction, infection dynamics, and local epidemiological conditions.

CONCLUSION

In the current study overall prevalence of 2.37% hydatidosis was recorded in sheep slaughtered across the Rayalaseema region of Andhra Pradesh, confirming the occurrence of cystic echinococcosis in this part of southern India. Histopathological examination demonstrated significant and consistent tissue reaction in both lungs and liver, characterized by a trilaminar cyst wall, pericystic fibrosis, inflammatory cell infiltration, hepatocellular degeneration, pulmonary alveolar compression, and granuloma formation. These findings underscore the pathological impact of hydatidosis on ovine health, with implications for meat hygiene, organ condemnation, and zoonotic public health risk. Strengthening slaughterhouse surveillance, implementing targeted deworming programs in dogs, and public health awareness campaigns are warranted to curtail the transmission and spread of echinococcosis in the Rayalaseema region of Andhra Pradesh.

ACKNOWLEDGEMENT

The authors extend their sincere thanks to the Sri Venkateswara Veterinary University, Tirupati for providing the facilities necessary to conduct this study.

Financial support & sponsorship*:* None

Conflict of interest : None

Use of artificial intelligence (AI)-assisted technology for manuscript preparation: The authors confirm that there was no use of AI-assisted technology for assisting in the writing of the manuscript and no images were manipulated using AI.

REFERENCES

1. Haftu B, Kebede T. 2014. Study on prevalence and economic significance of bovine hydatidosis in Bako municipal abattoir, West Shoa zone, Oromiya regional state. *J Vet Sci Technol* **5**:197.
2. Vaidya VM, Zende RJ, Paturkar AM, Gatne ML, Dighe DG, Waghmare RN, Moon SL, Bhave SS, Bengale KG, Nikale NV. 2018. Cystic echinococcosis in animals and humans of Maharashtra State, India. *Acta Parasitol* **63(2)**:232–243.
3. Soulsby EJL. 1982. *Helminths, Arthropods and Protozoa of Domesticated Animals*. 7th edn. Bailliere Tindall, London, pp. 119–122.
4. Shahnazi, M., Jafari, A., Javadi, M. and Saraei, M. (2013). Fertility of hydatid cysts and viability of protoscoleces in slaughtered animals in Qazvin, Iran. Journal of Agricultural Sciences, **5(1)**:141.
5. Mandal S, Mandal MD. 2012. Human cystic echinococcosis: epidemiologic, zoonotic, clinical, diagnostic and therapeutic aspects. *Asian Pac J Trop Med* **5(4)**:253–260.
6. Godara R, Katoch R, Yadav A. 2012. Hydatidosis in goats in Jammu, India. *J Parasit Dis* **38(1)**:73–76.
7. Ibrahim SEA, Gameel AA. 2014. Pathological, histochemical and immunohistochemical studies of lungs and livers of cattle and sheep infected with hydatid disease. In: *Proceedings of 5th Annual Conference-Agricultural and Veterinary Research*, Khartoum, Sudan, **2(1)**:1–17.
8. Bancroft JD, Cook HC. 1994. *Manual of Histological Techniques and Their Diagnostic Application*. Churchill Livingstone, Edinburgh.
9. WHO. 2021. Echinococcosis. Available at: World Health Organization.
10. Beigh AB, Darzi MM, Bashir S, Shah A, Shah SA. 2018. The pathology of cystic echinococcosis and structural details of hydatid cyst and protoscolex. *Indian J Vet Pathol* **42(1)**:8–14.
11. Beigh AB, Darzi MM, Bashir S, Kashani B, Shah A. 2017. Gross and histopathological alterations associated with cystic echinococcosis in small ruminants. *J Parasit Dis* **41(4)**:1028–1033.
12. Moudgil A, Moudgil P, Asrani RK, Agnihotri RK. 2020. Hydatidosis in slaughtered sheep and goats in India: prevalence, genotypic characterization and pathological studies. *J Helminthol* **93(6)**:768–775.
13. Kumari S, Singh R, Kumar A, Singh S, Yadav J. 2017. Pathomorphological diagnosis of hydatidosis in slaughtered sheep. *Int J Livest Res* **7(9)**:246–251.
14. Rashid A, Darzi MM, Mir MS, Dar LM. 2019. Pathological and histochemical studies on cystic echinococcosis in sheep. *SKUAST J Res* **21(1)**:50–58.
15. Hansh WJ. 2019. The study of histopathological changes in some of intermediate hosts infected with cystic echinococcosis. *Univ Thi-Qar J Sci* **7(1)**:249.
16. Jogdand BM, Gangane GR, Moregaonkar SD, Rathod PR, Chigure GM, Ghorpade BP, Zende RJ, Patil AA, Bhagwat PN, Kadam ST. 2024. Pathomorphological alterations in goats afflicted with cystic echinococcosis. *Int J Vet Sci Anim Husb* **9(5)**:692–698.
17. Fallah M, Kavand A, Mashouf RY. 2014. Infected hydatid cyst bacteria in slaughtered livestock and their effects on protoscoleces degeneration. *Jundishapur J Microbiol* 7(6):e10135.
18. Mahmoudvand H, Harandi MF, Shakibaie M, Aflatoonian MR, ZiaAli N, Makki MS, Jahanbakhsh S. 2014. Scolicidal effects of biogenic selenium nanoparticles against protoscolices of hydatid cysts. *Int J Surg* **12(5)**:399–403.
19. Siddartha PV, Babu AJ, Rao TM, Rayulu VC, Swetha CS. 2022. A comparative evaluation of four different immunoassays in the diagnosis of cystic echinococcosis using crude and purified hydatid cyst fluid antigen. *Acta Parasitol* **67(4)**:1667–1679.
20. Barnes TS, Hinds LA, Jenkins DJ, Bielefeldt-Ohmann H, Lightowlers MW. 2011. Comparative pathology of pulmonary hydatid cysts in macropods and sheep. *J Comp Pathol* **144(4)**:333–342.
21. Al Malki J, Ahmed N. 2022. Epidemiological and histomorphic studies in sheep infected with hydatid cyst in Taif area. *Saudi J Biol Sci* **29(2)**:886–893.
22. Al-Aubaidi IK, Yaseen AN, Gathwan MA. 2019. Histopathological study of hepatic and pulmonary sheep hydatidosis. *Ann Trop Med Publ Health* **22(4)**: SPe155.
23. Usman M, Rizwan HM, Sajid MS, Kausar R, Tahir UB, Abbas H, Ateeq MK, Raza M, Maqbool M, Fouad D, Ataya FS. 2024. Prevalence and histopathological analysis of cystic echinococcosis in ruminants of District Narowal, Pakistan: focus on pulmonary involvement. *Braz J Vet Parasitol* **33(4):**e016824.
24. Iqbal N, Hussain M, Idress R. 2017. Disseminated hydatid cyst of liver and lung. *BMJ Case Rep*. **bcr-2017**-222808.
25. Dalal U, Dalal AK, Singal R. 2017. Concomitant lung and liver hydatid cyst managed as one-stage surgery. *Maedica (Bucur)* **12(1):**19–22.
26. Amarir FE, Rhalem A, Marcotty T, Dorney P, Sadak A, Azrib R, Kirschvink N. 2022. Epidemiological aspects of cystic echinococcosis in small ruminants. *Small Rum Res* **210**:106671.