Indian J. Vet. Pathol., 50(4) : 316-323, 2026: DOI: https://doi.org/10.56093/v1rm4f03

RESEARCH ARTICLE

Pathological and molecular insights into *Toxoplasma gondii* in aborted fetuses of goat and slaughtered goats in Mymensingh district, Bangladesh

Mahmuda Islam, Nazneen Sultana, Moutuza Mostaree, Thahsin Farjana[1], Munmun Pervin and Mohammad Abu Hadi Noor Ali Khan[*]

Department of Pathology, Faculty of Veterinary Science, Bangladesh Agricultural University (BAU), Mymensingh-2202
[1]Department of Parasitology

[*]**Address for correspondence**
Dr Mohammad Abu Hadi Noor Ali Khan, E-mail: hadi.khan@bau.edu.bd, nazneen41151@bau.edu.bd
ORCID ID: 0000-0002-3612-2443, 0000-0001-8060-4805, 0000-0003-1380-908X, 0000-0001-6033-5505, 0000-0002-5514-5798, 0000-0002-8409-4571

Received: 26.8.26; Accepted: 25.9.26

ABSTRACT

The study attempted to investigate *Toxoplasma gondii* infection in aborted goat fetuses and slaughtered goats. A total of 29 aborted fetuses and 50 slaughtered goats were examined. The liver, spleen, kidney, stomach, and placenta from the aborted fetuses and the liver, spleen, and kidney from the slaughtered goats were collected from Mymensingh district, Bangladesh. The organs were fixed in 10% neutral buffered formalin and processed for H&E staining to visualize specific lesions. Gross examination revealed hepatomegaly with fragile, pale livers and kidneys, while placentas showed necrosis, swelling, and whitish foci. Histopathological examination revealed banana-shaped tachyzoites of *T. gondii* in three fetuses. In addition, placentitis with congestion, haemorrhage, and mononuclear cell infiltration, as well as hepatic granulomas, were observed in suspected *T. gondii*-infected cases. Tissue samples were collected aseptically in falcon tubes and cryovials and preserved at -20ºC for DNA extraction and PCR detection. PCR analysis of fetal DNA detected *T. gondii* (B1 gene, 512 bp) in five cases (17.24%), and DNA extracted from slaughtered goats (N = 50) detected *T. gondii* in one case (2%). The partial sequence of the B1 gene of *T. gondii* was sequenced and deposited in GenBank (accession number: OP627282). Bangladeshi isolates of *T. gondii* showed the highest similarity with the isolates from Mexico but also revealed genetic relatedness with other global isolates.

Keywords: Abortion, Black Bengal goats, Histopathology, PCR, phylogeny, *T. gondii*

INTRODUCTION

Toxoplasmosis is an important intracellular apicomplexan protozoan disease of humans and animals caused by the parasite *Toxoplasma gondii*. Globally, approximately 500 million people are infected yearly by these protozoa[1]. Throughout the world, *T. gondii* is a significant medical and veterinary issue[2] causing financial losses due to congenital disease and abortions, [3,4]. Among animals, Toxoplasmosis is an economically significant disease of small ruminants and is recognized as one of the focal causes of infective abortions as it can result in early embryonic death and resorption, foetal death and mummification, abortion, stillbirth, and neonatal death[5]. The main methods of transmission for humans are eating raw or undercooked meat contaminated with *T. gondii* cysts, drinking contaminated food or water, or accidentally ingesting the oocysts[6]. Infection from raw goat and sheep milk consumption has recently reported[7,8].

Numerous serological tests conducted throughout the world, including Bangladesh, served as the basis for most of the epidemiological studies on *T. gondii*[9]. In Bangladesh, sheep, goats, and cattle are frequently used as food sources. Earlier studies in Bangladesh have reported that the seroprevalence of toxoplasmosis in cattle varied from 12 to 27%, 12 to 61% in goats 18 to 69% in sheep[10-13].

Histopathological analysis, serological tests, isolation of the parasite in mouse inoculation[14-17], and the amplification of parasite DNA by various molecular techniques, such as polymerase chain reaction (PCR), quantitative polymerase chain reaction (qPCR), and loop-mediated isothermal amplification (LAMP), have been used for the diagnosis of toxoplasmosis. Although the LAMP procedure is simple, quick, and requires the least amount of time, LAMP reagents are expensive[18]. Molecular methods based on polymerase chain reaction (PCR) are simple, sensitive, and reproducible and can be applied to all clinical samples[19,20,21]. The B1 gene of *T. gondii* is extremely conserved, and PCR amplification of this gene has been effectively used to detect a minute amount of

How to cite this article: Islam, M., Sultana, N., Mostaree, M., Farjana, F., Pervin, M. and Khan, M.A.H.N.A. 2026. Pathological and molecular insights into *Toxoplasma gondii* in aborted fetuses of goat and slaughtered goats in Mymensingh district, Bangladesh. Indian J. Vet. Pathol., 50(4) : 316-323.

parasite DNA[22]. In this study, B1 gene fragment of *T. gondii* were amplified using a uniplex conventional PCR. Due to its frequent use in the detection of *T. gondii*, this gene was chosen [9,23,24]. In Bangladesh, there are few investigations on the molecular detection of caprine abortion[9,13]. This study aimed to investigate gross and histopathological alterations in visceral organs and to molecularly characterize *T. gondii* infection in aborted goat fetuses and slaughtered goats in Mymensingh, Bangladesh.

MATERIALS AND METHODS

Collection of samples

A total of 29 aborted fetuses and 50 slaughtered female goats were collected from Mymensingh during the period from January 2018 to December 2019. Aborted fetuses were collected from veterinary clinics and Upazilla Livestock Hospital in Mymensingh district. Slaughtered goat samples were collected from different slaughterhouses in Mymensingh District, Bangladesh. The liver, spleen, kidney, stomach, and placenta from the aborted fetus and the liver, spleen, and kidney from the slaughtered goats were collected. The organs were fixed in 10% neutral buffered formalin, and the formalin-fixed tissues were processed, sectioned, and stained with hematoxylin and eosin (H&E) stain[25]. Parts of the organs were collected in falcon tubes and cryovials and preserved at -20°C for DNA extraction and PCR detection of *T. gondii*.

Histopathology

Formalin-fixed tissues were processed and embedded in paraffin. Paraffin-embedded tissues were then sectioned and stained with hematoxylin and eosin (H&E) stain[25]. The stained sections were observed under a light microscope (Carl-Zeiss), and images were captured

DNA extraction from tissue samples

DNA was extracted from the liver, spleen, kidney, stomach, and placenta of the aborted fetus and from the liver, spleen, and kidney of the slaughtered goats. The Wizard® Genomic DNA Extraction Kit (Promega, Inc., USA) was used to extract the DNA using manufacturer instructions. The quality and quantity of the extracted DNA were measured by spectrophotometry (A^{260}/A^{280}) (Nanodrop 2000 machine, Shimadzu, Japan) and agarose gel (1.5%) electrophoresis, respectively. A260/A280ratio of 1.75 -2.0 was considered a reasonable purity of DNA and was used in this study. Approximately 200–300 ng/μL was dissolved in RNase-free water and stored at -20°C until used in PCR amplification. Table. 1 contains the list of primers used in this study to detect *T. gondii*[26].

Polymerase chain reaction (PCR)

PCR reactions were performed on each DNA sample in a 25 μl reaction mix containing 12.5 μl of One *Taq*® Quick-Load® 2X Master Mix with standard buffer (New England Biolabs, USA), 1 μl (20 pmol) of each primer, 9.5 μl nuclease-free water, and 1 μl template DNA/water (for the water control tube). The following thermal profile was used for DNA amplification in a thermal cycler (Thermal Cycler PCR systems with Gradient Thermo Fisher Scientific, USA): Initial denaturation step at 94°C for 30 s in the first cycle, followed by 35 cycles on 30 sec at 94°C for denaturation, 58.5°C for 30 sec for annealing, and 30 sec at 68°C for extension. This was followed by a final extension of 5 minutes at 68 °C. After completion of the PCR reaction, the tubes were held at 4°C.

Electrophoresis

The amplified PCR products were electrophoresed in 1.5% agarose gel, stained with ethidium bromide, and examined using a UV transilluminator documentation system (Cell Biosciences, Alphalmager HP, USA).

RESULTS

Age distribution

In this study, the gestational age of the aborted fetuses ranged from 1.5 to 5 months (Fig. 1). The ages of goats with abortion cases ranged from 10 months to 4 years.

Gross pathological observations

The majority of fetuses were collected fresh, but a few showed evidence of autolysis. Obvious lesions were not seen on the fetuses (Fig. 1). Although no significant gross lesions were seen, hepatomegaly, fragile and pale liver and kidney were recorded (Fig. 2). The placental changes recorded were necrosis, swelling, and freckling with whitish foci in the cotyledons (Fig. 3). No significant gross changes could be ascertained in the visceral organs examined of the slaughtered goats.

Histopathological observations

Histopathological changes demonstrated banana-shaped tachyzoites of *T. gondii* in the fetal spleen. The spleen showed atrophic changes, thickened trabeculi, lymphocytic depletion and haemorrhages (Fig. 4). Tachyzoites of *T. gondii* were also in the hepatic

Table 1. Oligonucleotide primers used for the detection of ***Toxoplasma gondii***

Primers	Sequences (5′-3′)	Gene/Amplicon size	References
ToxoplsF1	gaattcgttcgacagaaaggg	B1/ 512bp	Ahmad *et al.*[26]
ToxoplsR1	catttcacctgtatttgccagc		



Fig. 1. Gross findings of aborted goat fetuses (a–c) delivered at 2.5, 3, and 3.5 months of gestation, respectively.



Fig. 2. Visceral organs of aborted fetus (a) pale liver and kidney, fragile liver, (b) fragile liver, (c) hepatomegaly.



Fig. 3. Placenta from goat (a) necrosed, swollen and whitish cotyledon; (b) whitish necrotic foci in the cotyledon; (c) autolyzed placenta.

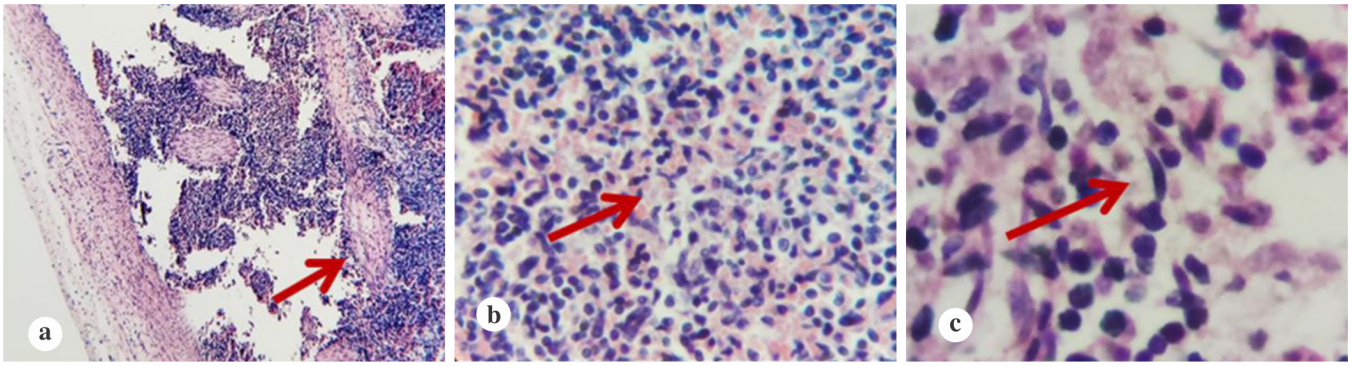

Fig. 4. Histopathology of the spleen of *Toxoplasma gondii* infected aborted goat fetus. a: atrophy of the spleen with thicker trabeculi and lymphocytic depletion(arrow), b: lymphocytic depletion and haemorrhages(arrow), c: higher magnification of (b) showing banana shaped tachyzoites of *Toxoplasma* (arrow). H&E; a = 10×, b = 40×, c = 100×.

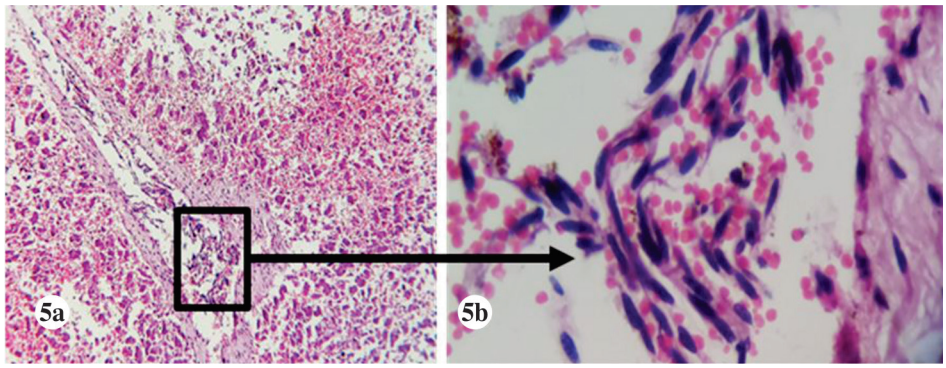

Fig. 5. Histopathology of the liver of *Toxoplasma gondii* infected aborted goat fetus. **(a-b)** banana-shaped tachyzoites of *Toxoplasma* in the central vein (arrow). H&E; a = 40x, b = 100x

Fig. 6. Histopathology of the placenta of *Toxoplasma gondii* infected aborted goat fetus; **(a)** placentitis; **(b)** congestion and haemorrhages (arrow); **(c)** infiltration of mononuclear cells (arrow) into the trophoblastic epithelium. H&E; a=10x, b=40x, c=100x.

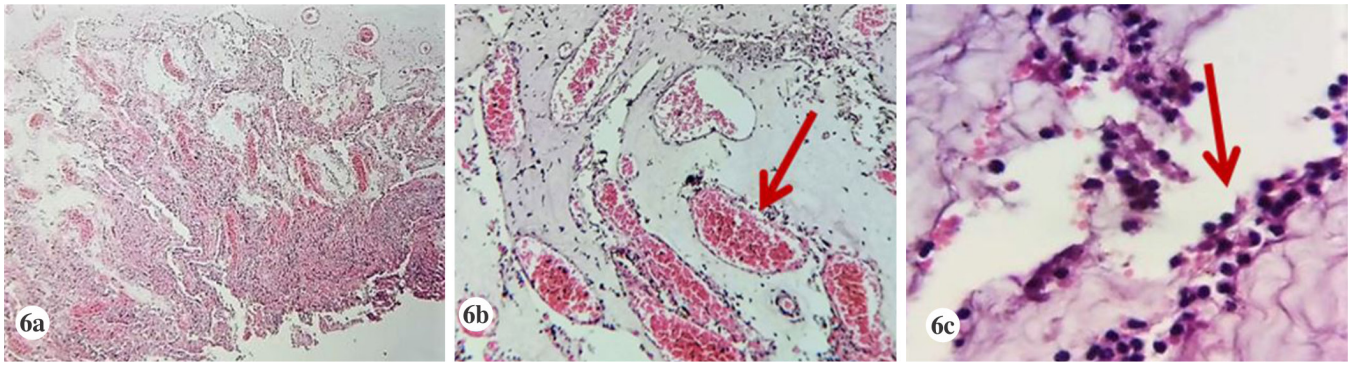

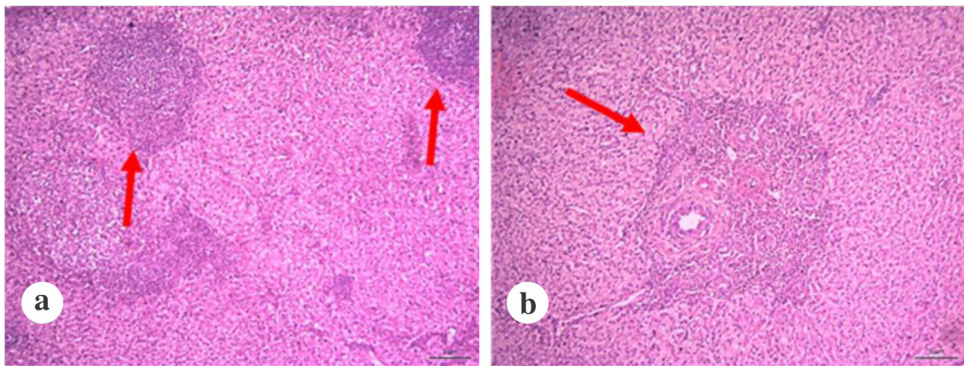

Fig. 7. Histopathology of the liver of slaughtered goat; **(a)** hepatic granuloma; **(b)** hepatic granuloma in the portal area (arrow) were seen in cases infected with *Toxoplasma gondii*. H&E; a-b = 10x.

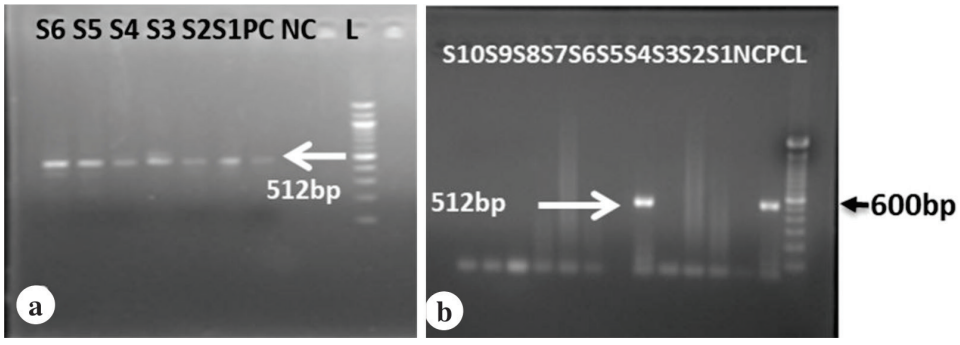

Fig. 8. PCR detection of the **B1 gene of *T. gondii*** from **(a)** the aborted fetus and **(b)**slaughtered goat, respectively. The lane L stands for 100bp DNA ladder, PC is for positive control, and NC is for negative control. Amplification of 512bp fragment specific for *T. gondii* was seen on agarose gel electrophoresis in **(a)** aborted fetus Lane S1 to S6: positive samples and **(b)** slaughtered goat Lane S4: positive sample.

central vein (Fig. 5). Placental examination of two aborted fetuses suspected of *T. gondii* infection and revealed placentitis, congestion and haemorrhages, and infiltration of mononuclear cells (Fig. 6). The histopathological examination of the liver of a slaughtered goat suspected to be infected with *T. gondii* showed a hepatic granuloma (Fig. 7).

Results of PCR

PCR analysis of DNA extracted (N=29) showed *T. gondii* PCR amplicons (B1 gene, 512bp) (Figure 8a) in five cases (17.24%). DNA (N=50) extracted from the slaughtered goats showed *T. gondi* (B1 gene, 512bp) (Figure 8b) in a case (2%).

Phylogenetic analyses of *T. gondii*

The partial sequence of the B1 gene (512 bp length) of *T. gondii was* carried out, and the sequence information was used in phylogenetic

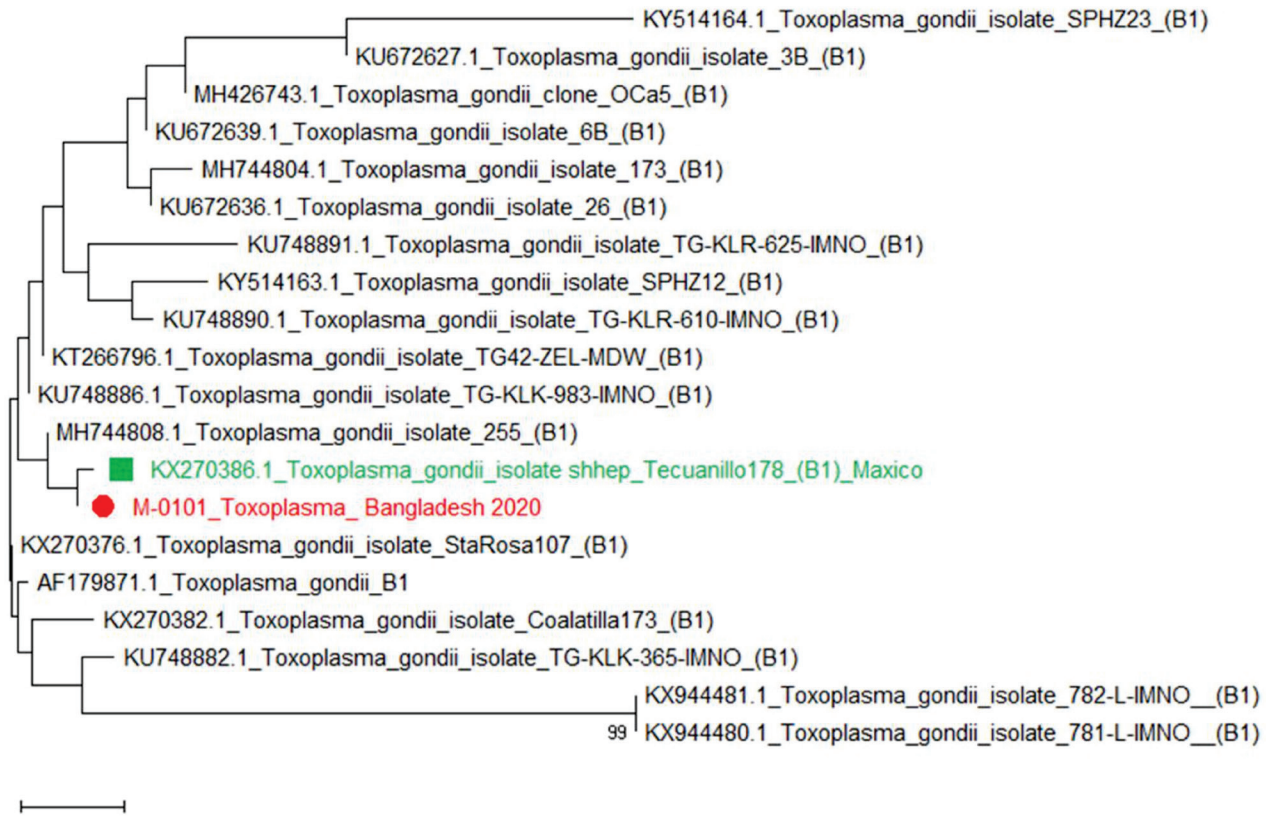

Fig. 9. Bangladeshi isolate showed highest similarity with a Mexican isolate but also revealed genetic relatedness with other global isolates

analysis. The B1 gene of *T. gondii* sequences obtained in the current study were submitted to GenBank database and the accession number (OP627282) was obtained. Results of phylogenetic analysis of B1 gene showed that the *T. gondii* of the Bangladeshi isolate showed the highest similarity to isolates from Mexico and North India but also revealed genetic relatedness with other global isolates. The current study successfully analyzed the sequences of the B1 gene of *Toxoplasm*a, and its phylogenetic position was identified (Fig. 9).

DISCUSSION

In this study, the gestation age of aborted fetuses ranged from 1.5 to 5 months. Abortion cases in goats were observed in the age group of 10 months to 4 years. Infections that occur between 40 and 120 days of gestation may cause fetal mummification and maceration or abortion. Infection after 120 days causes stillbirth and or the birth of weak offspring[5]. Most abortions associated with *T. gondii* infection occurred in ewes aged 1–3 years during the late stages of pregnancy, consistent with the previous[27] and current study.

At necropsy, the majority of the aborted fetuses had hepatomegaly, along with fragile and pale livers and kidneys. Grossly, the placenta was enlarged, reddish, and friable in aborted ewe fetuses, and its cotyledons were covered in white foci or necrotic nodules, which is consistent with previous findings[27]. The cotyledons of aborted sheep fetuses showed necrotizing placentitis with several white foci[28]. Grossly, the placenta was enlarged, reddish, and friable in aborted ewe fetuses, and its cotyledons were covered with white foci or necrotic nodules[27]. The cotyledons of aborted sheep fetuses showed necrotizing placentitis with several white foci[28]. Grossly, numerous focal areas of necrosis and grayish white calcification were present in the placenta of goat[29]. Ahmed *et al*[30]. reported reported that most of the aborted caprine fetuses infected by *Toxoplasma* displayed a rounded-bordered, friable, congested liver[30]. In this study, in addition to the histopathological changes in tissues banana-shaped tachyzoites of Toxoplasma were seen in the fetal spleen. Atrophy of the spleen with thicker trabeculi, lymphocytic depletion and hemorrhages were present. The liver of an aborted goat fetus showed banana-shaped tachyzoites of toxoplasma in the central vein. According to previous study, the liver, brain, heart, and lungs of the aborted fetuses /species showed the most frequent histopathological changes, including severe congestion, necrosis, and infiltration of multinucleated cells, as well as tissue cysts, tachyzoites, and bradyzoites, and the brain and heart showed the

most clusters of dark purple, banana-shaped *T. gondii* tachyzoites[27]. There were intracellular protozoa in the heart, lung, and liver tissues[31]. Histological investigation revealed many parasite cysts of varied sizes embedded and dispersed between cardiac muscle fibers in sheep hearts[32]. Mild multifocal necrotizing pneumonia with intralesional protozoan tachyzoites was discovered in the lungs of sows and aborted fetuses. Histopathologic analysis of lungs, livers, lymph nodes, and brains revealed multifocal necrotic lesions connected to nearby protozoan tachyzoites[33]. Large clusters of *T. gondii* with the appearance of dark purple bananas were seen in the cardiac tissue of most of the individuals examined [30]. In the present study, the placenta of an aborted goat infected by *T. gondii* shows placentitis, haemorrhage and congestion, and infiltration of mononuclear cells. In the placental sections of some aborted goats, the placenta was bloated, crimson, and friable, and its cotyledons were covered in whitish foci or nodules of necrosis, as well as intracellular *T. gondii* tachyzoites[27]. The most frequent lesion caused by *T. gondii* during abortion is necrotizing placentitis, which almost exclusively affects cotyledonary regions [34]. In this study, histopathological examination of the liver of a slaughtered goat infected with *T. gondii* revealed a hepatic granuloma. The liver also displayed multifocal necrosis with mononuclear cell infiltration, primarily comprising lymphocytes and macrophages[35]. Multifocal portal granuloma with macrophage and mononuclear cell infiltration was also noted[36].

In the present study, *T. gondii* DNA was detected in five cases (17.24%) in aborted fetuses and DNA extracted from the slaughtered goats showed *T. gondii* in one case (2%) by PCR. Results obtained from the aborted fetus were almost identical to those reported by Sah *et al*.[9] who were also the first to report on molecular detection of *T. gondii* in sheep and goat aborted fetuses in Bangladesh, with a rate of 15.52%[9]. Similar findings were reported by[37] from Chennai, South India. In Iran, the presence of *T. gondii* DNA was detected by PCR in liver samples from 17.3% and 16% of sheep and goats, respectively [38]. *Toxoplasma* DNA was found in 12.0% of aborted sheep fetuses in Iran's North Khorasan Province[39] and 8.3% of aborted caprine and ovine fetuses in Iran's Kordestan Province[40]. The result of the slaughter sample analysis was identical to that reported by[2] from North India, where *T. gondii* infection was found in 1.35% and 1.69% of slaughter goats and sheep, respectively. The prevalence of *T. gondii* infection in aborted fetuses of sheep and goats was estimated to be 5.4% and 3.8%, respectively, in Spain[41]. The prevalence of *T. gondii* DNA in goats was reported as 5.2% in China [42]. However, many studies showed higher prevalence values for *T. gondii* infection. The infection rate of *T. gondii* was found to be 27% and 31% in goats and sheep, respectively, in Iran [43]. *T. gondii* PCR positivity was detected as 29.8% in Jordan [44]. In Bangladesh, a higher prevalence of *T. gondii* as detected by PCR was reported as 35% in aborted goat fetuses [45]. Literature available indicates the prevalence of toxoplasmosis ranges from 2 to 35%. The study observed the prevalence of toxoplasmosis of around 17%, which appeared similar to the previous observation. The BLAST comparison of the partial sequences of the B1 gene (512 bp length) of *T. gondii* Bangladeshi isolate (accession no. OP627282) was found to be more closely related to those reported from other geographical locations, and include: Mexico (accession no. KX270376, KX270382), USA (accession no. AF179871, MH426743, MH744808), Iran (accession no. KU672636, KU672627, KU672639), Poland (accession no. KX270376, KU748891, KU748886), and India (accession no. KY514164, KY514163). The isolate of *T. gondii* revealed 97–99% identity with sequences from other strains present in the GenBank. The Bangladeshi isolate of *T. gondii* showed the highest similarity with the isolates from Mexico (99.4%), North India (98.5%), and Poland (98.89%) but also revealed genetic relatedness with other global isolates. B1 gene of *T. gondii* coding sequences obtained by[2] and found (94–98%) homology with *T. gondii* type I RH strain, USA (AF179871). 99% similarity in sequence of *T. gondii* with the sequence from Brazil (FJ176233) was reported by[46].

CONCLUSIONS

The present study has provided evidence of the involvement of *T. gondii* in the aborted fetuses and placentas of goats. *T. gondii* may be one of the potential agents responsible for causing a significant rate of goat abortions in Bangladesh. The presence of the organism in the tissue demonstrates a health hazard for the human inhabitants who ordinarily consume goat meat. The possibility of *T. gondii* infection in goats poses a threat to public health. We need more research to better understand the different genotypes of *T. gondii* that cause abortion in goat populations in Bangladesh.

ACKNOWLEDGEMENT

The authors extend their gratitude to the Department of Veterinary Pathology, Faculty of Veterinary Science, Bangladesh Agricultural University for providing the facilities necessary to conduct this study.

Financial support & sponsorship: The authors are grateful to the Ministry of Education (MOE), Bangladesh for funding the research (Project ID.:2017/189/MoE) and thanked the Bangladesh Agricultural University Research System (BAURES).

Conflicts of Interest: None

Use of Artificial Intelligence (AI)-Assisted Technology for manuscript preparation: The authors confirm that

there was no use of AI-assisted technology for assisting in the writing of the manuscript and no images were manipulated using AI.

REFERENCES

1. Bob. 2011. Dr. Bob's all creatures site. WWW.Petdoc.ws, Zoonotic Diseases. pp 1-169 file:///F:/zoonotic_ diseases1.htm.
2. Kalambhe D, Gill JP, Singh BB.2017. Molecular detection of *Toxoplasma gondii* in the slaughter sheep and goats from North India. *Vet Parasitol.* **241:**35-38.
3. Dubey JP, Beattie CP.1988. Toxoplasmosis of Animals and Man. CRC Press, Florida, U.S.A, Boca Raton. pp. 1–220.
4. Remington JS, Desmonts G.1990. Toxoplasmosis: Infectious Diseases of the Fetus and Newborn Infant. vol. *30. W. B. Saunders, Philadelphia, Santa Maria* pp. 123–127.
5. Dubey J. 2009. Toxoplasmosis in sheep—the last 20 years. *Vet Parasitol.* **163**(1–2): 1–14.
6. Dubey JP, Schares G. 2011. Neosporosis in animals – the last five years. *Vet Parasitol* **180(1-2)**:90-108.
7. de Santana Rocha D, de Sousa Moura RL, Maciel BM, Guimarães LA, O'dwyer HN, Munhoz AD, Albuquerque GR. 2015. Detection of *Toxoplasma gondii* DNA in naturally infected sheep's milk. *Genet Mol Res.* **14(3)**:8658-8662.
8. Amairia S, Rouatbi M, Rjeibi MR, Nouasri H, Sassi L, Mhadhbi M and Gharbi M .2016. Molecular prevalence of *Toxoplasma gondii* DNA in goats' milk and seroprevalence in Northwest Tunisia. *Vet Med Sci.***2(3):**154–160.
9. Sah RP, Dey AR, Rahman AA, Alam MZ, Talukder MH.2019. Molecular detection of *Toxoplasma gondii* from aborted fetuses of sheep, goats and cattle in Bangladesh. *Vet Parasitol Reg Stud Reports.* **18:**100347.
10. Samad MA, Rahman KB and Halder AK. 1993. Seroprevalence of *Toxoplasma gondii* in domestic ruminants in Bangladesh. *Vet Parasitol* **47**(1-2):157-159.
11. Shahiduzzaman M, Islam MR, Khatun MM, Batanova TA, Kitoh K, Takashima Y. 2011. *Toxoplasma gondii* seroprevalence in domestic animals and humans in Mymensingh District, Bangladesh. *J Vet Med Sci.***73:**1375– 1376
12. Rahman M, Azad MT, Nahar L, Rouf SM, Ohya K, Chiou SP, Baba M, Kitoh K, Takashima Y.2014. Age-specificity of *Toxoplasma gondii* seroprevalence in sheep, goats and cattle on subsistence farms in Bangladesh. *Bangladesh. J Vet Med Sci.***76**(9):1257-1259.
13. Sah RP, Talukder MH, Rahman AA, Alam MZ, Ward MP.2018. Seroprevalence of *Toxoplasma gondii* infection in ruminants in selected districts in Bangladesh. *Vet Parasitol Reg Stud Reports.* **11**:1-5.
14. da Silva AV, Langoni H.2001.The detection of *Toxoplasma gondii* by comparing cytology, histopathology, bioassay in mice, and the polymerase chain reaction (PCR). *Vet Parasitol* **97**(3):193-200.
15. Masala G, Porcu R, Madau L, Tanda A, Ibba B, Satta G, Tola S.2003. Survey of ovine and caprine toxoplasmosis by IFAT and PCR assays in Sardinia, Italy. *Vet Parasitol* **117**(1-2):15-21.
16. Remington JS, Thulliez P, Montoya JG.2004. Recent developments for diagnosis of toxoplasmosis. *J Clin Microbiol.* **42**:941–945.
17. Garcia JL, Gennari SM, Machado RZ, Navarro IT .2006. *Toxoplasma gondii*: detection by mouse bioassay, histopathology, and polymerase chain reaction in tissues from experimentally infected pigs. *Exp Parasitol.* **113**(4):267-271.
18. Wang Y, Wang G, Zhang D, Yin H, Wang M.2013. Detection of acute toxoplasmosis in pigs using loop mediated isothermal amplification and quantitative PCR. *Korean J Parasitol.* **51:**573–577.
15. Contini C and Picot S. 2005. Evaluation of a Real-time PCR based assay using the light cycler system for detection of *Toxoplasma gondii* bradyzoite genes in blood 23 specimens from patients with toxoplasmic retinochoroiditis. *Int J Parasitol.* **35**(3):275-283.
16. Tlamçani Z, Lemkhenete Z and Lmimouni BE. 2013.Toxoplasmosis: The value of molecular methods in diagnosis compared to conventional methods. *J. Microbiol. Infect. Dis.* **3**(2):93-99.
17. Gashou A, Amro A, Erhuma M, Al-Dwibe H, Elmaihub E, Babba H, Nattah N, Abudher A. 2016. Molecular diagnosis of *Toxoplasma gondii* infection in Libya. *BMC Infect Dis*.**16**(1):1-8.
18. Dubey JP, Morales JA, Villalobos P, Lindsay DS, Blagburn BL, Topper MJ.1996. Neosporosis-associated abortion in a dairy goat. *J Am Vet Med Assoc.* **208**:263–265.
19. Thakur R, Sharma R, Aulakh RS, Gill JP, Singh BB.2019. Prevalence, molecular detection and risk factors investigation for the occurrence of *Toxoplasma gondii* in slaughter pigs in North India. *BMC Vet Res.***15**(1):1-7.
20. Sroka J, Karamon J, Wójcik-Fatla A, Piotrowska W, Dutkiewicz J, Bilska-Zając E, Zając V, Kochanowski M, Dąbrowska J, Cencek T.2020. *Toxoplasma gondii* infection in slaughtered pigs and cattle in Poland: seroprevalence, molecular detection and characterization of parasites in meat. *Parasit Vectors.***13**(1):223.
21. Luna LG.1968. Manual of Histologic Staining Methods of the Armed Forces Institute of Pathology; McGraw Hill Book Co., New York, USA
22. Jahan AA, Ruba T, Mumu TT, Rana MS, Islam M, Belal SM, Khan MA and Bari AM. 2018.Pathological and molecular detection of diseases of cattle at slaughter. *Bangl. j. vet. med.* **16**:213-222.
23. Khanamir RA, Naqid IA, Zangana IQ.2020. Histopathological and Serological Analysis of Aborted Ewes and Neonatal Death with *Toxoplasma gondii* in Duhok City, Kurdistan-Iraq. *Arch Razi Inst.* **75**(2):241-248.
24. Dorsch MA, Francia ME, Tana LR, González FC, Cabrera A, Calleros L, Sanguinetti M, Barcellos M, Zarantonelli L, Ciuffo C, Maya L, Castells M, Mirazo S, da Silva Silveira C, Rabaza A, Caffarena RD, Doncel Díaz B, Aráoz V, Matto C, Armendano JI, Salada S, Fraga M, Fierro S, Giannitti F.2022. Diagnostic Investigation of 100 Cases of Abortion in Sheep in Uruguay: 2015-2021. *Front Vet Sci.* 9:904786.
25. AbouZeid NZ, Amer HA, Barakat TM, Selim A, El-Balkemey F.2010. Toxoplasmosis is naturally and experimentally infected goats. *Am. J. Sci.* **6**(11):122-9.
26. Ahmed YF, Sokkar SM, Desouky HM, Soror AH.2008. Abortion is due to toxoplasmosis in small ruminants. *Glob. Vet.* **2**(6):337-342.
27. Tokiwa T, Yoshimura H, Hiruma S, Akahori Y, Suzuki A, Ito K, Yamamoto M, Ike K.2019. *Toxoplasma gondii* infection in Amami spiny rat on Amami Oshima Island, Japan. *Int J Parasitol Parasites Wildl.* **9**:244-247.
28. Al-Khafagi AM, Zainab RZ.2016. Histopathological and diagnostic study of Toxoplasmosis in human and sheep by using ELISA in Kut city. *Iraqi J. Vet. Med.* **40**(2):94-9.
29. Kim JH, Kang KI, Kang WC, Sohn HJ, Jean YH, Park BK, Kim Y, Kim DY.2009. Porcine abortion outbreak associated with *Toxoplasma gondii* in Jeju Island, Korea. *J Vet Sci.***10**(2):147-151.
30. Dubey JP, Kirkbride CA.1990. Toxoplasmosis and other causes of abortions in sheep from north central United States. *J Am Vet Med Assoc.* **196**:287-290.
31. El-Gawady HM, Abdel-Aal AA, Sallam NH, Youssif EM.2018. Molecular studies on *Toxoplasma gondii* in sheep and goats in

Ismailia Province. *Archives of Infectious Diseases and Therapy* **2**:1-4.
32. Mahmood NA, Dawood MN. 2012. Liver function tests in toxoplasmosis. *Ann. Coll. Med. Mosul.* **38**(2).
33. Satbige AS, Sreekumar C, Rajendran C, Vijaya BM.2017. Isolation and characterization of *Toxoplasma gondii* from small ruminants (sheep and goats) in Chennai City, South India. *J Parasit Dis.***41**:869-873.
34. Yousefvand A, Mirhosseini SA, Ghorbani M, Mohammadzadeh T, Moghaddam MM, Mohammadyari S.2021. Molecular and serological detection and of *Toxoplasma gondii* in small ruminants of southwest Iran and the potential risks for consumers. *J Verbrauch Lebensm.***16(2)**:117-127.
35. Salehi M, Nezami H, Niazkar HR.2020. Investigation of *Toxoplasma gondii* infection in aborted fetuses of sheep using PCR: a study in north Khorasan province, Iran. *Vet Med Int.* **2020**:7913912.
36. Partoandazanpoor A, Sadeghi-Dehkordi Z, Ekradi L, Khordadmehr M, Rassouli M, Sazmand A.2020. Molecular diagnosis and pathological study of *Toxoplasma gondii* in aborted caprine and ovine fetuses in borderline of Iran–Iraq. *Acta Parasitol.* **65**(1):187-192.
37. Moreno B, Collantes-Fernández A,Villa A, Navarro A, Regidor-Cerrillo J, Ortega-Mora LM.2012. Occurrence of *Neospora caninum* and *Toxoplasma gondii* infections in ovine and caprine abortions. *Vet Parasitol.***187**:312–318.
38. Qian W, Yan W, Lv C, Bai R, Wang T, Wei Z, Zhang M.2020. Molecular detection and genotyping of *Toxoplasma gondii* and *Neospora caninum* in slaughtered goats in Central China. *Foodborne Pathog Dis.***17**(5):348–356.
39. Sharif M, Sarvi S, Shokri A, Hosseini Teshnizi S, Rahimi MT, Mizani A, Daryani A.2015. *Toxoplasma gondii* infection among sheep and goats in Iran: a systematic review and meta-analysis. *Parasitol Res.***114**:1–16.
40. Abu-Dalbouh MA, Ababneh MM, Giadinis ND, Lafi SQ.2012. Ovine and caprine toxoplasmosis (Toxoplasma gondii) in aborted animals in Jordanian goat and sheep flocks. *Trop Anim Health Prod.***44**(1):49-54.
41. Hasan T, Mannan A, Hossain D, Rekha A, Hossan MM, Alim MA, Uddin AHMM.2021. Molecular detection of *Toxoplasma gondii* in aborted fetuses of goats in Chattogram, Bangladesh. *Vet World.* **14**(9): 2386-2391.
42. Rouatbi M, Amdouni Y, Amairia S, Rjeibi MR, Sammoudi S, Rekik M, Gharbi M. 2016.Molecular detection and phylogenetic analyses of *Toxoplasma gondii* from naturally infected sheep in Northern and Central Tunisia. *Vet Med Sci.* **3(1)**:22-31