Indian J. Vet. Pathol., 50(4) : 328-334, 2026: DOI: https://doi.org/10.56093/n9dm6440

RESEARCH ARTICLE

Pathomorphological and immunohistochemical studies on male genital tract tumors in dogs

P. Balaram[1], CH. Sudha Rani Chowdary[*], K. Satheesh[2], CH. Bindu Kiranmayi[3] and V. Rama Devi[4]
Department of Veterinary Pathology, NTR College of Veterinary Science, Sri Venkateswara Veterinary University, Gannavaram, Andhra Pradesh, India- 521102.
[1]M.V.Sc. Scholar; [2]Professor and Head, Department of Veterinary Pathology, C.V.Sc, Garividi; [3]Associate Professor, Department of Veterinary Public Health, [4]Professor & Head, Dept. of Veterinary Pathology, NTR CVSc, Gannavarm

***Address for correspondence**
CH. Sudha Rani Chowdary, Assistant Professor, E-mail: drsudha84@gmail.com
ORCID ID: 0000-0002-4714-5149

Received: 13.4.26; Accepted: 3.6.26

ABSTRACT

The present study was undertaken to know the occurrence of tumors in canine male reproductive tract and to study the cytology, gross and histopathology and to diagnose the origin of different neoplasms by immunohistochemistry. Tumors of the male genitalia in the present study were observed in the testes and penis. Testicular tumors included germ cell tumors, represented exclusively by seminomas (26.9%), and sex cord-stromal tumors, including Sertoli cell (19.2%) and Leydig cell tumors (7.7%). Seminomas were cytologically characterized by highly cellular smears of pleomorphic round-to-polygonal cells with prominent nucleoli and mitotic figures, while histologically presenting as either intratubular or diffuse patterns. Sertoli cell tumors exhibited moderate to highly cellular, pleomorphic cytology with vacuolated cytoplasm and prominent nucleoli, while histologically presenting as intratubular and diffuse patterns. Leydig cell tumors were characterized cytologically as clusters of polyhedral cells with vacuolated cytoplasm, eccentric nuclei, and prominent nucleoli; histologically, they displayed angiomatoid and sarcomatoid patterns with the presence of lipochrome pigment. Penile tumors exclusively comprised transmissible venereal tumors (46.2%) that were characterized by sheets of round cells with vacuolated cytoplasm and high mitotic index. IHC revealed that all tumors were negative for pancytokeratin and S100. Diffuse immunopositivity for both calretinin and vimentin was observed in seminomas, whereas Leydig cell tumors and TVTs expressed vimentin exclusively. Sertoli cell tumors demonstrated no immunoreactivity to any of the tested antibodies.

Keywords: Canine, Male reproductive tract, Leydig cell tumor, Seminoma, Sertoli cell tumor

INTRODUCTION

Shifting lifestyles and increased pet ownership have rendered dogs more susceptible to various metabolic and infectious diseases, as well as a rising incidence of neoplasms. Although robust vaccination programs have successfully mitigated many infectious threats, the lack of preventive measures for cancer has seen tumors particularly those of cutaneous and reproductive origin become a leading health concern in the canine population[1]. Indeed, genital tract tumors now rank among the most frequently diagnosed malignancies in dogs, surpassed only by skin and mammary tumors[2].

In veterinary clinical practice, tumors of the male genital tract are particularly prevalent among aging, intact populations[3]. These neoplasms primarily target the testes, prostate, and penis or prepuce, each presenting with distinct biological behaviors. For instance, testicular tumors such as Sertoli cell tumors (SCTs), seminomas, and Leydig cell tumors (LCTs) are usually benign, yet they can trigger severe paraneoplastic syndromes like hyperestrogenism. In contrast, prostatic neoplasia, most notably adenocarcinoma, is typically highly aggressive and often diagnosed at an advanced stage, carrying a guarded prognosis regardless of castration status. Furthermore, the canine transmissible venereal tumor (CTVT) represents a unique oncological entity: a physically transmissible clonal cell line affecting the external genitalia[1]. Consequently, a thorough understanding of the histopathological diversity and clinical progression of these various tumors is essential for effective diagnosis and management.

How to cite this article: Balaram, P., Chowdary, S.R., Satheesh, K., Kiranmayi, B. and Rama Devi, V. 2026. Pathomorphological and immunohistochemical studies on male genital tract tumors in dogs. . Indian J. Vet. Pathol., 50(4) : 328-334.

Given the clinical significance and histopathological diversity of these conditions, the present study was conducted to provide a comprehensive analysis of the occurrence of different male genital tract tumors in dogs in and around the Vijayawada region.

MATERIALS AND METHODS

A total of 26 male genital tract tumors were included in the study that were sourced from the Veterinary Clinical Complex

(VCC), NTR College of Veterinary Science, Gannavaram, Super Speciality Veterinary Hospital (SSVH), Animal Birth Control centre and various local private clinics in and around Vijayawada.

Diagnostic samples were obtained by fine-needle aspiration (FNA) and touch impression for cytological evaluation. For histopathological and immunohistochemical analysis, representative excisional biopsies were preserved in 10% neutral buffered formalin. Tissue samples fixed in 10% neutral buffered formalin were processed using standard paraffin embedding techniques. Sections of 4 micron thickness were then cut and stained with Hematoxylin and Eosin (H&E) according to the methods described by Bancroft and Cook[4].

Immunohistochemical staining was performed on 4 micron thick sections mounted on positively charged slides (BioGenex, USA) using a Super Sensitive Polymer-HRP detection system. Following deparaffinization in xylene and rehydration through graded ethanol, antigen retrieval was conducted in 0.01M citrate buffer (pH 6.0) using a pressure cooker for 20 minutes. Endogenous peroxidase activity was quenched with 3% hydrogen peroxide (Peroxide Block™, BioGenex) for 20 minutes, followed by a 10 - minute incubation with Power Block™ (BioGenex) to minimize non-specific binding. Sections were incubated with primary antibodies (Biogenex, USA) including pancytokeratin, vimentin, calretinin and S100 for 60 minutes at room temperature. Signal amplification was achieved using Super Enhancer™ (20 min) and Polymer-HRP reagent (30 min). Immunoreactivity was visualized using 3,3'-Diaminobenzidine (DAB) chromogen. Finally, sections were counterstained with Harris Hematoxylin and mounted with DPX. Negative controls were maintained by omitting the primary antibody.

RESULTS

In this study, 26 out of 411 canine tumor biopsies (6.5%) were identified as male reproductive tract neoplasms involving testes and penis (Table 1). The study did not record any tumors in the prostate gland. The testicular tumors consisted of germ cell tumors (seminoma) and sex-cord stromal tumors (Sertoli and Leydig cell tumors), whereas the penile tumors were exclusively TVTs. Among all the histological types of male reproductive tract tumors, the highest occurrence was observed in the penis, consisting entirely of TVTs at 46.2% followed by seminomas at 26.9% and SCTs at 19.2%. The least frequent histological type recorded was the LCT, which accounted for 7.7% of the total male reproductive tract neoplasms. On immunohistochemistry, none of the tumors revealed positive staining to cytokeratin and S100 antibodies (Table 2).

The pathological features of different histological types of male canine reproductive tract tumors identified in the present study are detailed in separate sections.

Seminoma

In the present study, seminomas were unilateral in a few cases and bilateral in majority of the cases. In all the cases, they were associated with cryptorchidism. On gross examination, the affected testes were irregular in shape, markedly enlarged and measured approximately 4-7 cm in diameter. Cut sections revealed bulging, homogeneous masses that were grayish white to pale cream in colour. The tumor masses exhibited a soft to firm, fleshy consistency and a lobulated appearance (Fig. 1). Cytological smears were highly cellular, featuring discrete round-to-polygonal cells arranged individually or in loose clusters. These cells exhibited indistinct borders, pale-to-basophilic cytoplasm, and large, central nuclei with prominent nucleoli. Significant anisokaryosis and moderate pleomorphism were also observed. On histopathological examination, two different types of seminomas were observed in the present study *viz.* intratubular and diffuse forms. In intratubular seminoma, the seminiferous tubules were filled with proliferating neoplastic germ cells replacing the normal spermatogenic and Sertoli cells. In the diffuse type, the neoplastic cells were arranged in large sheets that infiltrated into the testicular parenchyma. The stroma often showed large infiltrates of lymphocytes. The neoplastic cells were large, round to polyhedral with distinct cell borders and clear to granular eosinophilic to amphophilic cytoplasm. The nuclei were single to multiple, centrally located, round and vesicular with prominent nucleoli. The tumor occasionally exhibited giant cells with abundant cytoplasm

Table 1. Histological classification of male reproductive tract tumors (n=26).

Anatomical Site	Histological Type	Number of cases	Occurrence (%)
Testis	Seminoma (SEM)	7	26.9
	Sertoli cell tumor (SCT)	5	19.2
	Leydig cell tumor (LCT)	2	7.7
Penis	Transmissible Venereal Tumor (TVT)	12	46.2

Table 2. Immunohistochemical characterization of male reproductive tract tumors.

Antibody	SEM	SCT	LCT	TVT
Cytokeratin	-	-	-	-
Vimentin	+	-	+	+
Calretinin	+	-	-	-
S100	-	-	-	-

and mitotic figures. In a few foci atypical mitotic figures appeared as filamentous chromatin, the spiremes. The neoplastic sheets often showed individual necrosis of cells giving the "starry - sky" appearance (Fig.2). In a few cases, tumor emboli were noticed in the vascular spaces.

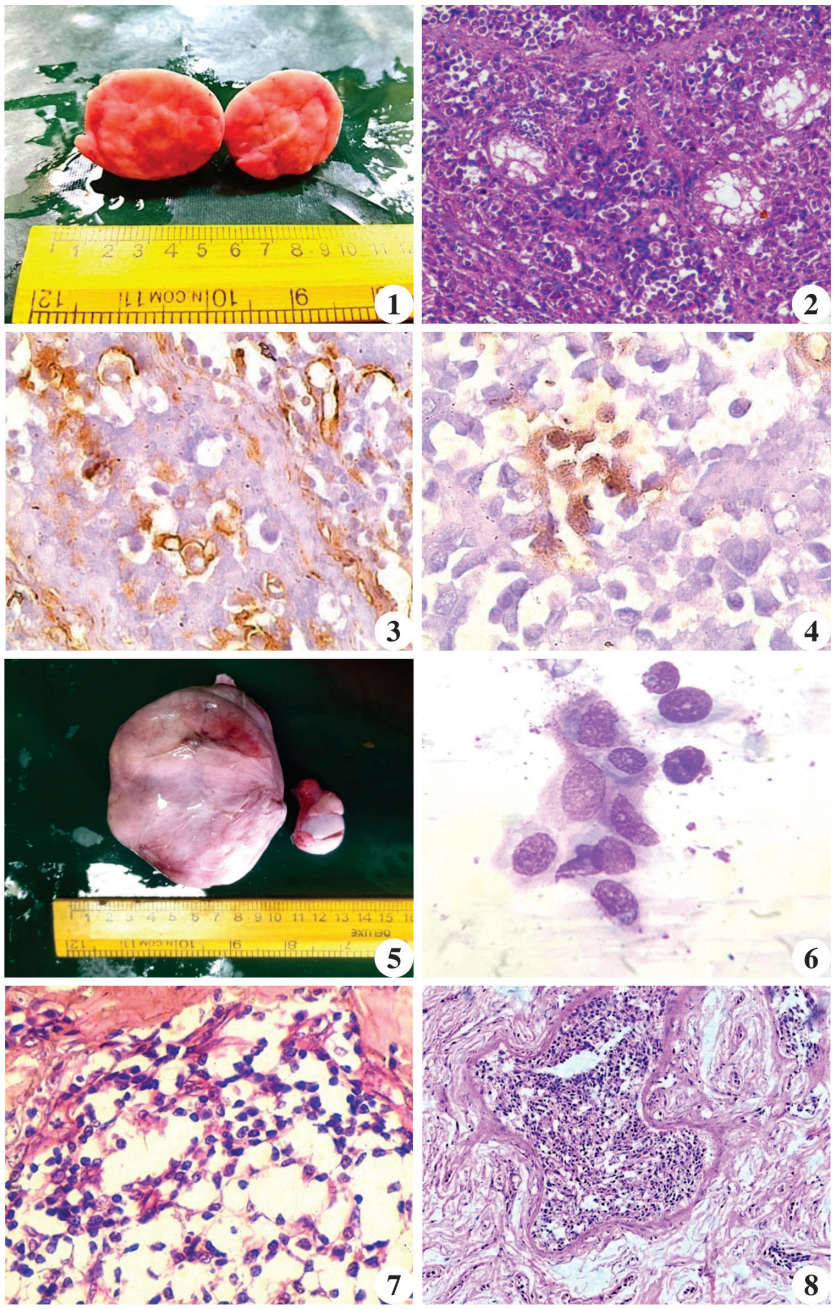

Fig.1. Seminoma - Lobulated, grayish white cut surfaces; **Fig.2.** Diffuse seminoma - Section showing "starry sky appearance" with sheets of neoplastic germ cells. H&E x100; **Fig.3.** Seminoma: IHC, vimentin - Note a moderate to intense cytoplasmic expression in the neoplastic germ cells x400; **Fig.4.** Seminoma: IHC, calretinin - Section showing a focal area of intense cytoplasmic and nuclear expression in the neoplastic cells x400; **Fig.5.** Sertoli cell tumor - Affected testes showing severe enlargement compared to the normal testes; **Fig.6.** Sertoli cell tumor - Cytology showing a cluster of pleomorphic cells with prominent nucleoli. Leishman's stain x1000; **Fig.7.** Intratubular Sertoli cell tumor - Section showing neoplastic cells forming microcystic pattern. H&E x400; **Fig.8.** Intratubular Sertoli cell tumor - Section showing sclerosing pattern with severe hyalinising stroma. H&E x100

On IHC, seminomas revealed moderate cytoplasmic positivity for vimentin (Fig. 3) and multifocal intense cytoplasmic and nuclear positivity for calretinin (Fig. 4).

Sertoli cell tumor

In the present study, SCTs were majorly observed in cryptorchid testes. The tumors were unilateral and the affected testes were enlarged and distorted in shape while the contralateral testes showed severe atrophy (Fig. 5). The tumors measured about 5 - 9 cm in diameter and were firm in consistency. On cut sections, the tumors were lobulated, solid, gray to tan in colour with foci of haemorrhages. Cytological smears of SCTs revealed moderate to high cellularity with moderate pleomorphism, predominantly large and arranged as clusters. The cells were irregular to elongated and polygonal in shape, with indistinct cell borders and a moderate amount of pale to slightly basophilic cytoplasm containing fine vacuoles (Fig. 6). The nuclei were round to oval and generally centrally placed. Nuclear chromatin was finely granular with one or more prominent nucleoli. Histologically, two forms *viz.* intratubular and diffuse patterns were recorded. The intratubular Sertoli cell tumors displayed different architectures that included microcystic, palisading, whorling and sclerosing patterns. In the microcystic pattern, the neoplastic cells formed back to back, small cystic spaces (Fig. 7), while in the palisading pattern, the neoplastic cells were parallel to each other and perpendicular to the seminiferous tubules. In the whorling pattern, the neoplastic cells formed whorls, while in the sclerosing pattern, the neoplastic cells were arranged within the tubules as nests with a huge intertubular hyalinising fibrous connective tissue (Fig.8). The Sertoli cells exhibited moderate degree of pleomorphism and were slender, round to elongated and triangular in shape with pale, eosinophilic to vacuolated cytoplasm and indistinct cell borders. A few cells contained lipochrome granules in the cytoplasm. The nuclei were hyperchromatic, oval to elongated and central to eccentrically located with

finely stippled chromatin. The diffuse form of Sertoli cell tumor was characterized by sheets of small to large, slender to oval and triangular shaped cells with eccentric nuclei and eosinophilic cytoplasm. In a few foci, the tumor cells formed multicellular spheres (Fig. 9), whorls and microcystic structures. The stroma was minimal to moderate and often appeared hyalinised with infiltration of lymphocytes. In a few foci, the tumor parenchyma exhibited necrosis, infiltration of neutrophils and vascular invasion. On IHC, the neoplastic Sertoli cells did not exhibit positivity for any of the antibodies used.

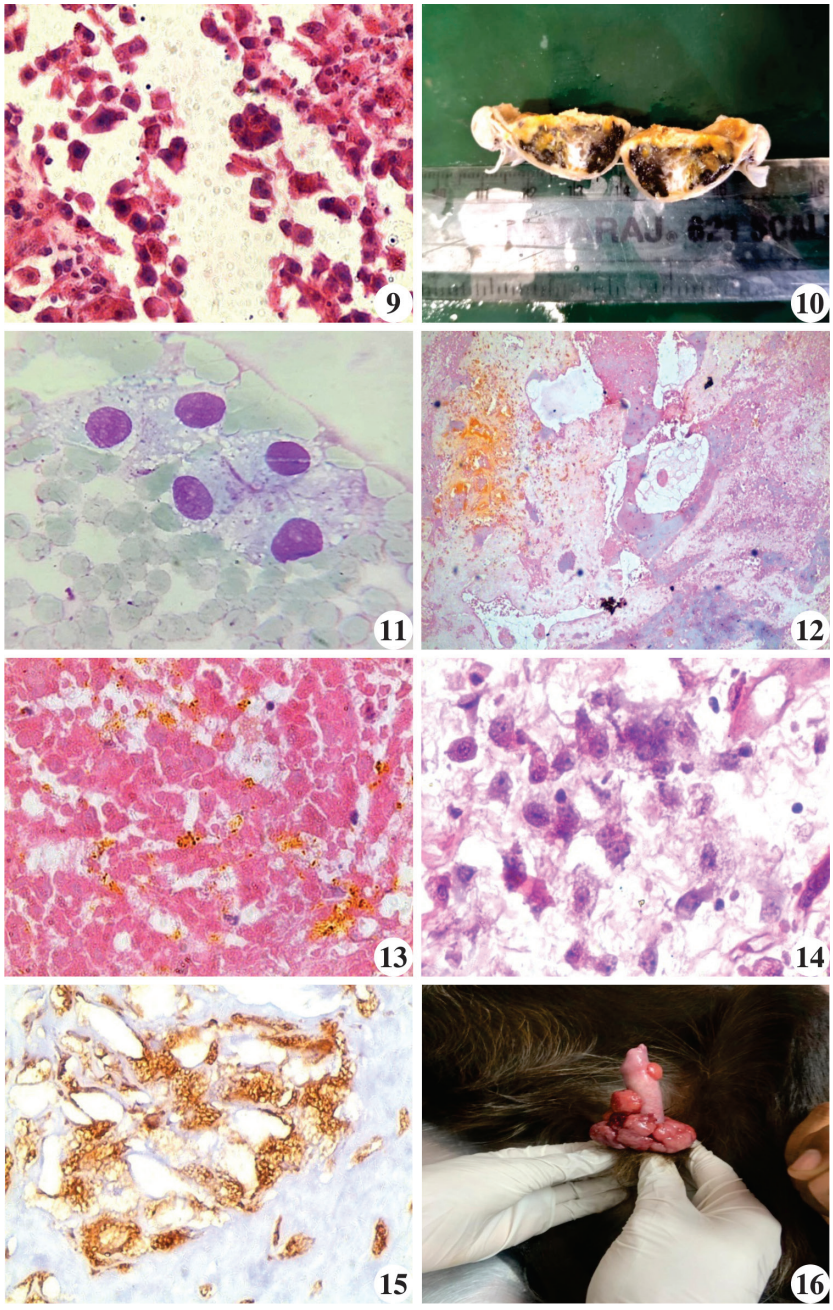

Fig. 9. Diffuse Sertoli cell tumor - Section showing neoplastic multicellular spheres. H&E x400; **Fig. 10.** Leydig cell tumor - Yellowish brown, fleshy cut surfaces showing foci of hemorrhage and necrosis; **Fig. 11.** Leydig cell tumor - An impression smear showing polyhedral cells with eccentric nuclei and vacuolated cytoplasm. Leishman's stain x1000; **Fig. 12.** Angiomatoid Leydig cell tumor - Section showing vascular spaces filled with proteinaceous fluid amidst solid areas of neoplasm. H&E x100; **Fig. 13.** Angiomatoid Leydig cell tumor - Section showing multifocal deposition of golden yellow lipochrome pigment amidst neoplastic Leydig cells. H&E x400; **Fig. 14.** Diffuse Leydig cell tumor - Section showing loose clusters of pleomorphic Leydig cells within a hyalinised stroma. H&E x400; **Fig. 15.** Leydig cell tumor: IHC, vimentin - Note intense cytoplasmic positivity in the neoplastic Leydig cells x400; **Fig. 16.** TVT: Nodular to cauliflower like masses on the entire length of penis.

Leydig cell tumor

LCTs were unilateral and occurred in the scrotal testes. Grossly, the tumors distorted the shape and size of the affected testes. The tumors measured about 3 - 5 cm in diameter and were irregular in shape. On sectioning, the tumors were solid and firm, golden brown to dark in colour. The cut surfaces were fleshy with focal areas of necrosis, hemorrhage and displayed multiple cystic spaces (Fig. 10). Cytological smears revealed presence of loose clusters of polyhedral cells with finely vacuolated to granular cytoplasm. The nuclei were eccentrically placed exhibiting coarse chromatin and prominent nucleoli (Fig. 11). Histologically, two types of LCTs were observed in the present study that included an angiomatoid and a diffuse type. The angiomatoid LCT was characterized by the presence of large vascular spaces filled with erythrocytes and proteinaceous fluid amidst nests and cords of neoplastic cells (Fig. 12). The neoplastic Leydig cells were large, round to polyhedral in shape with an abundant eosinophilic cytoplasm and central to eccentrically placed nuclei. The tumor also displayed abundant sclerosing stroma and multifocal deposition of golden yellow lipochrome pigment (Fig. 13) that was negative for Perl's stain. In the diffuse type of LCT, the neoplastic cells were arranged in loose clusters separated by abundant hyalinised matrix (Fig. 14), while in a few foci, they assumed sarcomatoid architecture. In those foci with clusters, the cells were large, pleomorphic, oval to polyhedral in shape with vacuolated to granular cytoplasm. The nuclei were large, vesicular, central to eccentric with a single, small, basophilic nucleolus. In those foci with sarcomatoid

architecture, the cells were elongated to fusiform and arranged in bundles, with an abundant eosinophilic cytoplasm, vesicular nuclei containing multiple nucleoli and indistinct cell borders. Occasionally, the cells contained lipochrome pigment. On immunohistochemistry, LCTs demonstrated intense cytoplasmic positivity to vimentin (Fig. 15).

Transmissible venereal tumor (TVT)

TVTs were recorded on the external genitalia of males. Grossly, tumors were multiple, nodular and fleshy. They occurred on the entire length of the penis in male dogs (Fig.16) and at the base of the penis, the tumors were larger and multinodular to cauliflower in shape.

Impression smears exhibited two cell types: lymphocytoid cells (Fig. 17), which were round to polyhedral with a high nuclear-to-cytoplasmic ratio, scant vacuolated cytoplasm, and prominent nucleoli, and plasmacytoid cells (Fig. 18), which were oval with abundant vacuolated cytoplasm and an eccentrically placed hyperchromatic nucleus. Mitotic figures are frequently seen in both patterns. Histopathologically, the tumor showed densely packed round to polyhedral cells in sheets with delicate fibrovascular stroma. Cells exhibited eccentric nuclei with prominent nucleoli, frequent mitoses (Fig. 19), vacuolated cytoplasm, and focal hemorrhage and necrosis. IHC showed diffuse mild to moderate cytoplasmic vimentin positivity in the tumor cells (Fig. 20).

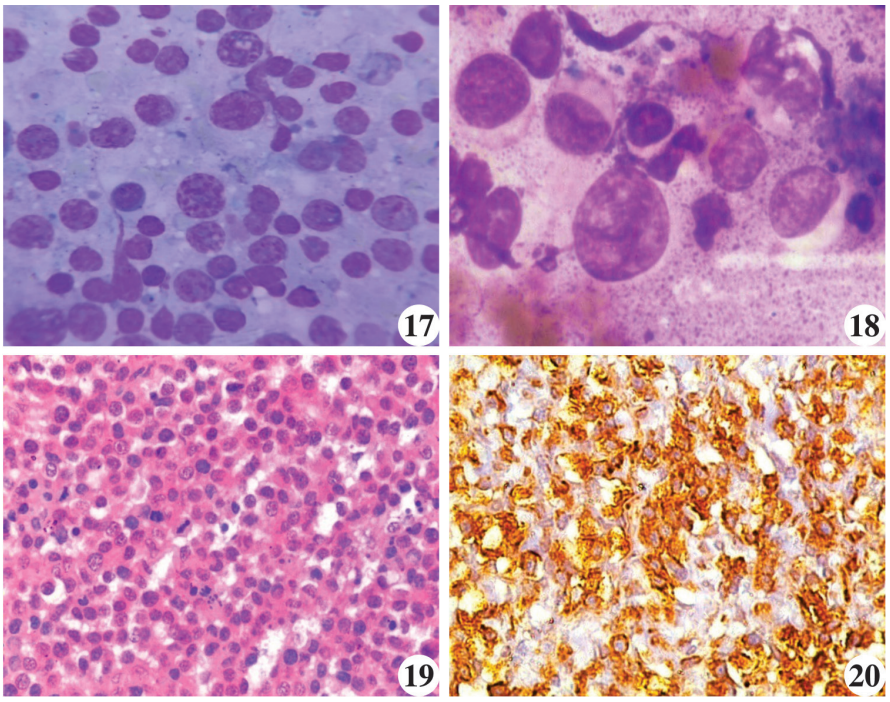

Fig. 17. TVT: An impression smear showing pleomorphic, round to oval cells with coarse chromatin and cytoplasmic vacuolation. Leishman's stain x1000; **Fig. 18.** TVT: an impression smear showing anisocytic plasmacytoid cells with eccentric nuclei. Leishman's stain x1000; **Fig.19.** TVT: Section showing sheets of round cells with mitotic figures. H&E x400; **Fig. 20.** TVT: IHC, vimentin - Section showing strong cytoplasmic immunostaining x400

DISCUSSION

In the present study, tumors were observed affecting the testes and penis of the male genital tract in dogs. The susceptibility of testes to tumors in geriatric, intact dogs, is exacerbated by conditions such as cryptorchidism, which increases the likelihood of tumor development by 9 to 14-fold[5]. The present study did not record prostatic tumors, although earlier reports[6,7] have documented prostatic tumors, that typically represented less than 1% of all canine neoplasms and roughly 5% of all prostatic diseases. In the present study, the sample size was smaller and could be one of the reasons for absence of prostatic tumors. Furthermore, because prostatic tumors are often internal and present with non-specific clinical signs, they may be unnoticed by the owners and may not be presented for diagnosis.

In the present study, testicular neoplasms consisted of seminomas (26.9%), followed by SCTs and LCTs. While the findings in the present study are in accordance with that of earlier reports[8,9] in identifying seminoma as the most frequent type, they contrast with that of a few studies[10,11,12] that reported a higher prevalence of Leydig cell tumors. Additionally, rare types like mixed germ cell-sex cord stromal tumors and hemangiosarcomas, noted by earlier authors[8,13], were not observed in this study.

The gross and microscopic morphology of seminomas in the present study aligns with the findings of previous reports. Key microscopic features, such as lymphocytic infiltration, "starry sky" patterns, and high mitotic indices, were consistent with established literature[14]. Although canine seminomas typically exhibit low metastatic potential, the vascular invasion observed in diffuse seminoma in the present study serves as a significant prognostic indicator of malignancy.

The majority of SCTs in this study were found in cryptorchid testes consistent with earlier reports[15, 16]. Cytologically, the tall columnar to polygonal cells with vacuolated cytoplasm mirrored features described by earlier finding[17]. Histologically, both intratubular and diffuse forms exhibited severe desmoplasia and stromal

hyalinization, highlighting the dynamic interaction between tumor cells and connective tissue[18]. In the present study, an interesting finding in diffuse SCTs was the presence of multicellular spheres. Because the diffuse type also demonstrated vascular invasion, these spheres may play a critical role in vascular invasion and metastasis.

LCTs in this study presented as solid, golden-brown scrotal masses, consistent with the earlier findings[19]. Cytological analysis showed dyscohesive, vacuolated cells, while histology revealed angiomatoid and diffuse sarcomatoid patterns. Angiomatoid type of Leydig cell tumor has been rarely reported in the literature. The characteristic golden-yellow lipochrome pigment observed in the neoplastic Leydig cells reflects intense steroidogenesis and lipid peroxidation[20].

TVTs represented the most common male canine genital neoplasm in this study. This high occurrence is likely attributed to the sample source, an Animal Birth Control centre handling free-roaming street dogs. The unrestricted sexual behaviour of these free-range dogs facilitates the transmission of TVTs, thereby elevating their occurrence in the study. The gross, cytological and histopathological findings of canine TVTs in the present study are consistent with previous reports[21,22,23].

Despite existing studies on canine testicular tumor markers, the relatively sparse data available presently hinders their implementation as diagnostic tools[24]. In the present study, to characterize the tumors, a panel of antibodies including pancytokeratin, vimentin, S100 and calretinin were utilized for immunohistochemical analysis. All evaluated tumors in this study lacked pancytokeratin and S100 expression, ruling out an epithelial or neuroectodermal origin. Regarding calretinin, seminomas in the present study demonstrated multifocal positivity, whereas Leydig and Sertoli cell tumors showed no expression. As calretinin expression is typically observed in steroid-hormone-producing cells, this protein has been postulated as a marker for the secretory activity of testicular tumors[25]. Radi and Miller[26] documented variable calretinin expression across all canine testicular tumor types, which contrasts sharply with human studies, where LCTs are the sole testicular neoplasms expressing this protein[25]. However, the usefulness of calretinin for diagnosis is limited because its expression is not consistent in all cases[27].

In this study, vimentin expression was recorded in seminomas, LCTs and TVTs. Although traditionally a marker of mesenchymal origin, as confirmed by the intense immunolabeling in our LCT and TVT cases, vimentin is also a hallmark of epithelial-mesenchymal transition (EMT), which promotes tumor invasion and metastasis. Our findings partially align with an earlier study[28] that observed vimentin expression across all three tumor types and noted that its overexpression contributes to localized canine testicular tumor invasion

In conclusion, the present study revealed gross, cytological, histopathological and immunohistochemical features of canine male reproductive tract tumors in the study area.

Financial support & sponsorship*:* None

Conflict of interest : None

Use of artificial intelligence (AI)-assisted technology for manuscript preparation: The authors confirm that there was no use of AI-assisted technology for assisting in the writing of the manuscript and no images were manipulated using AI.

REFERENCES

1. Brodzki P, Wolniaczyk K, Głodkowska K and Brodzki N. 2023. Tumors of the reproductive system of bitches based on the description of selected own clinical cases and literature data. *Med Weter 79***(7)**: 334–344.
2. Baioni E, Scanziani E, Vincenti M C, Leschiera M, Bozzetta E, Pezzolato M and Ru G. 2017. Estimating canine cancer incidence: findings from a population-based tumour registry in northwestern Italy. *BMC Veterinary Research* **13(1)**: 203.
3. Valli VE, Bienzle D and Meuten DJ. 2017. Tumors of the hemolayphatic system. In: Meuten DJ, eds. Tumors in domestic animals, NC, USA: John Wiley & Sons, Inc. 203-295.
4. Bancroft DJ and Cook CH. 1994. Fundamentals of normal histology and histopathology. In: Manual of histopathological techniques and their diagnostic application, Edinburgh: Churchill Livingstone: 1-17.
5. Ciaputa R, Nowak M, Kiełbowicz M, Antończyk A, Błasiak K and Madej J A. 2012. Seminoma, sertolioma, and leydigoma in dogs: clinical and morphological correlations. *Bull Vet Inst Pulawy* **56(3)**: 361-367.
6. Leroy B E and Northrup N. 2009. Prostate cancer in dogs: comparative and clinical aspects. *Vet J* **180(2)**: 149-162.
7. Vasilatis D M and Ghosh P M. 2024. Clinicopathologic characterization of prostatic cancer in dogs. *Animals* **14(4)**: 588.
8. Catoi C, Moussa R, Bolfa P, Taulescu M and Negrea O 2008. Morphological study of testicular tumors in dogs. *Lucr Şt Med Vet* **41**:100-105.
9. Svara T, Gombac M, Pogorevc E, Plavec T, Zrimsek P and Pogačnik, M. 2014. A retrospective study of canine testicular tumours in Slovenia. *Slov Vet Res* **51(2)**: 81-88.
10. Nielsen S W and Lein D H. 1974. Tumours of the testis. *Bull World Health Organ* **50(1-2)**: 71-78.
11. Manuali E, Forte C, Porcellato I, Brachelente C, Sforna M, Pavone S and Mechelli L. 2020. A five-year cohort study on testicular tumors from a population-based canine cancer registry in central Italy (Umbria). *Prev Vet Med* **185:** 105201.
12. Gazin A A, Vatnikov Y A, Sturov N V, Kulikov E V, Grishin V, Krotova E A and Lisitskaya K V. 2022. Canine testicular tumors: An 11-year retrospective study of 358 cases in Moscow Region, Russia. *Vet World* **15(2)**: 483.
13. Liao A T, Chu P Y, Yeh L S, Lin C T and Liu C H. 2009. A 12-year retrospective study of canine testicular tumors. *J Vet Med Sci* **71(7)**: 919-923.
14. Ramesh S, Vijayendran V, Balakumar A and Kumar V. 2025. Cytological diagnosis of seminoma in dog. *Indian J Vet*

Pathol **49(3)**: 250-253.
15. Masserdotti C, Bonfanti U, De Lorenzi D, Tranquillo M and Zanetti O. 2005. Cytologic features of testicular tumours in dog. *J Vet Med A* **52(7)**: 339-346.
16. Chang A, Lee P, Smith J and Yang K 2022. Cytologic and histopathologic features of an extratesticular Sertoli cell tumor with Call-Exner-like bodies in a castrated dog. *J. Vet Diagn Invest 34***(3)**: 123–129.
17. Silva G M, De Oliveira IC, De Toledo RS, Bezerril J E, Vasques G M B, Gasser B and Romani I. 2021. Seminoma and sertolioma in non-cryptorchid dog–case report. *Acta Vet Bras* **15(4)**: 296-300.
18. Finazzi M and Cammarata G. 1981. Histopathologic observations on Sertoli cell tumors in dog. *Tumori*, **67(5)**: 391–398.
19. Kudo T, Kamiie J, Aihara N, Doi M, Sumi A, Omachi T, and Shirota K. 2019. Malignant Leydig cell tumor in dogs: two cases and a review of the literature. *J Vet Diagn Invest* **31(4)**: 557-561.
20. Handa U, Sood T, Punia R S. 2010.Testicular Leydig cell tumor diagnosed on fine needle aspiration. *Diagn Cytopathol* **38(9)**: 682–684.
21. Ajayi O L, Oluwabi M, Ajadi R A, Antia R E, Omotainse S O, Jubril A J, and Makinde A F. 2018. Cytomorphological, histopathological and immunohistochemical observations on the histiocytic origin of canine transmissible venereal tumour. *Sokoto J Vet Sci* **16(2)**: 10-20.
22. Thangathurai R, Balasubramaniam G A, Dharmaceelan S, Balachandran P, Srinivasan P, Sivaseelan S and Manohar B M. 2008. Cytological diagnosis and its histological correlation in canine transmissible venereal tumour. *Vet Arh* **78(5):** 369–376.
23. Ucar M. 2016. Transmissible venereal tumor: a review. *Kocatepe Vet J* **9(3):** 230-235.
24. Yu C H, Hwang D N, Yhee JY, Kim JH, Im K S, Nho W G and Sur J H. 2009. Comparative immunohistochemical characterization of canine seminomas and Sertoli cell tumors. *J Vet Sci* **10(1):** 1-7
25. Ciaputa R, Nowak M, Madej JA, Poradowski D, Janus I, Dziegiel P and Kandefer-Gol, M. 2014. Inhibin-α, E-cadherin, calretinin and Ki-67 antigen in the immunohistochemical evaluation of canine and human testicular neoplasms. *Folia Histochemica et Ccytobiologica* **52(4):** 326-334.
26. Radi ZA and Miller D L.2005. Immunohistochemical expression of calretinin in canine testicular tumours and normal canine testicular tissue. *Res Vet Sci* **79(2):** 125-129.
27. OwstonMA, and Ramos-Vara JA 2007. Histologic and immunohistochemical characterization of a testicular mixed germ cell sex cord-stromal tumor and a leydig cell tumor in a dog. *Vet Pathol*, **44(6)**: 936-943.
28. de BarrosM D, Dos Santos Batista B P, Amaral C B, da Silva Leite J and Ferreira A M R. 2025. Vimentin expression in canine testicular tumors: a local invasion predictive biomarker. *Biotechnic & Histochemistry* **100(4):** 208-215.