Indian J. Vet. Pathol., 50(4) : 339-347, 2026: DOI: https://doi.org/10.56093/248w0v24

RESEARCH ARTICLE

Mitigating effects of *Moringa oleifera* leaf extract on fipronil-induced hematobiochemical alterations in female Wistar albino rats

J. Leela Prasad, K. Sujatha[1*], A. Anand Kumar, Y. Muralidhar[2] and T.V. Chaitanya Kumar[3]
Department of Veterinary Pathology, College of Veterinary Science, Sri Venkateswara Veterinary University, Tirupati-517 502, Andhra Pradesh, India
[1]Centre for Continuing Veterinary Education and Communication, SVVU, Tirupati
[2]Department of Veterinary Pharmacology and Toxicology, CVSc, Tirupati
[3]Department of Veterinary Biochemistry, CVSc, Tirupati

***Address for correspondence**
Dr. K. Sujathal, Professor & Coordinator, CCVEC, E-mail: karamalasujatha@gmail.com
ORCID ID: 0009-0004-4583-2094, 0000-0002-5082-9365

Received: 14.4.26; Accepted: 3.6.26

ABSTRACT

The present study was conducted to evaluate the ameliorative potential of *Moringa oleifera* leaf extract against the fipronil-induced hematobiochemical alterations in female Wistar albino rats. Twenty four female Wistar albino rats were weighed individually and randomly divided into four experimental groups containing 6 rats each group. Fipronil was administered orally at a dose rate of 10 mg.kg^{-1}.bwt dissolved in corn oil to the Group II rats, and *Moringa oleifera* leaf extract at a dose of 250 mg.kg^{-1}.bwt was given orally along with fipronil to the Group IV rats for a period of 45 days. Group I was considered the vehicle control group, whereas Group III served as the *Moringa oleifera* control. Blood was collected at fortnight intervals, and the haematological indices like Hb, TEC, PCV, TLC, lymphocyte count and neutrophil count were estimated; serum was separated, and biochemical indices like ALT, AST, BUN, CRE, TP, and ALB were estimated. A significant decrease in Hb, TEC, PCV, TLC, and *percent* lymphocyte count and a significant increase in *percent* neutrophil count were observed in fipronil-treated rats. A significant increase in ALT, AST, BUN, CRE, and a significant decrease in TP and ALB were observed in fipronil-treated rats. However, a significant improvement was noticed in the *Moringa oleifera*-ameliorated rats, suggesting its protective potential against fipronil-induced toxicity.

Keywords: Fipronil toxicity, hematobiochemical alterations, *Moringa oleifera*, Female Wistar albino rats

INTRODUCTION

Pesticides are chemical agents that are used to protect crops from the organisms that establish a parasitic association with plants. Any organism that derives nutrients from, lives in, or on a plant, thereby damaging the crop yield, is called a pest. Of all the pests, insects account for 18%- 20% of the global crop loss annually and are responsible for a 15%-20% loss of vegetable production[1]. Pest control is one of the effective methods that helps to meet the escalating demand for food production by the growing population. But the irresponsible use of insecticides may eventually harm humans and animals by entering the food chain.

Fipronil is one such chemical having a broad spectrum of insecticidal activity, even in insects that have developed resistance to classical insecticides[2]. This organic compound having a pyrazole ring attached to a phenyl group, acts by blocking the gamma-aminobutyric acid (GABA)-gated chloride channels, resulting in excessive neuronal firing in the insects, leading to prolonged muscular contractions, which eventually cause paralysis and ultimately lead to the death of the insect. Its selective neurotoxic activity against insects over mammals is one of the reasons why it is widely used as an insecticide in agricultural fields and as an ectoparasiticide in veterinary medicine.

In a multi-centre study to determine the pesticide residues in the milk in peri-urban locations[3] reported that the estimated daily intake of fipronil was higher than the acceptable daily intake in children in some areas. Though fipronil shows selectivity towards insects, its chronic intake may impair metabolism even in mammals. Previous studies postulated that prolonged exposure to fipronil may cause neurotoxic, hepatotoxic, nephrotoxic, and reproductive toxic effects in mammals[4].

How to cite this article: Prasad, J.L., Sujatha, K., Kumar, A.A., Muralidhar, Y. and Kumar, T.V.C. 2026. Mitigating effects of *Moringa oleifera* leaf extract on fipronil-induced hematobiochemical alterations in female Wistar albino rats. Indian J. Vet. Pathol., 50(4) : 339-347.

In recent times, there's a shift in attention towards the pharmaceutical value of dietary plants and vegetables, due to the growing awareness among people that vegetables not only have nutritional benefits but also therapeutic properties. *Moringa oleifera* is a plant that has gained widespread attention for its therapeutic significance. Commonly called as Drumstick tree and often termed as miracle tree, as almost every part of the plant has medicinal value. Over the last decade, a consistent

number of studies have demonstrated the antioxidant potential of the plant, attributed to its rich concentrations of phenolic and flavonoid compounds. *Moringa oleifera* leaves are rich in antioxidants such as quercetin, kaempferol, and polyphenols[5], which can neutralize free radicals, decrease lipid peroxidation, and inhibit inflammatory pathways, and have demonstrated protective effects in various organs, such as liver, kidney, and reproductive tissues, and have also been shown to improve haemato-biochemical parameters[6]. Nevertheless, the ameliorating potential of *Moringa oleifera* against fipronil-induced haematological disturbances has not been sufficiently studied.

Therefore, the present study aims to investigate the effect of fipronil on haematological indices and amelioration with *Moringa oleifera* under experimental conditions.

MATERIALS AND METHODS

Procurement of lab animals, fipronil and *Moringa oleifera* leaf extract

A total of 24 female Wistar albino rats of eight to ten weeks old were procured from Kedhar Biolabs, Mahabubnagar, Telangana. Before the experiment, the rats were acclimatized to the laboratory conditions for a period of 14 days. Animals were housed in polypropylene cages and maintained at $25^0C \pm 1^0$ C with a 12-12 hour light/dark cycle throughout the 45-day experimental period. Standard hygienic and animal care protocols were followed based on the Committee for Control and Supervision of Experiments on Animals (CCSEA) guidelines[7] and were given access to *ad libitum* feed and water. The experiment was conducted only after obtaining the Institutional Animal Ethics Committee (IAEC) approval (Approval No. (281/ go/ ReBi/ S/ 2000/ CPCSEA/ CVSC/ TPTY/ 066/ Veterinary Pathology/ 2025 dated: 02.08.2025). The technical grade of fipronil (99% pure; B.no: FIP92B7055) was procured from Gharda Chemicals Ltd., Mumbai. Corn Oil (CAS No.: 8001-30-7) from Central Drug House (P) Ltd., New Delhi, and *Moringa oleifera* leaf extract (Product no: LC25060145) from Chemiloids Life Sciences Pvt Ltd., Vijayawada, Andhra Pradesh.

Study design

A total of 24 female Wistar albino rats of eight to ten weeks old were individually weighed and subsequently arranged into 4 experimental groups, containing six rats each, using a stratified randomization method to minimize variability. Corn oil was used as a vehicle for administering fipronil, as it is having lipophilic nature and a solubility of about >10,000 mg/L[8]. Fipronil and *Moringa oleifera* leaf extract were administered orally for 6 weeks. The dose of fipronil was selected as $1/10^{th}$ of its LD_{50}, that is 10 mg kg^{-1} bwt, while the dose of *Moringa oleifera* was adopted based on previously reported studies[9], where it had shown a protective effect in female rats, that is 250 mg kg^{-1} bwt. Rats in Group I served as vehicle control group, and were offered feed and water *ad libitum*. Rats in Group II were administered fipronil orally at a dose rate of 10 $mg.kg^{-1}$.b.wt for 6 weeks, with corn oil serving as vehicle. Rats in Group III were treated with *Moringa oleifera* leaf extract orally at a dose rate of 250 mg kg^{-1} bwt, and rats in Group IV were treated with fipronil along with *Moringa oleifera* leaf extract at the dose rates of 10 mg kg^{-1} bwt and 250 mg kg^{-1} bwt, respectively. Pooled blood samples were collected at fortnightly intervals from all experimental groups for haematological analysis. The animals were maintained for a period of six weeks and were sacrificed at the end of the experimental period.

Haematology

Pooled blood samples were collected in EDTA-coated vials at fortnightly intervals from all the experimental groups for haematological analysis, including Total Erythrocyte Count (TEC) and Total Leucocyte Count (TLC) estimated by the dilution method[10], haemoglobin estimation by Sahli's method[11] and Packed Cell Volume (PCV) assessed by the Micro haematocrit method[10]. Blood smears were immediately prepared and stained with Field's stain, then analysed for a differential leucocyte count using the Battlement method[10].

Serum biochemistry

At fortnight intervals, blood was collected in clot activator-coated vials and allowed to clot. After clotting, the sample was centrifuged at 4000 rpm for 15 minutes, and the serum was separated. The separated serum was used to estimate Alanine Aminotransferase (ALT), Aspartate Aminotransferase (AST), Total protein (TP), Albumin (ALB), Blood Urea Nitrogen (BUN) and serum creatinine (CRE) levels. All the serum markers were estimated using Biosystems commercial diagnostic kits.

Statistical analysis

The haemato-biochemical parameters were subjected to One-way ANOVA in accordance with[12] using Statistical Package for the Social Sciences (SPSS) version 20 for statistical analysis.

RESULTS

Total erythrocyte count (TEC) (millions/µl)

The mean and S.E values of TEC (millions/µl) in rats of different experimental groups, Group I to IV, were 7.67 ± 0.17^{b}, 6.69 ± 0.89^{a}, 8.49 ± 0.17^{c}, and 8.12 ± 0.99^{bc} respectively, and are shown in Fig.1. A significant ($p<0.05$) decrease in mean TEC was observed in fipronil-treated rats (Group II) when compared to the control rats (Group I). The *Moringa oleifera*-ameliorated rats (Group IV) showed a statistically significant increase in mean TEC compared with the fipronil rats (Group II).

Likewise, there was no significant difference between *Moringa oleifera*-treated rats (Group III) and *Moringa oleifera*-ameliorated rats (Group IV).

Haemoglobin (Hb) (gm%)

The mean and S.E values of haemoglobin (gram%) of rats in different experimental groups, Group I to IV, were 13.94 ± 1.03^{b}, 10.30 ± 0.46^{a}, 15.73 ± 1.17^{b}, and 15.07 ± 0.76^{b}, respectively, and are shown in Fig.2. A significant reduction ($p< 0.05$) in mean haemoglobin levels was observed in fipronil-treated rats (Group II) compared to the control rats (Group I). The *Moringa oleifera* ameliorated rats (Group IV) showed improvement in mean Hb concentration when compared with fipronil-treated rats (Group II), and no significant difference was observed between the control rats (Group I) and *Moringa oleifera*-treated rats (Group III).

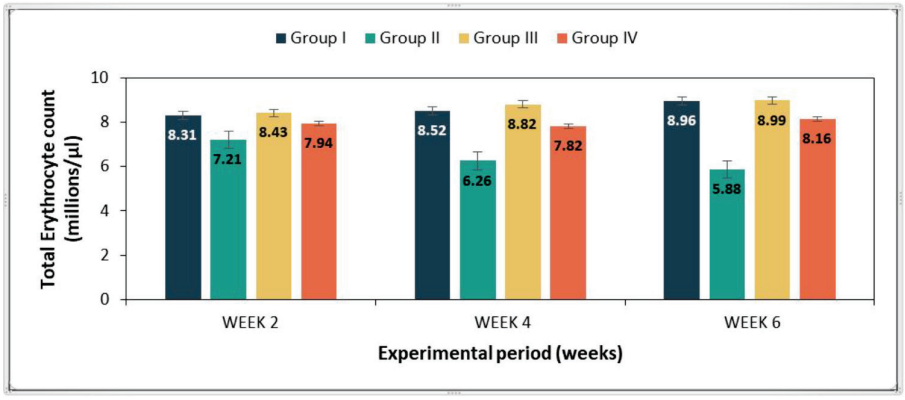

Fig.1. Mean values of TEC (millions/µl) in rats of different experimental groups

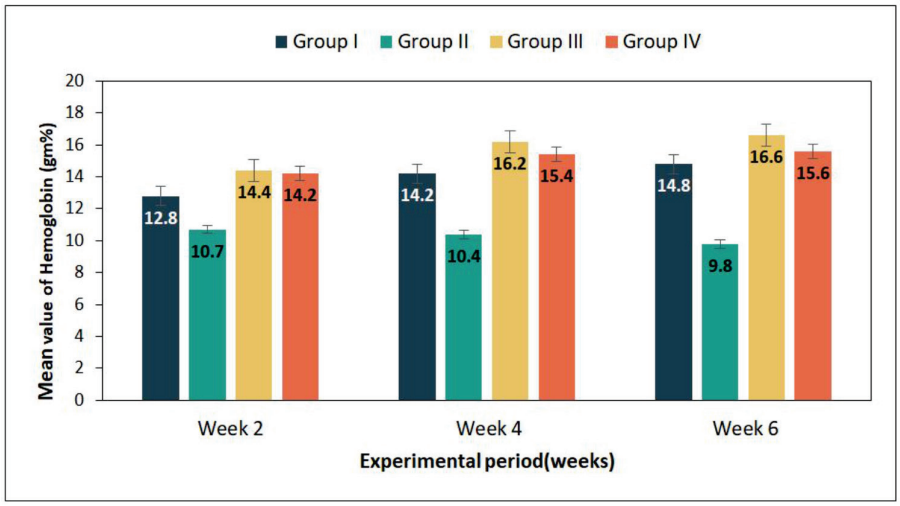

Fig.2. Mean values of haemoglobin (gm%) in rats of different experimental groups

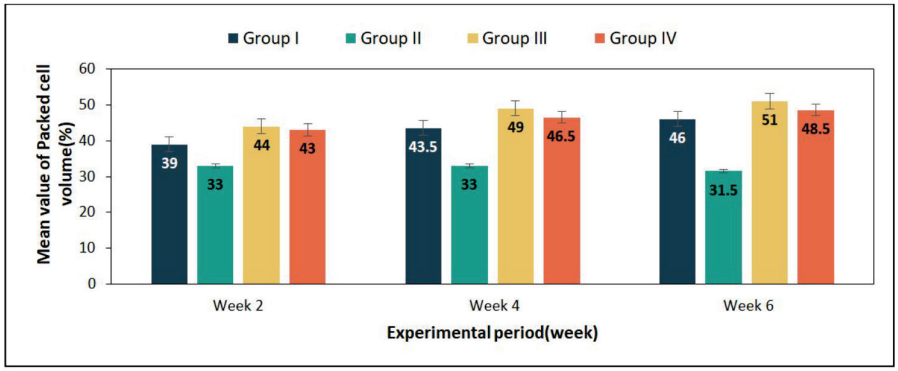

Fig.3. Mean values of PCV (%) in rats of different experimental groups

Packed cell volume (PCV) (%)

The recorded mean and S.E values of PCV (%) of rats in different groups, Group I to IV were 42.83 ± 2.05^{b}, 32.5 ± 0.5^{a}, 48 ± 2.08^{b}, and 46 ± 1.60^{b}, respectively, and are shown in Fig.3. A significant decrease ($P< 0.05$) in the mean PCV values was observed in fipronil-treated rats (Group II) when compared to the control rats (Group I). The rats treated with fipronil and *Moringa oleifera* (Group IV) showed improvement in mean PCV values when compared with fipronil-treated rats (Group II), and no significant difference was observed between the control rats (Group I) and *Moringa oleifera*-treated rats (Group III).

Total leucocyte count (TLC) (Thousands/µl)

The mean and S.E values of Total Leukocyte Count (Thousands/µl) in rats of experimental groups, Group I to IV were 8.08 ± 0.1^{b}, 6.97 ± 0.44^{a}, 8.47 ± 0.04^{b}, and 8.20 ± 0.05^{b}, respectively, and are presented in Fig.4. In fipronil-treated rats (Group II), the TLC values were significantly decreased ($P< 0.05$) than control (Group I). There was a significant ($P<0.05$) increase in TLC values in *Moringa oleifera*-treated rats (Group III) and *Moringa oleifera*-ameliorated rats (Group IV) when compared to the fipronil-treated rats (Group II).

Percent neutrophil count (%)

The mean and S.E values of percent neutrophil count (%) in rats of different experimental groups, Group I to IV, were 16.57 ±

0.82[a], 26.96 ± 0.84[b], 15.14 ± 2.14[a], and 15.76 ± 2.96[a], respectively, and are given in Fig. 5. There was a significant ($p<0.05$) increase in the percent neutrophil count in fipronil-treated rats (Group II) compared to the control rats (Group I). No significant difference was observed between the control and *Moringa oleifera*-treated rats (Group III). A significant ($p<0.05$) reduction in percent neutrophil count was noticed in *Moringa oleifera*-ameliorated rats (Group IV) compared to fipronil-treated rats (Group II).

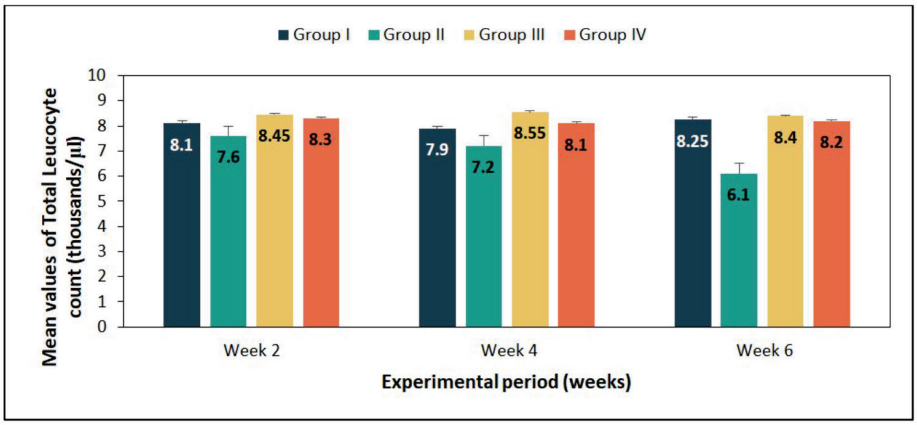

Fig.4. Mean values of TLC (Thousands/µl) in rats of different experimental groups

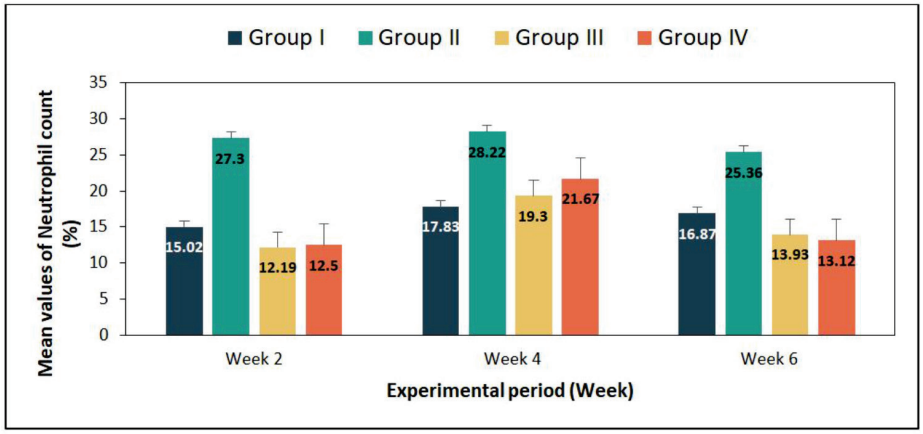

Fig.5. Mean values of Percent neutrophil count (%) in rats of different experimental groups

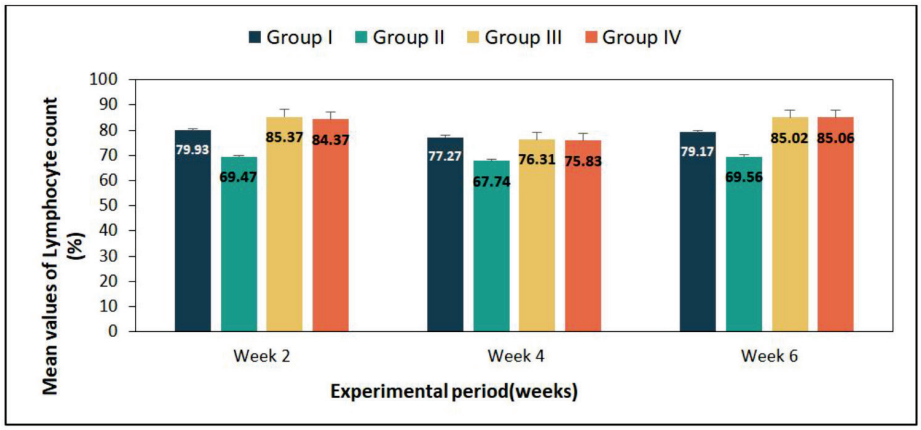

Fig.6. Mean values of percent lymphocyte count (%) in rats of different experimental groups

Percent lymphocyte Count (PLC) (%)

The mean and S.E values of percent lymphocyte count (%) in rats of different experimental groups, Group I to IV were 78.79 ± 0.79[b], 68.92 ± 0.59[a], 82.23 ± 2.96[b], and 81.76 ± 2.97[b], respectively, are given in Fig.6. There was a significant ($p<0.05$) decrease in the percent lymphocyte count in fipronil-treated group (Group II) rats compared to the control rats (Group I). A significant ($p<0.05$) increase in percent lymphocyte count was noticed in *Moringa oleifera*-ameliorated rats (Group IV) compared to fipronil-treated rats (Group II). No significant difference was noticed between the control rats (Group I) and *Moringa oleifera*-treated rats (Group III).

Biochemical profile

Alanine aminotransferase (ALT) (IU/L)

The mean and S.E values of ALT (IU/L) of rats in different groups, Group I to IV, were 44.97 ± 2.02[a], 83.86 ± 6.68[b], 51.75 ± 1.56[a], and 57.67 ± 4.47[a], respectively, and are given in Fig 7. In comparison to control rats (Group I), fipronil-treated rats (Group II) showed a statistically significant ($p < 0.05$) elevation in mean ALT levels. Serum ALT values in *Moringa oleifera* ameliorated rats (Group IV) were significantly ($p < 0.05$) decreased when compared to the fipronil-treated rats (Group II). Meanwhile, no significant difference was noticed in the values of *Moringa oleifera*-treated rats (Group III) compared to control rats (Group I).

Aspartate aminotransferase (AST) (IU/L)

The mean and S.E values of AST (IU/L) of rats in different groups, Group 1 to IV were 105.2±1.63[a], 193.1±14.1[c], 123.57±5.84[ab], and 142.83±4.90[b], respectively, and are given in

Fig.8. There was a significant ($p < 0.05$) increase in mean AST levels in fipronil-treated rats (Group II) when compared to the control rats (Group I). A significant decrease in mean serum AST values was noticed in *Moringa oleifera* ameliorated rats (Group IV) than the fipronil-treated rats (Group II). Although a significant increase ($p < 0.05$) in the mean value was observed in Group IV compared to the control (Group I), this is within the physiological range. No significant difference was noticed in the values of *Moringa oleifera-treated* rats (Group III) compared to control rats (Group I) and the ameliorated rats (Group IV).

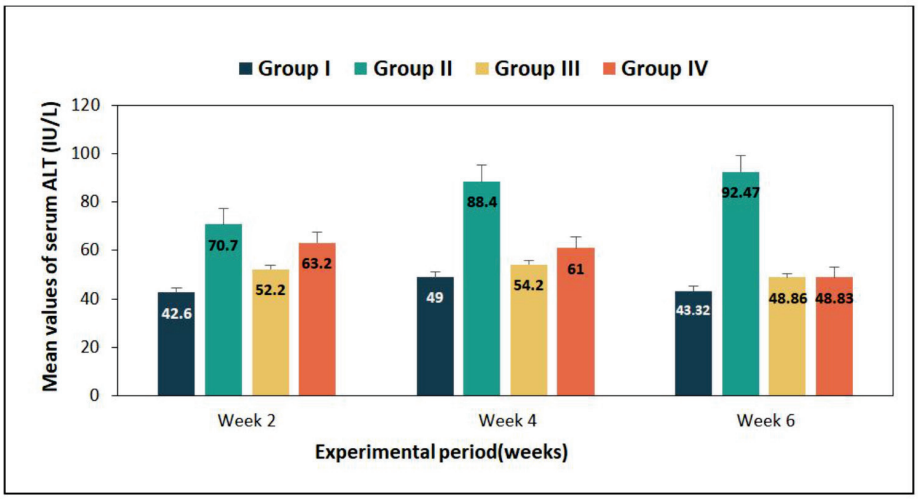

Fig.7. Mean serum ALT(IU/L) values in rats of different experimental groups

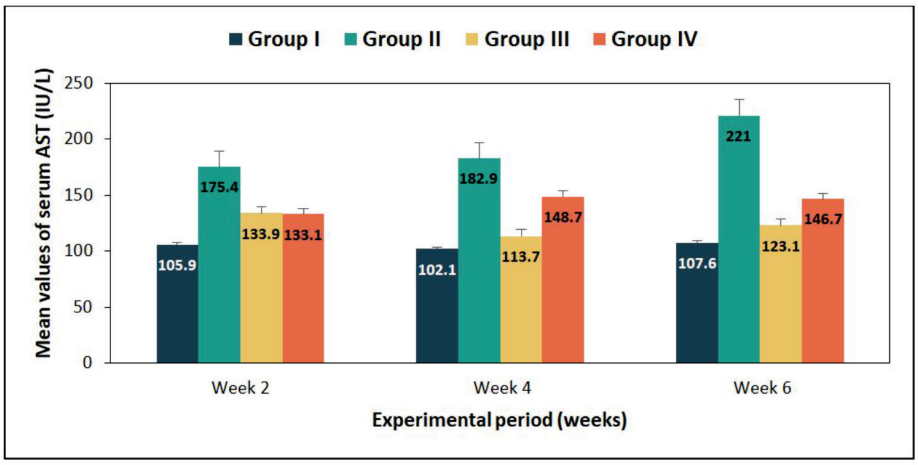

Fig.8. Mean serum AST(IU/L) values in rats of different experimental groups

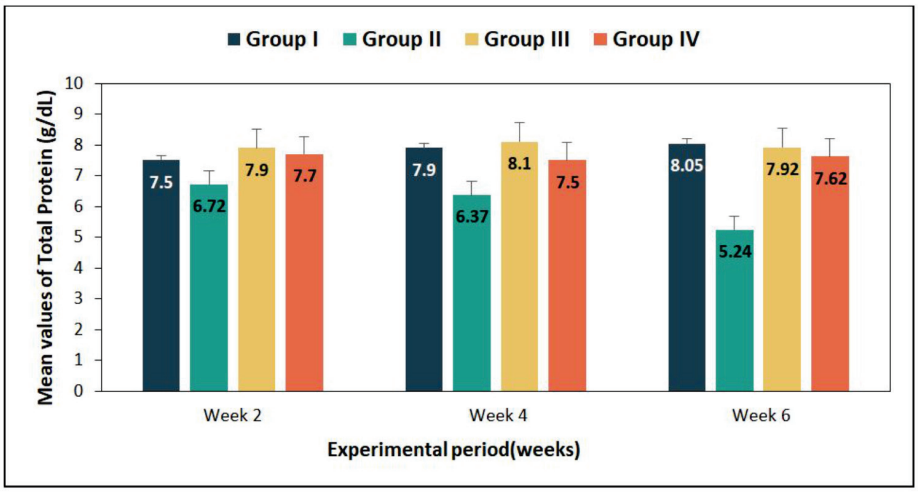

Fig.9. Mean values of serum total protein (g/dL) in rats of different experimental groups

Serum total protein (g/dL)

The mean and S.E serum values of total protein (g/dL) of rats in different groups, Group I, II, III, and IV were 7.81 ± 0.16^{b}, 6.11 ± 0.44^{a}, 7.97 ± 0.62^{b}, and 7.60 ± 0.58^{b}, respectively, and are given in Fig.9. In comparison with the control group of rats, there was a significant decrease ($p<0.05$) in total protein value in fipronil-treated rats (Group II). No significant difference was noticed in the total protein values of *Moringa oleifera*-treated rats (Group III) compared to control rats (Group I). At the same time, these values were restored in *Moringa oleifera*-ameliorated rats (Group IV), when compared to fipronil-treated rats (Group II).

Serum albumin (g/dL)

The mean and S.E serum values of albumin (g/dL) of rats in different groups, Group I to IV were 4.51 ± 0.99^{b}, 3.44 ± 0.28^{a}, 4.67 ± 0.29^{b}, and 4.47 ± 0.90^{b} (g/dL), respectively, and are given in Fig.10. There was a significant decrease ($p<0.05$) in the mean value of albumin in fipronil-treated rats (Group II), when compared to the control rats (Group I). Meanwhile, a significant improvement was noticed in *Moringa oleifera*-ameliorated rats (Group IV) compared to fipronil-treated rats (Group II). No significant difference was noticed in the mean serum albumin values of *Moringa oleifera*-treated rats

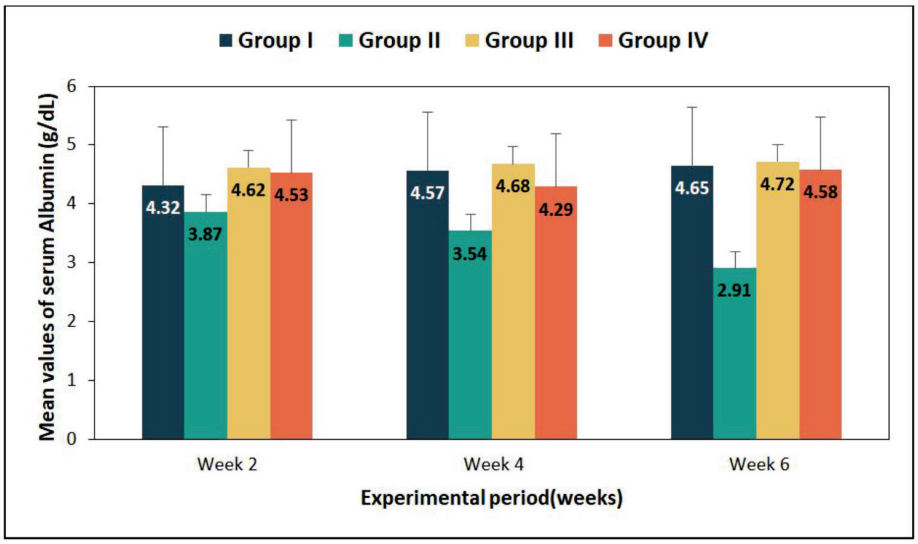

Fig.10. Mean values of serum albumin (g/dL) in rats of different experimental groups

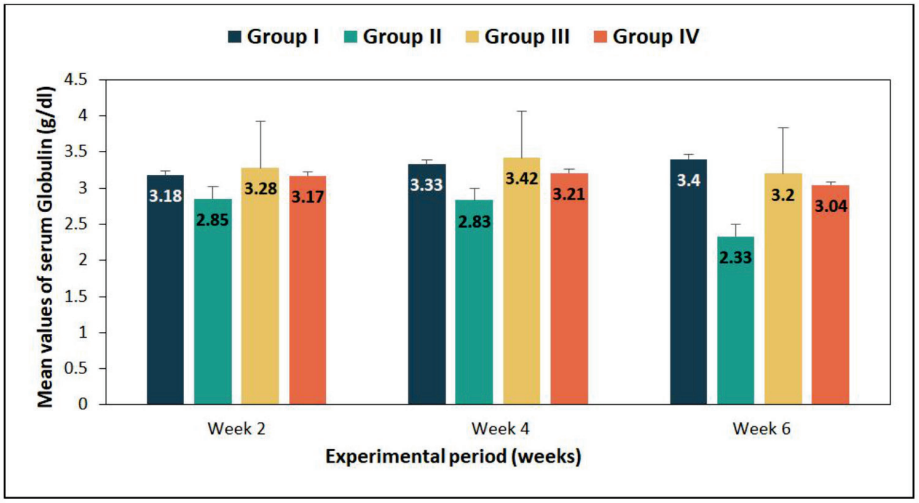

Fig.11. Mean values of serum globulin (g/dL) in rats of different experimental groups

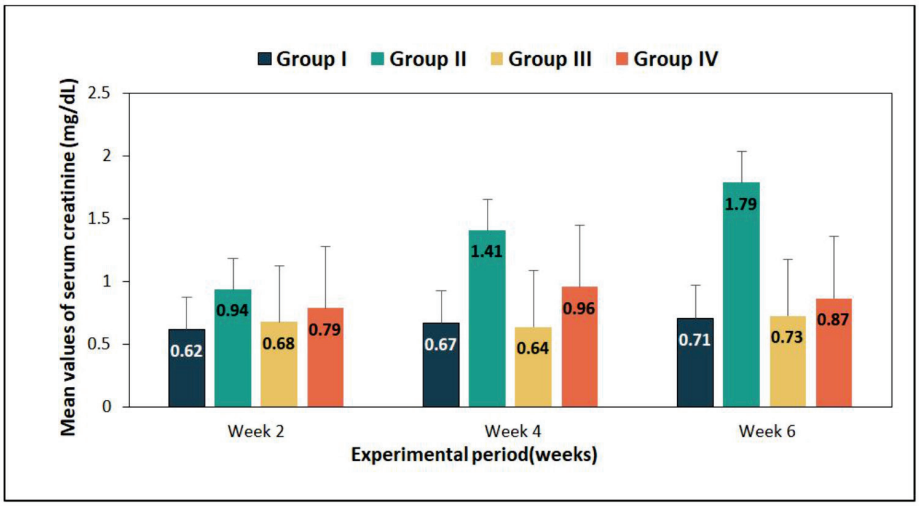

Fig.12. Mean values of serum creatinine (mg/dL) in rats of different experimental groups

(Group III) compared to control rats (Group I).

Serum globulin (g/dL)

The mean and S.E values of serum globulin (g/dL) of rats in different groups, Group I to IV were 3.30 ± 0.06^{b}, 2.67 ± 0.17^{a}, 3.30 ± 0.64^{b}, and 3.14 ± 0.05^{b}, respectively, and are shown in Fig.11. Statistically a significant ($p<0.05$) decrease was observed in mean serum globulin levels in fipronil-treated rats (Group II) when compared to the control rats (Group I). No significant difference was noticed in the *Moringa oleifera*-treated (Group III) and *Moringa oleifera*-ameliorated rats (Group IV) compared to control rats (Group I).

Serum creatinine (mg/dL)

The mean and S.E values of serum creatinine (mg/dL) of rats in different groups, Groups I to IV were 0.67 ± 0.26^{a}, 1.38 ± 0.25^{b}, 0.68 ± 0.45^{a}, and 0.87 ± 0.49^{ab}, respectively, and are presented in Fig.12. A significant ($p<0.05$) increase in the serum creatinine values was observed in fipronil-treated rats (Group II) when compared to control rats (Group I). The rats treated with fipronil and *Moringa oleifera* (Group IV) showed no significant difference in these values when compared with the fipronil-treated rats (Group II), and also with the control rats (Group I). Whereas the *Moringa oleifera*-treated rats (Group III) showed no significant difference in serum creatinine values when compared with control rats (Group I).

Blood urea nitrogen (BUN) (mg/dL)

The mean and S.E values of serum blood urea nitrogen (mg/dL) of rats in different groups, Group I to IV were 25.08 ± 0.90^{b}, 39.24 ± 0.99^{c}, 20.62 ± 0.42^{a}, and 26.69 ± 1.03^{b}, and are given in Fig.13. There was a significant ($p<0.05$) increase in mean serum

BUN values in fipronil-treated rats (Group II) when compared to the control rats (Group I). A significant decrease ($p<0.05$) was observed in the values of *Moringa oleifera*-ameliorated rats (Group IV) compared to fipronil-treated rats (Group II), and a significant decrease ($p<0.05$) was observed in the values of *Moringa oleifera*-treated rats (Group III) compared to the control rats (Group I).

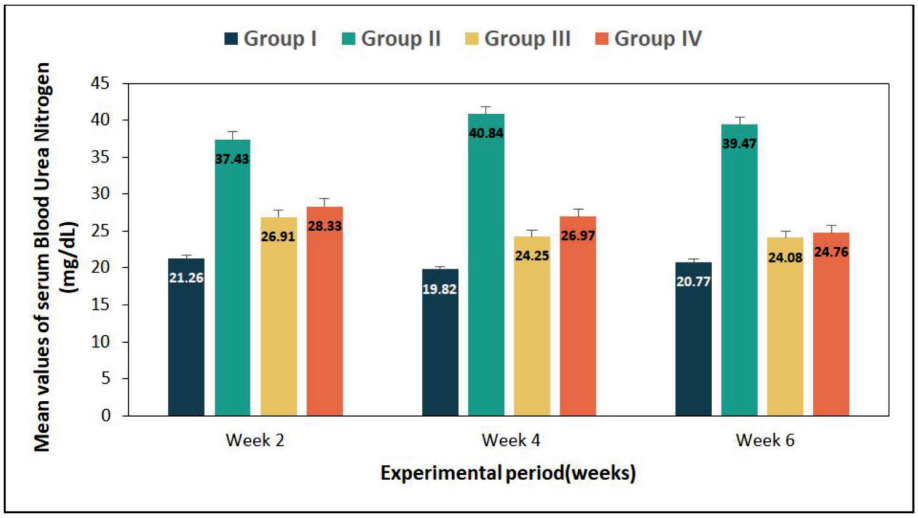

Fig.13. Mean values of serum BUN (mg/dL) in rats of different experimental groups

DISCUSSION

The findings of the present study demonstrated significant alterations in haematological parameters due to exposure to fipronil. The administration of *Moringa oleifera* leaf extract has shown a protective effect, which is evident by improvement in the haematological parameters. There is a remarkable reduction in the TEC, Hb and PCV values in the fipronil-administered rats when compared to the control group. These findings were in accordance with the observations of previous authors[13]. Fipronil, by producing ROS species, causes oxidative damage to the bone marrow and disrupts erythropoiesis[14]. Fipronil disrupts the membrane integrity and stability of erythrocytes through its interaction with membrane phospholipids, resulting in an imbalance in the bilipid layer of the cell membrane. This leads to the production of spherocytes, acanthocytes, and echinocytes, which are prone to hemolysis[15]. The kidneys are the primary source of erythropoietin, which stimulates RBC production in the bone marrow, and the histopathological examination revealed renal damage, supporting the noticeable decrease in the TEC, Hb and PCV values in this study.

A significant reduction in total leucocyte count and lymphocyte count, and an increase in neutrophil count were observed in fipronil-treated rats in comparison to the control rats. These observations are in accordance with[16], where they observed a progressive and steady decrease in the leucocyte count over time. The decrease in lymphocyte count is attributed to the immunotoxic effect of fipronil and oxidative damage to the lymphoid organs. This observation was further supported by the gross pathological findings, wherein the splenic atrophy was observed in the fipronil-treated rats during necropsy. Since lymphocytes constitute the major fraction of leucocytes, their decrease is reflected in the total leucocyte count. The increase in the neutrophil count could be due to the response of the immune system to stressful conditions[14].

Moringa oleifera ameliorated rats (Group IV) exhibited a significant improvement when compared with the fipronil-treated rats in all of the haematological parameters like Hb, PCV, TEC, and also restored lymphocyte and total leucocyte count. These findings are in accordance with[17]. The flavonoids and phenolic compounds in the *Moringa oleifera* act in synergism and aid in improving the haematological parameters through attenuation of oxidative stress, and stimulate the stem cells in producing erythrocytes through erythropoiesis[18]. The *Moringa oleifera* leaves are rich in iron content, which acts as the main nutrient in haematopoiesis, and Vitamin C in *Moringa oleifera* leaves also facilitates iron absorption by forming a chelate with ferric iron that is soluble in the duodenum. The observed increase in leucocyte count is also reported in previous studies[19], where it might be due to its potent antioxidant and immunostimulatory effect which protects the bone marrow from anti-oxidants and stimulates the production of white blood cells and enhances the body's defence mechanism against toxic insult In addition the amelioration of pathological lesions in the kidneys and spleen, where kidneys appeared normal, reduction in splenic atrophy and restoration of the splenic architecture may have contributed to the improvement in the haematological aspects.

The mean values of the liver and kidney function biomarkers ALT, AST, BUN, CRE of the fipronil-treated rats (Group II) were significantly increased compared to the control rats (Group I). These results coincided with the observations of[20]. The liver plays a crucial role in metabolizing insecticides, making it susceptible to the oxidative damage. The elevated serum levels of these enzymes in fipronil treated rats might be due to seepage of enzymes from liver cytosol into the bloodstream, caused by worsened cell membrane permeability or hepatocyte damage, induced by fipronil sulfone, a

metabolite of fipronil that interferes with the electron transport chain, resulting in decreased ATP production, resulting in Ca^{++} influx, eventually compromising membrane integrity and cause the release of AST and ALT[21]. Fipronil enhances NADPH oxidase activity and mitochondrial superoxide production in the kidney, leading to lipid peroxidation and damage renal proteins that results in damage to the glomeruli and tubules, thus impairing filtration and tubular reabsorption. These structural alterations disrupt kidney architecture, reduce filtration efficiency, and hinder the clearance of urea and creatinine[20]. The histopathological examination of the liver revealed atrophied hepatic cords, along with focal necrotic areas in the parenchyma. The kidney revealed degenerated tubules along with moderate vacuolization in the glomeruli. These observations coincided with the elevation of liver and kidney functional biomarkers.

A significant reduction in the serum total protein, albumin, and globulin levels was evident in the fipronil treated rats when compared to the control group. These findings are consistent with previous findings of[22]. Albumin and globulin, synthesized in the liver, acts as carrier proteins, albumin primarily maintains colloid osmotic pressure, whereas globulin plays a key role in immune defence. The decline in these levels in this study might result from decreased protein synthesis in the liver caused by hepatic damage from fipronil exposure. A decrease in serum total protein, albumin, and globulin levels indicates the immunosuppressive effect[23] of fipronil.

These biomarkers were restored to normal in *Moringa oleifera*-ameliorated rats. This recovery towards normal transaminase enzyme and protein levels suggests that *Moringa oleifera* might aid in regenerating parenchymal cells, thus protecting cell membranes from damage and likely reducing the leakage of marker enzymes into the bloodstream[24]. The amended effect on kidney markers could be due to antioxidant activities of *Moringa oleifera* leaves, which are attributable to the presence of polyphenols that increase endogenous antioxidant enzymes, helping to protect tubular cells by upregulating anti-apoptotic proteins and by scavenging ROS. This improvement in functional biomarkers coincided with the amelioration of histopathological lesions and the restoration of histoarchitecture in the liver and the kidney, under microscopic examination.

CONCLUSION

The findings of the present study indicate that fipronil causes alterations in various haematological and biochemical parameters in rats, and co-administration of *Moringa oleifera* along with the fipronil had attenuated these changes and restored them to normal. Therefore, *Moringa oleifera* could be considered as an effective way to mitigate the fipronil-induced haemato-biochemical alterations.

ACKNOWLEDGMENTS

The authors are thankful to the Sri Venkateswara Veterinary University, Tirupati for providing various facilities to carry out the present research work.

Financial support & sponsorship: None

Conflicts of Interest: None

Use of Artificial Intelligence (AI)-Assisted Technology for manuscript preparation: The authors confirm that there was no use of AI-assisted technology for assisting in the writing of the manuscript and no images were manipulated using AI.

REFERENCES

1. Ouaarous M, El Fakhouri K, Taarji N, Baouchi A, Amri M, Ramdani C. 2025. Impact of field insect pests on seed and nutritional quality of some important crops: a comprehensive review. *ACS Omega* **10**: 8779–8792.
2. Aajoud A, Ravanel P, Tissut M. 2003. Fipronil metabolism and dissipation in a simplified aquatic ecosystem. *J Agric Food Chem* **51**: 1347–1352.
3. Gill JPS, Bedi JS, Singh R, Fairoze MN, Hazarika RA, Gaurav A. 2020. Pesticide residues in peri-urban bovine milk from India and risk assessment: a multicenter study. *Sci Rep* **10**: 8054.
4. Singh NS, Sharma R, Singh SK, Singh DK. 2021. A comprehensive review of environmental fate and degradation of fipronil and its toxic metabolites. *Environ Res* **199**: 111316.
5. Chiș A, Noubissi PA, Pop OL, Mureșan CI, Fokam Tagne MA, Kamgang R. 2023. Bioactive compounds in *Moringa oleifera*: mechanisms of action, focus on their anti-inflammatory properties. *Plants (Basel)* **13**(1):20.
6. Kasem TS. 2019 Effect of *Moringa oleifera* on hemato-biochemical and histological alterations in rats after exposure to high voltage electromagnetic field. *J. Res. Fields Specific Educ* **5**(22): 143-166.
7. CCSEA. 2018. Compendium of CPCSEA. *Ministry of Fisheries, Animal Husbandry and Dairying, Government of India*.
8. O'Neil MJ, Heckelman PE, Koch CB, Roman KJ. 2013.The Merck Index - An Encyclopedia of Chemicals, Drugs, and Biologicals. Cambridge: UK: Royal Society of Chemistry; XV edition, 748 pp.
9. Soliman SS, Suliman AA, Fathy K, Sedik AA. 2025. Ovario-protective effect of *Moringa oleifera* leaf extract against cyclophosphamide-induced oxidative ovarian damage and reproductive dysfunction in female rats. *Sci Rep* **15**: 1054.
10. Jain NC. 1986. Schalm's Veterinary Hematology - Lea and Febiger, Philadelphia II edition, pp.1221.
11. Coles EH. 1986. Veterinary clinical pathology. *W.B. Saunders* company, Philadelphia, USA, pp.445-446.
12. Snedecor WG, Cochran GW. 1994. Statistical methods. 8th ed. *Iowa State University Press*, 258–268.
13. Al-Janabi Q, Hamed L, Khaleel Ibraheem A. 2023. Effects of nano-fipronil on male rats' biochemical, liver, and renal functions. *IOP Conf Ser Earth Environ Sci* **1259**: 012033.
14. Ghaffar A, Hussain R, Abbas G, Kalim M, Khan A, Ferrando S. 2018. Fipronil induces hemato-biochemical, histological and genetic damage at low doses in common carp, *Cyprinus carpio*. *Ecotoxicol* **27**: 1261–1271.

15. Yumnam D, Dutta BK, Paul SB, Choudhury S. 2017. Alterations in the erythrocyte membrane and ultrastructural changes in the liver and kidney of albino mice exposed to fipronil. *Nat Environ Pollut Technol* **16**: 273-278.
16. Nakul P, Sujatha K, Kumar A, Vijayalakshmi S. 2024. Fipronil toxicity induced hemato-biochemical alterations in male Wistar albino rats and its alleviation with pomegranate peel extract. *Indian J Vet Pathol* **48**: 159–168.
17. Fachruddin F, Suprayogi A, Manalu W, Hanif N, Darusman HS. 2025. Hematology and reproductive performance of female rats supplemented with kelor (*Moringa oleifera* Lam.) leaf extract during the reproductive period. *Open Veterinary Journal* **15**(6):2651–60.
18. Suzanne DrBBS, Adeline FYS, Theodora K, Dairou H, Pradel KL, Aristide KM. 2020. Hemopoietic effects of some herbal extracts used in treatment of infantile anemia in Cameroon. *World J Pharm Med Res* **6**: 147–155.
19. Nurhayati T, Fathoni MI, Fatimah SN, Tarawan VM, Goenawan H, Dwiwina RG. 2023. Effect of *Moringa oleifera* leaf powder on hematological profile of male Wistar rats. *J Blood Med* **14**: 477–485.
20. Abdel-Daim MM, Abdeen A. 2018. Protective effects of rosuvastatin and vitamin E against fipronil-mediated oxidative damage and apoptosis in rat liver and kidney. *Food Chem. Toxicol* **114**:69–77.
21. Vroon DH, Israili Z. Aminotransferases. 1990. In: Walker HK, Hall WD, Hurst JW, editors. Clinical Methods: The History, Physical, and Laboratory Examinations. 3rd ed. Boston: Butterworths.
22. Behery M, El-Sayed Y, Eldakroury M, Abdelhiee E. 2022. Hepatoprotective Effect of Quercetin Nanoparticles Against Fipronil Toxicity in Adult Male Rats. *Mat. J. Vet. Med* **2**(1):13–7.
23. Nayak AK, Das BK, Kohli MPS, Mukherjee SC. 2004. The immunosuppressive effect of alpha-permethrin on Indian major carp, rohu (*Labeo rohita* Ham.). Fish Shellfish Immunol **16**(1):41–50
24. Singh D, Arya PV, Aggarwal VP, Gupta RS. 2014. Evaluation of antioxidant and hepatoprotective activities of *Moringa oleifera* Lam. Leaves in carbon tetrachloride-intoxicated rats. *Antioxidants* **3**(3):569–591.