Indian J. Vet. Pathol., 50(4) : 348-352, 2026: DOI: https://doi.org/10.56093/6hz5fb92

RESEARCH ARTICLE

Pathological alterations induced by acute oral exposure to Acephate in Wistar rats

C.S. Mishra, R.C. Ghosh, Pramod Kumar and Devesh Kumar Giri*
Department of Veterinary Pathology, College of Veterinary Science and Animal Husbandry, Anjora (DSVCKV) Durg, Chhattisgarh

Address for correspondence
Dr. Devesh Kumar Giri, E-mail: giri.devesh18@gmail.com
ORCID ID: 0009-0005-8000-4697, 0000-0003-3016-5837, 0009-0009-2070-1318, 0000-0001-7555-3337

Received: 8.5.26; Accepted: 3.6.26

ABSTRACT

Acephate is an organophosphate pesticide that has been widely used to control insect pests in agricultural fields for decades. There is increasing concern for public health due to their widespread usage. The current experimental investigation was planned to study the toxicopathological effects of acephate in female Wistar rats following an acute toxic dose. The acute toxic dose of acephate was determined by approximate lethal dose (ALD) method. The ALD for acephate was found to be 1350 mg/kg body weight, orally in female Wistar rats. The rat showed signs of profuse salivation, depression, prostration, piloerection, scant droppings, chromodacryorrhoea, dyspnoea, gasping, clonic convulsion, hunched posture, soiled perineum and loss of reflexes. The rat died at 5 hours and 35 minutes of oral acephate intoxication. The pathomorphological changes observed at necropsy were those of generalised congestion in vital organs i.e. liver, heart, kidneys, lung and brain. Apart from haemorrhages and congestion in liver, lung, kidneys and heart, the histopathological lesions represented tubular necrosis and glomerular degeneration in kidney, degenerative and necrotic changes in cardiac muscles, severe lymphocytolysis in the Malpighian corpuscles in spleen, thickening of interalveolar septa in lung and moderate degenerative and necrotic changes in neurons in brain. It can be concluded that acute toxic dose of acephate causes hepatotoxicity, nephrotoxicity neurotoxicity together with considerable damage to the histoarchitecture of lungs, heart and spleen.

Keywords: Acephate, Organophosphate, Pathomorphology, Toxicopathology

INTRODUCTION

The widespread use of pesticides in public health programme and agriculture has caused severe environmental pollution and potential health hazards. Introduction of new, more toxic and rapidly disseminating pesticides into environment has necessitated accurate identification of their potential hazards to animal and human health. Many pesticides are extremely toxic to mammals and/or other target organisms. The extent of hazard depends on the amount of residue and its toxicity. Today there are some 200 organophosphorus ester insecticides, in the market place formulated into literally thousands of products[1]. Acephate is the International Organization for Standardization (ISO) approved name for the organophosphorus insecticide O, S-dimethyl acetylphosphoramidothioate[2]. It is one of the top ten organophosphate insecticides used in agriculture[3]. Acephate is organophosphorus insecticide with contact and systemic action on sucking and biting insects and has been widely used for the protection of vegetables and fruits due to its wide range activity against Agromyzidae, Lepidopterans', Hymenoptera, Thysanoptera and Aphids[4]. Methamidophos, the primary metabolite of acephate in plants, birds and mammals, has significantly more potent inhibitor of cholinesterase activity than acephate[2].

Acephate can overstimulate the nervous system causing nausea, dizziness, confusion and at very high exposures (accidents or major spills), respiratory paralysis and death. A number of studies showed the toxicity of acephate on different organisms which indicated it as a potent hepatotoxic[5], nephrotoxic[5], neurotoxic, mutagenic, carcinogenic and cytotoxic compound[6,7].

The reports on pathological effects on visceral organs following an acute toxic dose are meager in available literature. The present report puts on record the approximate lethal dose of acephate in Wistar rats along with the clinical signs observed during the study. It also throws light on the pathomorphological alterations in visceral organs associated with acute toxicity of acephate.

How to cite this article: Mishra, C.S., Ghosh, R.C., Kumar, P. and Giri, D.K. 2026. Pathological alterations induced by acute oral exposure to Acephate in Wistar rats. Indian J. Vet. Pathol., 50(4) : 348-352.

MATERIAL AND METHODS

Acute toxicity of acephate in female Wistar rats was determined by approximate lethal dose (ALD) method as described by Hayes[8] after obtaining approval from Institutional Animal Ethics Committee (IAEC). Acephate, 75% SP (TATA ASATAF 75 SP) purity

was obtained from Rallis India Limited Mumbai, India. For this purpose, 6 healthy female rat weighing 110 - 120 g were taken. Based on the reviewed literature, an arbitrary dose of 267 mg acephate/kg body weight dissolved in 1 ml of distilled water was given *per os* to a rat by gastric probe. As the rat survived, second rat was given 1.5 times the initial dose i.e. 400 mg acephate/kg body weight, *per os* and sequentially, several rats were given increasing doses of acephate in the similar manner (600, 900 and 1350 mg acephate/kg body weight, *per os*) until a lowest lethal dose was achieved. One rat was kept as control and given 1 ml distilled water, *per os*. All the rats were critically observed to record the clinical manifestation of toxicity.

The rat died during the acute toxicity study was subjected to detailed post-mortem examination. The representative tissue samples were collected in 10% neutral buffered formalin for histopathological studies. Paraffin embedded tissue sections of 4 - 5 µm were obtained as described by Luna[9] and stained with Haematoxylin and Eosin (H&E) as per the method described by Bancroft and Stevens[10] with slight modifications. The stained sections were examined under light microscope and the lesions were recorded, if any.

RESULTS

ALD and associated clinical manifestations

The approximate lethal dose of acephate was determined as 1350 mg acephate/kg body weight, *per os* in female Wistar rat. The rat intoxicated with an initial arbitrary dose of 267 mg acephate/kg body weight, orally showed mild irritation and hyperactivity just after administration of the dose. However, the rat recovered to normalcy after a short time gap of 25 minutes. Another rat being exposed to 400 mg acephate/kg body weight exhibited the signs of mouth smacking, mild irritation and hyperactivity followed by salivation and depression. The third rat intoxicated with 600 mg acephate /kg body weight showed irritation, hyperactivity and salivation followed by depression, prostration and reduced motor activity. Another rat received 900 mg acephate/kg body weight, orally exhibited the toxic signs instantaneously. The rat exhibited irritation, hyperactivity and tachypnea within 45 minutes, colourless discharge from nostrils, eyes and salivation along with prostration, followed by somnolence 2 hours post exposure. However, the rat recovered after 10 hours from all these signs and assumed normal functions.

Therefore, one more rat was intoxicated orally with a 1.5 times higher dose of 1350 mg acephate /kg body weight. The toxic signs appeared instantaneously following its administration and became more pronounced with passage of time. The toxic signs noticed after 2 hours and 10 minutes comprised of depression, prostration, piloerection, profuse salivation, colourless lacrimation and dyspnoea. Passage of loose droppings with soiled perineum was observed at 3 hours and 45 minutes followed by gasping (deep laboured inspiration, accompanied by a wheezing sound) and clonic convulsions. These signs were accomplished by loss of other reflexes *i.e.* corneal eyelid closure (touching of cornea causes eyelid to close), myotact (ability of animal to retract its hind limb when limb is pulled down over the edge of surface), righting reflex (loss of reflex to maintain normal upright posture when placed on the back), pupillary reflex (constriction of pupil in presence of light) and startle reflex (response to external stimuli such as touch and noise). The toxicity signs were very pronounced at 4 hours and 30 minutes post-intoxication with soiled perineum, severe salivation, exophthalmos, chromodacryorrhoea, hunched posture and prostration (Fig. 1). The rat died at 5 hours and 35 minutes of oral acephate intoxication. As the rat died following intoxication with 1350 mg acephate/kg body weight, the aforesaid dose was considered as approximate lethal dose for Wistar rats.

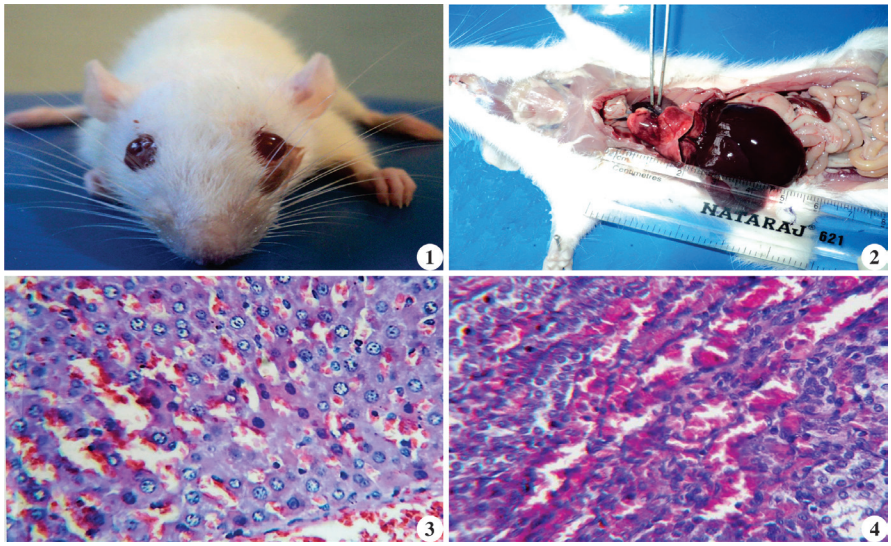

Fig.1. Exophthalmos with chromodacryorrhoea and excessive salivation in female rat exposed to Approximate Lethal Dose of Acephate at 1350 mg/kg body weight, orally; **Fig.2**. Congestion in lung, heart and liver of female rat exposed to Acephate at 1350 mg/kg body weight, orally in acute toxicity study; **Fig.3**. Liver of rat exposed to ALD (Acephate at 1350 mg/kg body weight, orally). Showing haemorrhages in hepatic parenchyma. H&E X400; **Fig.4**. Kidney of rat exposed to ALD (Acephate at 1350 mg/kg body weight, orally). Showing degenerative and necrotic changes of tubular cells and haemorrhages in the intertubular space. H&E X400

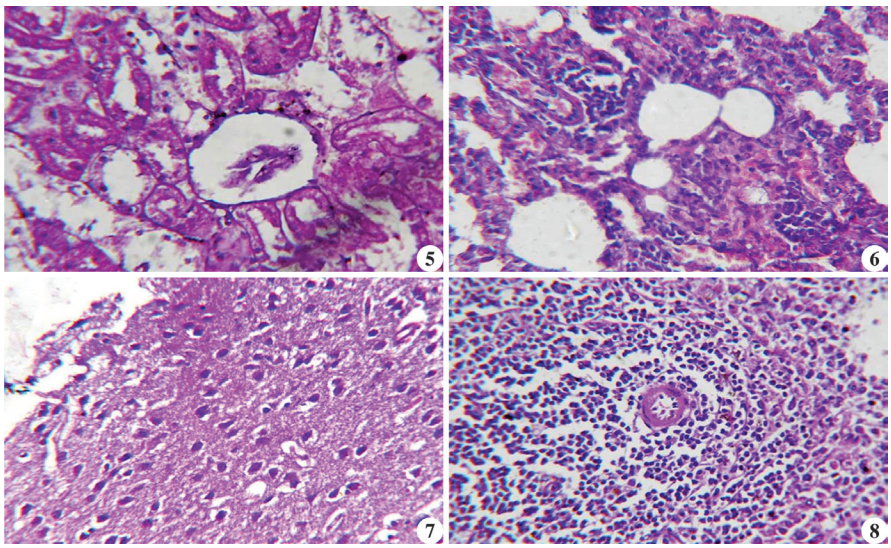

Fig.5. Kidney of rat exposed to ALD (Acephate at 1350 mg/kg body weight, orally). Showing lysis of renal tubular cells and necrosis in the glomerular tuft. H&E X400; **Fig.6**. Lung of rat exposed to ALD (Acephate at 1350 mg/kg body weight, orally). Depicting haemorrhages and thickening of inter alveolar septa. H&E X400; **Fig.7**. Brain of rat exposed to ALD (Acephate at 1350 mg/kg body weight, orally). Showing mild degenerative and necrotic changes in neurons. H&E X400; **Fig.8**. Spleen of rat exposed to ALD (Acephate at 1350 mg/kg body weight, orally). Showing severe depletion in the number of lymphocytes in Malpighian corpuscles. H&E X400.

Pathology of acute acephate toxicity

At necropsy the external examination of the dead female rat showed wet hairs around the mouth, exophthalmos and the soiled perineum region. The pathomorphological changes observed at post-mortem examination of the rat died of acute Acephate toxicity were generalized congestion in the vital organs *i.e.* liver, heart, lungs (Fig. 2), kidneys and brain.

Histopathological screening of the liver sections represented severe degenerative and necrotic changes in hepatocytes along with haemorrhages in the hepatic parenchyma (Fig. 3). There were mild dilatations of sinusoids at places. Histopathology of kidneys revealed pronounced changes in the corticomedullary areas. There were severe haemorrhages in the intertubular spaces (Fig. 4) along with profound degenerative changes in the lining epithelium of proximal convoluted tubules and distal convoluted tubules. In addition to these changes, there was also necrosis in glomerular tuft (Fig. 5).

The representative sections of heart showed mild degenerative and necrotic changes characterized by increased eosinophilia of the cardiac myocytes. Sections of the lung revealed severe congestion and thickening of interalveolar septa with infiltration of erythrocytes (Fig. 6). The histopathological sections of brain showed mild degenerative and necrotic changes in the form of shrunken neurons (Fig. 7). The sections of spleen represented severe depletion of lymphocytes from the Malpighian corpuscles (Fig. 8).

DISCUSSION

The ALD of acephate corroborated closely with the earlier reports[11,12,13]. WHO documented the median oral LD_{50} of acephate in rats as 1000-1400 mg/kg body weight[2]. The other report of the oral LD_{50} of acephate in rats and mice is 360 – 1000 mg/kg body weight[11]. The observed clinical manifestations can be attributed to the inhibition of enzyme acetylcholinesterase in the synapse and neuromuscular junctions. It is moderately toxic to mammals as it gets converted to methamidophos in the body. The common symptoms of acephate poisoning include salivation, nasal discharge, vomiting, diarrhea, nausea, blurred vision, difficulty in breathing, headache, and muscle weakness. Convulsions, coma, and death may occur in cases of severe acute poisoning as reported by earlier coworkers[2,7].

The observations of necropsy in the present investigation were in accordance with the earlier reports[2,5,7,12,13]. The rats exposed to acephate at different dose levels revealed dose dependant pathological changes[12]. Earlier workers[12] further reported that the main target organs affected were found to be liver, kidney, brain and lungs. The pathomorphological changes comprised of varying degrees of congestion, hemorrhages, degeneration, and necrosis in various visceral organs and lysis of lymphoid cells in spleen. Heart, spleen and lung showed congestion and haemorrhages. Prasad and others[13] reported moderate enlargement of liver, pale discoloration and friable consistency. Heart showed petechiae on pericardium and kidneys were swollen and hemorrhagic. Similarly, Londhe and others[14] reported degeneration in liver and kidney of 1/20th of LD50 of acephate treated female rats.

Our findings corroborates well with earlier reports[5,7] who outlined severe damage in hepatic tissue including prominent enlargement of sinusoids, infiltration of mononuclear cell, dilation, hemorrhage and necrosis. They also reported degeneration of glomeruli, Bowman's capsules and associated tubules structure in kidney[5,7]. The histopathological findings in the liver might be due to peroxidation of lipid and tissue damage is the result of induction of oxidative stress due

to excessive generation of free radicals and inhibition of several enzymes involved in ATP generation by the toxicity of pesticides. The mechanism of generation of oxidative stress is related to pesticide biotransformation[15].

Inhalational exposure of acephate in individuals produced pulmonary oedema, haemorrhages, tracheobronchitis and shortness of breath[2]. This clearly indicates direct action of acephate on respiratory tract mucosa and blood vascular system[2]. Moreover, the pathogenesis of tissue damage in acephate toxicity has been attributed to oxidative stress and modification of lipid component of cells as indicated earlier. Cardiac arrest following accidental exposure to high levels of acephate has been attributed to the development of hypocalcaemia and/or hyperkalaemia[15]. The acute lesions in heart might have occurred because of enhanced lipid peroxidation, increased free radical formation and inhibition of various cellular enzymes.

The acute effects of acephate upon the central nervous system could be due to inhibition of enzyme acetylcholinesterase at synaptic junction[13,14,15]. The changes in spleen might be attributed to acute stress imposed by much higher acephate concentration. As reported by earlier workers the main target of organophosphates is central and peripheral nervous system attributed to inactivation of enzyme acetylcholinesterase[16] but acute and subchronic toxicity of organophosphates is also due to disturbance in redox reactions resulting into oxidative stress. The disturbance in the balance between the generation and removal of free radicals within body by organophosphates leads to oxidative stress by production of free radicals such as reactive oxygen species (ROS). The major biomolecules such as proteins, lipids and nucleic acids are attacked by ROS, but lipids are targeted the most and hence lipid peroxidation of cell membranes takes place resulting into pathological lesions.

The results of this study may provide guidelines for selecting doses for subacute and chronic toxicity study of acephate in laboratory rats. Based on the findings of this study, it is concluded that approximate lethal dose of acephate in female Wistar rats is 1350 mg/kg body weight, orally. The important clinical signs included depression, dyspnoea, chromodacryorrhoea, piloerection, hunched posture, profuse salivation, clonic convulsions and loss of various reflexes. Exposure to the acute toxic dose of acephate causes various histopathological alterations in visceral organs indicating its hepatotoxic, nephrotoxic, neurotoxic, pulmonary and cardiotoxic potential. Lack of biochemical evaluation following acephate exposure in Wistar rats is the key limitation of the present investigation. Moreover, continued investigation into the toxicological potential of pesticide residue is vital to deepen our scientific understanding, inform public health strategies, regulatory policies, and sustainable farming practices aimed at protecting both health of human and livestock and also the environment.

ACKNOWLEDGEMENT

The authors are thankful to Dean, College of Veterinary Science and A.H., DSVCKV, Anjora, Durg, C.G for providing necessary facilities to carry out the work.

Financial support & sponsorship: None

Conflicts of Interest: The authors report no conflict of interest.

Use of Artificial Intelligence (AI)- Assisted Technology for manuscript preparation: The authors confirm that there was no use of AI-assisted technology for assisting in the writing of the manuscript and no images were manipulated using AI.

REFERENCES

1. Mulla SI, Ameen F, Talwar MP, Eqani SAMAS, Saxena RNBG, Tallur PN. 2020. Organophosphate pesticides: impact on environment, toxicity, and their degradation, In: Bharagava RN, Saxena S. eds *Bioremediation of Industrial Waste for Environmental Safety* Cham: Springer.
2. World Health Organization. 2005. Pesticide residues in food – 2005, Report of the Joint Meeting of the FAO Panel of Experts on Pesticide Residues in Food and the Environment and the WHO Core Assessment Group on Pesticide Residues Geneva, Switzerland, 20–29 September 2005.
3. Ribeiro TA, Prates KV, Pavanello A, Malta A, Tófolo LP, Martins IP. 2016. Acephate exposure during perinatal life program to type 2 diabetes. *Toxicol*. **372**: 12-21.
4. Spassova D, White T, Singh AK. 2000. Acute effects of acephate and methamidophos on acetylcholinesterase activity, endocrine system and amino acid concentrations in rats. Comparative Biochemistry and Physiology-- Part C: *Pharmacol. Toxicol. Endocrinol*. **126**(1): 79-89.
5. Jain E, Vashishat N. 2003. Toxicity of acephate to liver and kidney of female Wistar rats. *Indian J Entomol* **85**(2): 322-326.
6. Singh AK, Jiang Y. 2002. Immunotoxicity of acute acephate exposure in control or IL-1-challenged rats: correlation between the immune cell composition and corticosteroid concentration in blood. *J. Appl. Toxicol*. **22**: 279–291.
7. Karanth S. 2014. Acephate In: Wexler P. ed. *Encyclopedia of Toxicology* 3rd edn. Academic Press.
8. Hayes AW. 2001. Principles and methods of Toxicology. Philadelphia: Tylor and Francis.
9. Luna LG. 1972. Manual of histological staining methods of the Armed Forces Institute of Pathology. Philadelphia: W. B. Saunders.
10. Bancroft JD, Stevens A. 1990. Theory and Practice of Histological Techniques. Edinburgh: Churchill Livingstone. 113-305.
11. Gupta PK, Moretto A. 2005. A draft on acephate (addendum). Proceedings. Joint meeting on pesticide residues. 3-16.
12. Bhadaniya AR, Kalariya VA, Joshi DV, Patel BJ, Chaudhary S, Patel HB, Patel JM, Patel UD, Patel HB, Ghodasara SN, Savsani HH. 2015 . Toxicopathological evaluation in Wistar rats (*Rattus norvegicus*) following repeated oral exposure to acephate. *Toxicol Indus Health*. **31**(1): 9–17.
13. Prasad MS, Babu KR, Ravikanth SV, Narender P, Jacob DP.

2013. Alterations in the acetylcholinesterase activity in the brain of albino mice exposed to acephate. *The Bioscan* **8**(3): 1039-1041.

14. Londhe SA, Gangane GR, Moregaonkar SD. 2020. Subacute toxicity assessment of acephate and it's amelioration by *Picrorhiza kurroa* in female wistar rats. *Int J Curr Microbiol Appl Sci* **9**(12): 3242-3250.
15. Lin Z, Pang S, Zhang W, Mishra S, Bhatt P, Chen S. 2020. Degradation of acephate and its intermediate methamidophos: mechanisms and biochemical pathways. *Front Microbiol* **11**:2045.
16. Ndonwi EN, Atogho-Tiedeu B, Lontchi-Yimagou E, Shinkafi TS, Nanfa D, Balti EV, Indusmita R, Mahmood A, Katte J, Mbanya A, Matsha T, Mbanya JC, Shakir A, Sobngwi E. 2019. Gestational exposure to pesticides induces oxidative stress and lipid peroxidation in offspring that persist at adult age in an animal model**.** *Toxicol Res* **35**: 241-248.