Indian J. Vet. Pathol., 50(4) : 353-360, 2026: DOI: https://doi.org/10.56093/pmsq3f71

RESEARCH ARTICLE

PET-CT imaging, gross & microscopic features in systemic microsporidial diseases in laboratory rabbits

Yogita Shete*, Abhishek Gupta, Sutapa Rakshit and Sandip Basu
Radiation Medicine Centre, BARC, C/o TMH Annexe, Parel, Mumbai- 400 012

***Address for correspondence**
Dr. Yogita Shete, E-mail: yogeshwarivet@gmail.com
ORCID ID: 0000-0001-8594-9183

Received: 20.5.26; Accepted: 25.6.26

ABSTRACT

Encephalitozoon cuniculi can cause latent disease, especially in lagomorphs, and many wild and domestic animals in various countries. This infection is important for veterinary and public health because it is caused by a potentially zoonotic and opportunistic pathogen. This study investigated subclinical disease pathology in rabbits by comparing findings from Positron Emission Tomography-Computed Tomography imaging with serological titres in rabbit samples. which may be useful in early predicting the disease in clinically healthy rabbits. A total of 4 animals showing higher serological titres had undergone for PET-CT imaging. Rabbits that developed symptoms and had a positive titre were euthanized, and a necropsy was conducted (n=2). Serum creatinine levels were quantified, and histopathological analyses were performed on all vital organs from the affected rabbits. PET-CT imaging showed increased brain, focal liver and kidneys uptake were significantly higher in seropositive animals. Gross lesions showing brain congestion, necrotic kidney with grey cloudy urine were further confirmed of infection by necropsy. Histopathological findings in the kidney, degenerative changes and *Encephalitozoon cuniculi* spores were identified in the tubule and brain. Elevated levels of serum creatinine levels were found to have a significant relationship with the serological status and PET-CT imaging findings in the affected rabbits. This study revealed that PET-CT imaging would be useful for the evaluation of early changes in subclinical infection of the rabbits with *Encephalitozoon cuniculi* in conjunction with the routine ELISA method to increase diagnostic accuracy, & valuable adjunct to clinical interpretation for timely treatment in these laboratory animals.

Keywords: PET-CT Imaging, ELISA, Histopathology, Zoonosis, Laboratory Animals, Encephalitozoonosis, Gross features

INTRODUCTION

Encephalitozoonosis is a zoonotic, microsporidian parasitic disease that affects a wide range of hosts, including humans, dogs, non-human primates, rodents, and birds[1,2,3]. The causative agent, *Encephalitozoon cuniculi* (*E. cuniculi*), is an obligate intracellular spore-forming protozoan parasite (phylum Microsporidia). First identified in a laboratory rabbit in the USA in 1922[4], this infection is now common in domestic and laboratory rabbits worldwide, with clinical signs predominantly have been reported primarily in rabbits.[5&6] Furthermore, the disease has gained increasing attention due to its zoonotic potential[7,8,17].

The form of disease is apparent as chronic and subclinical in nature. In rabbits, *E. cuniculi* mainly affect CNS, renal and ocular system, show neurological signs, chronic renal failure or uveitis.[9] Most common findings reported in the clinical cases are vestibular signs, circling and paresis. However, *E. cuniculi* infective sporont escapes from the immune system, and continues germination progress and reaches at chronic stage in infected animals.[7] Therefore, seropositive cases and clinical signs do not concur.[3,10] Therefore, the confirmatory diagnosis of disease is difficult based on clinical signs.

The grading and distribution of microscopically developed lesion related with *E. cuniculi* infection are partially correlated with clinical signs and in some animals though histologically positive, does not produce any clinical sign of the disease[11]. The previous reports showed many rabbits persevere subclinical form of disease for months together. Post-brain inflammation and infection, infected rabbits exhibit clinical signs, torticollis, paresis and longitudinal rolling the animal is often incapable to cure themselves.

How to cite this article: Shete, Y., Gupta, A., Rakshit, S. and Basu, S. 2026. PET-CT imaging, gross & microscopic features in systemic microsporidial diseases in laboratory rabbits. Indian J. Vet. Pathol., 50(4) : 353-360.

This is unique microsporidia disease once the clinical signs developed, it is very difficult to clinically manage the animals and to restore the normal function. Hence early diagnosis of the disease is very important to provide the appropriate treatment to the animals.

Therapeutic options for *E. cuniculi* infections are scarce. Fenbendazole, an antiparasitic agent, effectively inhibits parasitic replication and curtails disease progression, making it highly valuable for prophylaxis

and early intervention. Nevertheless, it does not repair existing neurological or ocular lesions. Consequently, management during the clinical torticollis stage is strictly supportive, given the absence of a specific curative therapy to reverse the CNS damage inflicted by the parasite. Early diagnosis is critical to stop systemic spread and organ damage[11].

Nuclear medicine imaging with Positron Emission Tomography-Computed Tomography (PET-CT) & Single Photon Emission Computed Tomography is relatively underutilized in laboratory animal diagnostics due to regulatory causes, cost, and expertise limitations, despite its superior capacity for early disease detection. Fluorodeoxyglucose - PET-CT imaging is recognized as an indispensable, high-accuracy tool for diagnosing and staging numerous cancers[12]. Positron-emitting radioisotopes allow for the non-invasive, in vivo, and quantitative mapping of molecular, biochemical, and pathological processes. *E cuniculi* infection also follows the same path, early diagnosis is crucial for planning treatment ahead, leading to improved outcomes.

Diagnosis of *E. cuniculi* infection in rabbits requires a comprehensive approach because of the high prevalence of asymptomatic carriers[13]. Conventional diagnostic methods include physical examination and analysis of blood, urine, and faecal samples in live animals, while definitive diagnosis in deceased animals relies on systematic necropsy, histopathology, and Gram staining of tissues[14]. However, these methods may fail to detect early lesions and subclinical systemic abnormalities *in vivo*. PET-CT is a non-invasive imaging modality that provides anatomical and functional information, enabling sensitive detection of focal and multifocal lesions, even in asymptomatic animals. Therefore, PET-CT may offer comprehensive *in vivo* assessment of disease dissemination. The present study evaluated the prevalence of subclinical disease in a conventional rabbit colony using ELISA and correlated the findings with clinical signs and whole-body PET-CT imaging. In clinically affected rabbits, PET-CT findings were further correlated with histopathological changes to assess the extent of organ involvement.

MATERIALS & METHODS

Animal species selected

Researchers routinely brought different rabbits to the facility for experiments approved under various projects (BAEC/02/22, BAEC/23/24). As routine veterinary care involves monitoring animals for illness, with suspected cases set aside for comprehensive diagnostic evaluation. For this study, the New Zealand White rabbits (n=9; both male and female rabbits) were included under routine health monitoring of the housed animals. All the animals first underwent clinical examination. Blood samples were collected for hematology and ELISA test. Animals suspected clinically (n=1) were segregated and put for imaging and testing to evaluate and diagnose the disease condition.

Sample Analysis

ELISA of rabbit serum samples were tested for the detection of *E. cuniculi* antibodies using a commercial ELISA kit (Medicago AB-18-9001, Sweden). A total of nine (n = 9) serum samples were analysed in duplicate. Indirect ELISA was performed according to the manufacturer's protocol. Briefly, antigen-coated polystyrene microplates were washed with PBS-T, and sample positions were recorded on the ELISA worksheet before sample processing. The plate was sealed and incubated at room temperature (RT) for 60 minutes. It was then washed three times with 350 µL PBS-T per well and tapped upside down on a paper towel. Subsequently, 100 µL of diluted HRP-conjugated antibody was added to each well and incubated at RT for 30 minutes. The plate was washed again three times with 350 µL PBS-T. Conjugate binding was performed by adding 100 µL of diluted HRP-conjugated antibody to each well and incubating the plate in the dark at RT for 30 minutes, followed by three washes with 350 µL PBS-T. Finally, the substrate reaction was initiated by adding 100 µL of TMB substrate to each well, and the plate was incubated at RT for 15 minutes until colour development was observed. The enzymatic colour reaction was stopped by adding 50µl stop solution/well (colour turns yellow) and the optical density was read at 450 nm using a microplate reader. Results were analysed by comparing samples with positive and negative controls. For valid interpretation, the mean negative control absorbance for both control antigen- and EC antigen-coated wells was required to be ≤0.200 OD, while the positive control absorbance for EC antigen-coated wells was required to be >0.800 OD (A450). The sample ratio was calculated as A450 (EC-coated well)/A450 (control antigen-coated well). Samples with a ratio >2 were classified as positive for EC antibodies, whereas samples with a ratio <2 were classified as negative for EC antibodies[15].

Animal PET-CT imaging

PET-CT imaging was performed using a GEMINI TF 16-slice PET-CT scanner. Animals were restrained by intramuscular administration of ketamine (22–80 mg/kg body weight) and xylazine (5 mg/kg body weight). Imaging was acquired using a standard protocol (Serview: 90 kV, 20 mA; CT: 120 kV, 80 mA; PET: 1 min emission/bed). Approximately 1 mCi of 18F-FDG was administered intravenously, and imaging was performed 1 h post-injection. Data were reconstructed using the Row-Action Maximum Likelihood Algorithm (RAMLA), and coronal, sagittal, and transverse images were qualitatively analysed[5,16].

Necropsy findings, and histopathological analysis

Blood samples were collected from rabbits (n = 9) via the ear vein for serological analysis. Animals exhibiting torticollis, neurological signs, and compromised daily activity were euthanized using an overdose of anaesthetics. A complete necropsy was performed to identify pathological lesions in vital organs. The brain, liver, kidneys, and lungs were collected, fixed in 10% neutral buffered formalin, and processed for histopathology. Light microscopic examination was performed to identify and confirm the presence of microsporidia in the tissues[17,18,19].

RESULTS

Clinical diagnosis

In-house screening including serum ELISA testing was performed on all facility-housed New Zealand White rabbits. Subsequently, a physical examination was conducted post-sample collection. All animals appeared clinically healthy, except for one that presented with anorexia and a slight neck tilt, which underwent a whole-body PET-CT scan (Fig.1).

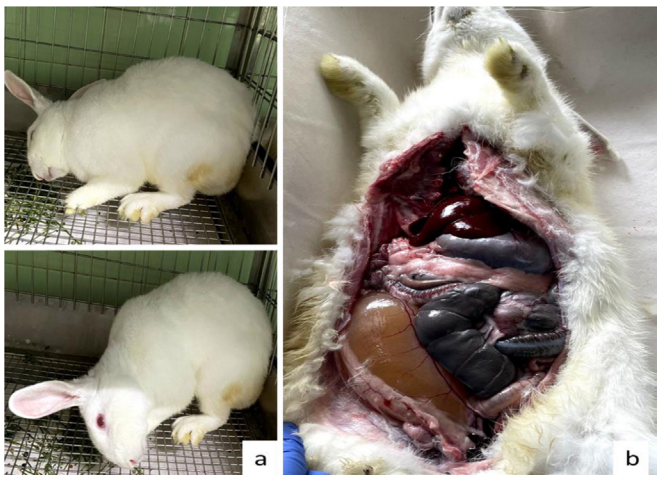

Fig.1. Clinical signs and gross necropsy features. (a) Neck twisting exhibited by the rabbit; **(b)** Necropsy showing abnormally kidney with distended urinary bladder, liver and lung congestions.

Gross and microscopic pathological findings

Central Nervous System (CNS) lesion

Gross examination of the brain revealed diffuse cerebral congestion, multifocal haemorrhages, and focal degenerative lesions. Histopathology showed vascular congestion, perivascular lymphocytic infiltration, glial nodules, astrogliosis, parasitic cysts, neuronal degeneration and necrosis, and vacuolation around cells. Gliosis around pyramidal cells and degeneration of Purkinje cells were also observed. *E. cuniculi* meronts in H&E-stained sections. These findings were consistent with encephalitis (Fig.2).

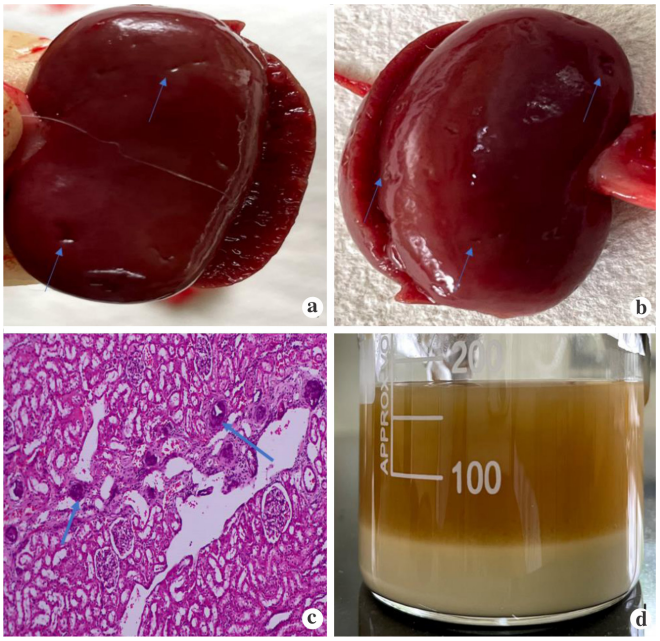

Fig.3. Kidney lesions Grossly multifocal contracted kidneys **(a&b)**; **(c)** Histopathology showed atrophy of glomeruli and tubular swelling and multifocal area inflammatory cell infilteration H&E x100; **(d)** Cloudy yellow dark coloured urine.

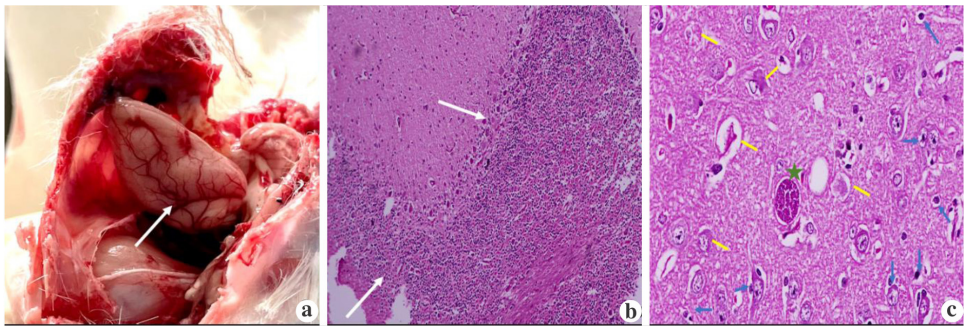

Fig 2: Brain encephalitis: gross & microscopy lesion (a) Grossly showed engorged blood vessels; **(b)** Histopathology showed multifocal area of infiltration of glial cells with neuronal degeneration under 100x stained with H&E stain; **(c)** Rabbit *Encephalitozoon Cuniculi* Brain Lesion charcateristics: Neuron degeneration and necrosis (line), single or multiple large vacuoles visible around cells, multifocal area of gliosis (arrow) around pyramidal cells and degeneration of Purkinje cells. Round parasitophoro vacuoles with *E. Cuniculi* organism (star) H&E x400.

Kidney and liver lesions

Gross examination revealed bilateral renal coloration ranging from dark to pale, with minor adhesion of the capsule to the cortex and multiple superficial, punctate subcapsular pits. The urinary bladder was significantly distended, containing concentrated, foul-smelling, dark yellow urine. Histopathology reveals multifocal tubulointerstitial changes, including tubular degeneration, swelling, and atrophy of the glomeruli,

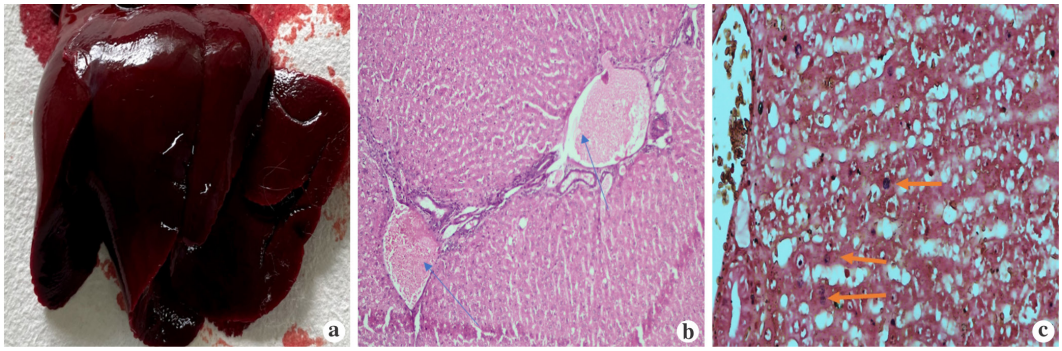

Fig. 4. **Liver lesions. (a)** Grossly liver showed diffuse congesion in all lobes and oosing of blood on cut surface; **(b)** Histopathology presented hepatic degenerative changes with Central and portal vein congestion with multifocal area of infiltration of MNC & PNC infiltration of inflammatory cells under 40x stained with H&E stain.; **(c)** Gram staining of liver section showed Gram positive spores of *E. Cuniculi* in the liver (arrow) H&E x100.

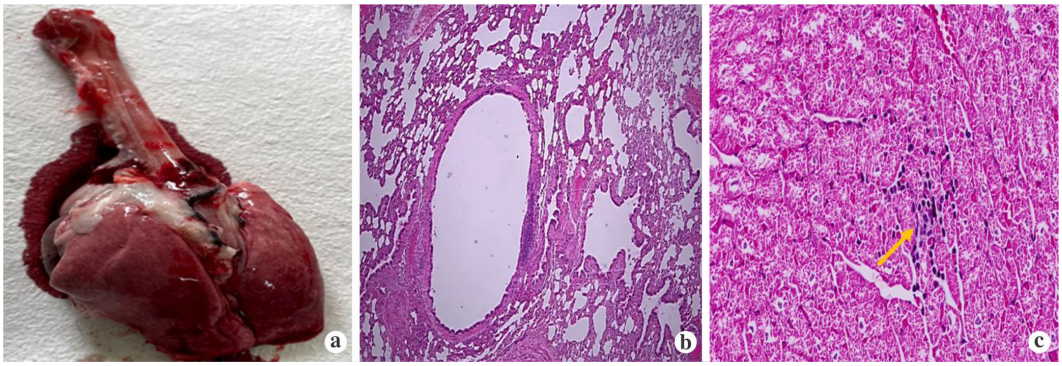

Fig.5. Lung lesions. (a) Lungs grossly showed diffuse congestion of all lobes; **(b)** Histopathology showed interstitial pneumonia and diffuse congestion and infiltration of inflammatory cells. under 40x stained with H&E stain; **(c)** Heart illustrated myofibrillar degeneration, focal necrosis, and mononuclear cell infiltration(yellow arrow) H&E x400.

consistent with nephritis. Serum creatinine level showed 2.8–3.0 mg/dL in clinically positive cases. Microscopic analysis showed few pus cells, epithelial casts, and calcium carbonate crystals, accompanied by high protein levels.

Diffuse congestion of all liver lobes, with profuse oozing of blood from the cut surface, indicative of chronic passive congestion. Hepatic histopathology showed degenerative changes with congestion of the central and portal veins, alongside multifocal MNC (mononuclear cell) and PNC (polynuclear cell) inflammatory infiltration. Encephalitozoon spores were identified

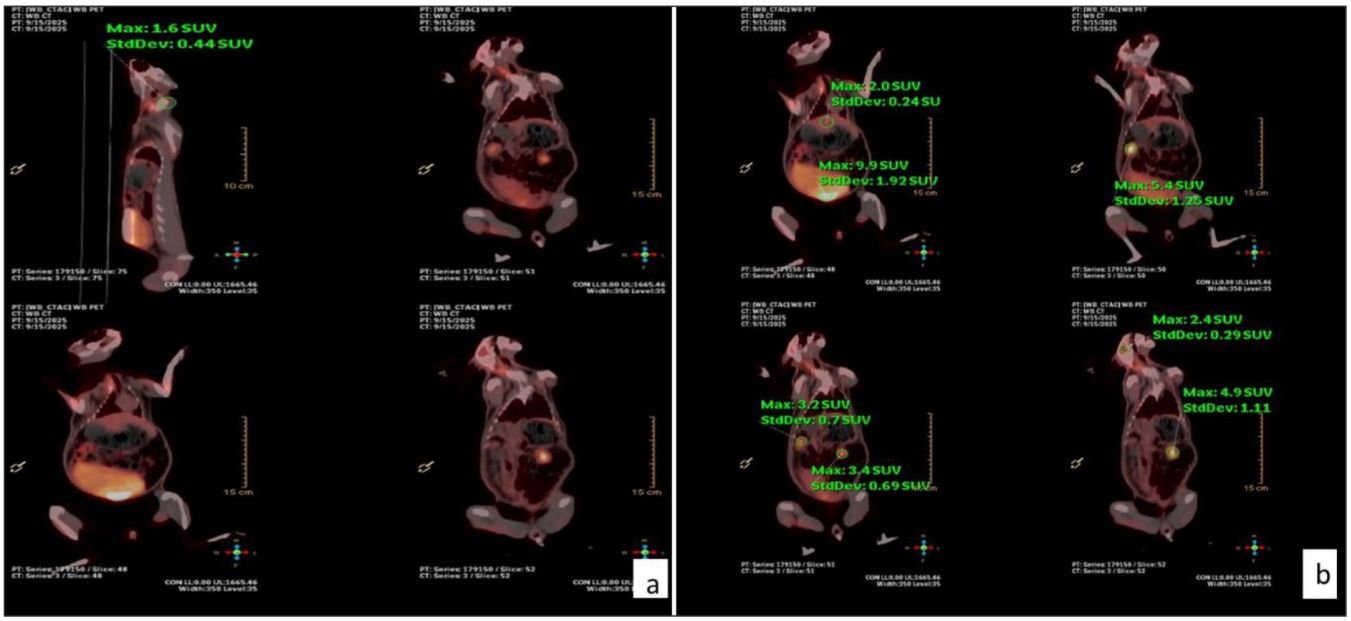

Fig. 6. Whole body PET-CT image in rabbit. (a&b) Quantitative imaging analysis of the PET/CT rabbit images demonstrated variable radiotracer uptake across different organs and anatomical regions. Whole-body PET/CT fused images demonstrated the radiotracer's biodistribution across various anatomical regions in the rabbit, with focal uptake noted in the cervical paraspinal and cervical lymphoid tissues. Prominent uptake and retention were observed in both the liver and kidneys. Quantitative assessment was performed using Standard Uptake Value (SUV) measurements obtained from regions of interest (ROIs) marked on the images.

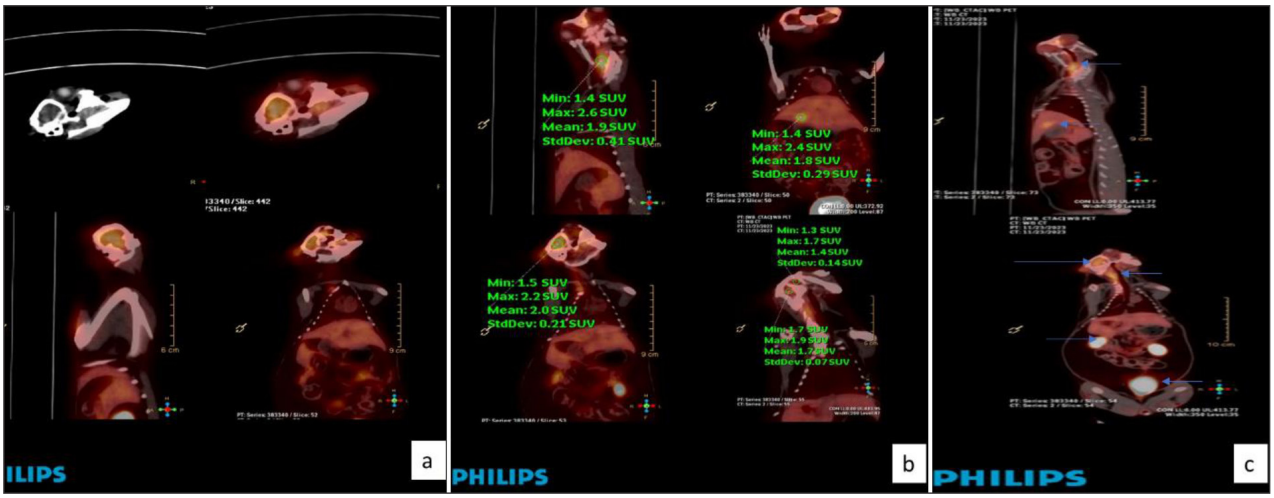

Fig. 7. Whole body PET-CT image in rabbit. Quantitative imaging analysis of the PET/CT rabbit images demonstrated variable radiotracer uptake across different organs and anatomical regions; **(a&b)** Intense brain, liver, kidney and bladder uptake seen in body, **(c)** Multifocal brain, liver, and cervical spinal cord(blue arrow) uptake seen in rabbit PET-CT image rabbit.

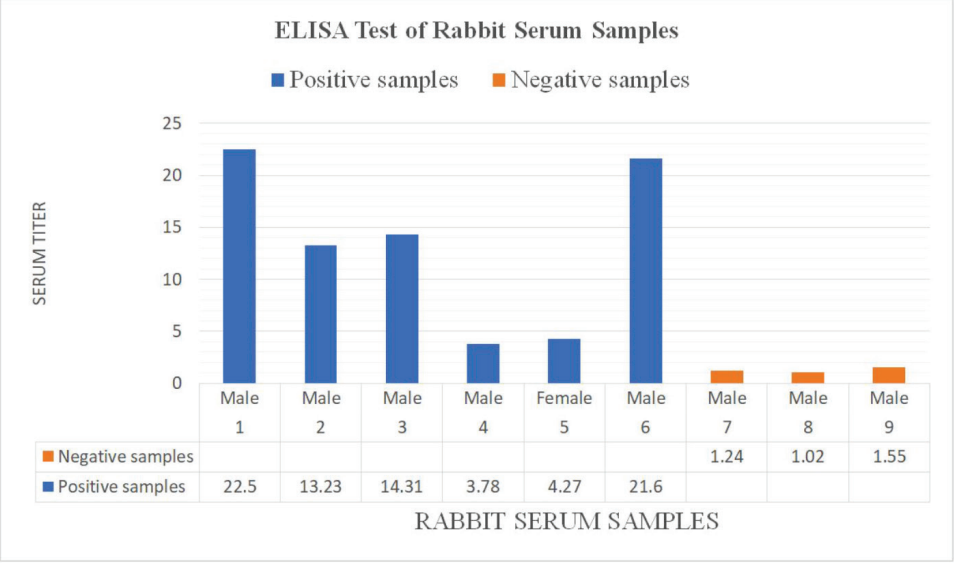

Fig. 8. Rabbit serum sample analysis results by ELISA method showed positive titre and negative titres.

within the liver sections via Gram staining (Fig.3, 4 and 9).

Heart and lung lesions

Grossly, the heart appeared normal; however, microscopic examination revealed patchy myofibrillar degeneration with focal necrosis and mononuclear cell infiltration. The lungs showed diffuse congestion grossly, while histopathology revealed interstitial pneumonia with inflammatory cell infiltration of the alveolar septa (Fig. 5,9).

PET-CT imaging

PET/CT imaging revealed inflammatory changes in the cervical region involving the cervical lymph nodes, paraspinal tissues, and cervical spinal musculature. Both kidneys and an abnormally distended urinary bladder showed increased radiotracer uptake (SUVmax: 9.9 ± 1.92). Focal uptake was also observed in the brain (2.4 ± 0.02 SUVmax), cervical neural structures (2.6 ± 0.41 SUVmax), and liver (2.0 ± 0.24 SUVmax), with mild radiotracer retention in the kidneys (5.4 ± 1.25 and 4.9 ± 1.10 SUVmax) (Figs. 6, 7 and 9). Clinically ill and sub-clinically affected rabbits with high serum titres were treated with fenbendazole, along with anti-inflammatory drugs and fluid therapy according to their clinical condition. However, fenbendazole was ineffective in reversing established neurological lesions, and supportive treatment failed to restore normal posture. Owing to a guarded prognosis, the affected animal was humanely euthanized and subjected to a detailed necropsy.

Serological test result

High levels of specific *E. cuniculi* antibodies were detected in infected rabbits, including seropositive but clinically asymptomatic animals (Fig. 8). ELISA titres differed markedly between positive and negative groups. Positive samples (n = 6) showed titres ranging from 3.78 to 22.50, with a mean of 13.28 ± 8.08, whereas negative samples (n = 3) ranged from 1.02 to 1.55, with a mean of 1.27 ± 0.27 (Table 1). An independent Student's *t*-test demonstrated that the mean

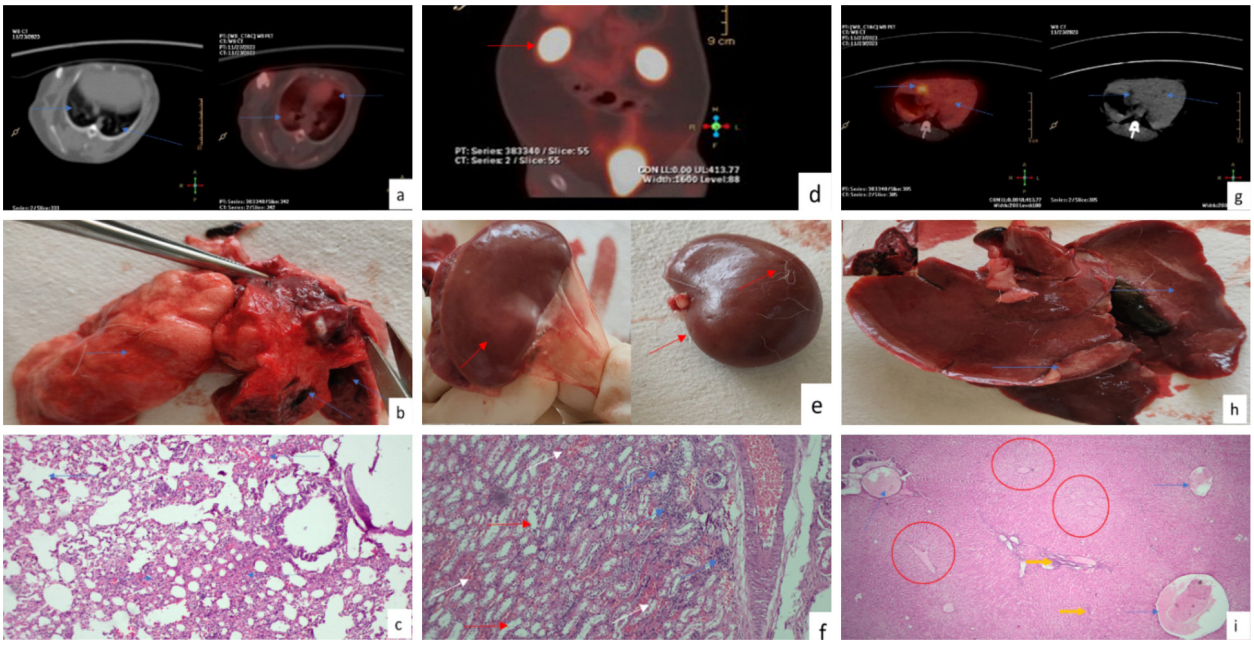

Fig. 9. Rabbit *E. Cuniculi* infection with lesion in lung, kidney and liver with PET-CT imaging. (a) PET-CT showed a prominent bright pink area of high metabolic activity in lung (blue arrow); **(b)** Gross Morphology of lung displays dark red consolidation.; **(c)** Histopathology of lung revealed marked thickening of the alveolar septa and infiltration of inflammatory cells (Hematoxylin and Eosin, 40x); **(d)** PET/CT Scan showed bright areas indicating regions of intense FDG uptake and retention in both the kidneys and bladder**; (e)** Gross morphology of kidney showed multifocal areas of pitting and a contracted kidney**; (f)** Histopathology of kidney showed tubular dilation (red arrow), necrosis, severe interstitial vascular congestion (white arrow), and infiltration of inflammatory cells (blue arrow) (Haematoxylin and Eosin, 40x); **(g)** PET-CT of liver revealed a focal bright yellow spot indicating increased uptake of the radioactive tracer; **(h)** Gross morphology of liver organ presented with hepatomegaly, showing congestion across all lobes and multifocal pale foci on the left lobe (blue arrow); **(i)** Histopathology of Liver exhibited central and portal vein congestion (blue arrow) and panlobular hepatocellular degeneration. Multiple hepatocytes appeared prominently swollen with pale, cleared cytoplasm (circle). Multifocal clusters of inflammatory cells were also present (yellow arrow) (H&E, 40x).

Table 1. ELISA results for sample processed for *E. cuniculi* infection.

Rabbit No	Positive Titre (Mean value : 13.28±3.3)	Negative Titre (Mean value : 1.27±0.15)
Rabbit 1		1.55
Rabbit 2	22.50	
Rabbit 3	13.23	
Rabbit 4	14.31	
Rabbit 5		1.02
Rabbit 6	3.78	
Rabbit 7	4.27	
Rabbit 8		1.24
Rabbit 9	21.60	
Total	N = 6	N = 3

titre of positive samples was significantly higher than that of negative samples (t = 3.64, p = 0.015). These findings confirm a strong serological response and the presence of *E. cuniculi* infection in seropositive rabbits.

DISCUSSION

Diagnosis of *E cuniculi* infection is the challenging for the veterinarian in the field as well as in captive laboratory animals due to their natural propensity of hiding the signs and symptoms[20,21]. A primary goal of recent veterinary research is to improve the accuracy of antemortem diagnosis by exploring advanced techniques, such as PCR and in-vivo imaging to better differentiate between exposure and active infection[22].

Generally, *E. cuniculi* infected rabbits act as asymptomatic carriers for prolonged periods, yet the progression of the parasite can lead to rapid, severe neurological manifestations in otherwise healthy animals[23]. Consequently, thorough clinical history and physical examination are essential for detecting early signs of sickness behavior in laboratory rabbits[24]. Therefore, early diagnosis of *E. cuniculi* relies heavily on attentive clinical evaluation, including monitoring feed intake and weight loss, which are essential for identifying active infections[25-27]. These clinical observations essential for isolating sick rabbits concurred with our findings.

The rabbit exhibited torticollis and longitudinal rolling, characteristic of central vestibular disease and consistent with chronic *E. cuniculi* infection, which commonly manifested with these signs[17,28]. Furthermore,

the observed neurological deficits were often associated with *E. cuniculi* induced renal insufficiency, characterized by elevated serum urea and abnormal phosphorus levels[29,30].

Subclinical *E. cuniculi* infection hindered progressive weight gain, making it a critical indicator for herd managers to detect and isolate affected animals, alongside clinically positive cases.[31] Prompt diagnosis, control measures, and timely treatment of systemic *E. cuniculi* reduce morbidity and mortality in laboratory rabbits. Historically, ELISA has been the established serological method for this diagnosis. Serological analysis in screed rabbits showed that elevated IgG with variable concentration, serves as a marker for recovering or chronic phase of disease. However, published literature showed that both IgM and IgG used in detection of *E. cuniculi* infection. The elevated IgM served as a marker of acute infection, whereas elevated IgG was typical of the convalescent or chronic phase[22,32].

Hybrid nuclear medicine imaging PET-CT, coupled with appropriate radiotracers, delivers superior, integrated anatomic-functional, comprehensive diagnostic information, surpassing the clinical utility of conventional structural or functional imaging techniques. An established in-*vivo* PET-CT imaging method is a very beneficial modality in diagnosis of systemic spread of the infection with help of ^{18}F-FDG radiotracer[33]. This well-established real time imaging methodology was explored in understanding of pathology for *E. cuniculi* disease. The detection of focal hypermetabolism at the junction of the brainstem and upper cervical spine (C1) in PET-CT imaging suggested an underlying lesion, which aligned with the clinical presentation of torticollis in the animals, further higher serological titer and histopathological lesion with parasitic cyst supported confirmatory disease diagnosis of *E. cuniculi.* PET-CT imaging revealed, in addition to cerebral involvement, distinct lesions in the liver, kidneys, and urinary bladder. Kidney associated renal retention and abnormal extended bladder suggestive of nephritis. These findings correlated with the histopathological observations. PET-CT scan findings indicated high metabolic activity in the brain, kidneys, and liver in cases of encephalitozoonosis, which aligned with earlier reported observations of multi-organ dissemination[34]. The intensification of focal radiopharmaceutical uptake was driven by the underlying pathophysiology of inflammation and increased blood supply, enabling the detection of metabolically active tissue areas.[33] Imaging findings suggesting that *E. cuniculi* caused complex, multi-organ disease in rabbits, clinicians must always address this systemic involvement in their treatment protocols.

While conventional serology confirms exposure to *E. cuniculi*, it did not reflect the severity of infection, making clinical diagnosis difficult. Given the long, silent, and often subclinical nature of the infection, ^{18}F-FDG radiotracer imaging represented a valuable step forward in antemortem diagnosis. PET-CT enabled high-accuracy mapping of active granulomatous lesions, allowing practitioners to pinpoint affected organs and determine the true systemic extent of encephalitozoonosis.

Histological findings in the liver, kidney, lung, and heart confirmed the PET-CT imaging results and are in line with earlier reports[17,35]. Furthermore, these observations aligned with established literature indicating that *E. cuniculi* induced lesions were frequently confirmed through histopathology in rats, mice, rabbits, and hamsters.

CONCLUSION

Consequently, PET-CT nuclear imaging techniques represent an advanced method for the diagnosis of diseased conditions in laboratory models. Advanced imaging modalities enable the early detection of pathological changes in preclinical models, facilitating statistically significant data collection throughout the disease process. The combined use of PET-CT or CT imaging with standard monitoring techniques offers much deeper insight and effective diagnostic ways to prevent deterioration conditions of laboratory animals. Further confirmatory diagnosis is supported by histopathology and special gram stain. As a highly sensitive and non-invasive technique, nuclear imaging, when combined with histopathology, serves as a rapid, effective diagnostic tool for identifying fatal, chronic, and challenging disease conditions in animals. However, the need for specialized facilities and specific configurations to handle radioactivity represents a major obstacle for its use in veterinary diagnostics.

ACKNOWLEDGEMENT

The study was conducted at the Animal House Facility, Department of Radiation Medicine Centre, with technical support provided by the facility staff, Bhabha Atomic Research Centre (BARC), Parel, Mumbai.

Financial support and sponsorship: Yes

Conflict of interest: None

Use of artificial intelligence for manuscript preparation: The author confirms that there was no use of AI-assisted technology for assisting in the writing of the manuscript and no images were manipulated using AI.

REFERENCES

1. Magalhaes T, Pinto F, Queiroga F. 2022. A multidisciplinary review about Encephalitozoon cuniculi in a One Health perspective. *Parasitol Res* **121:** 2463-2479.
2. Han B, Weiss L. 2017. Microsporidia: obligate intracellular

pathogens within the fungal kingdom. *Microbiol Spectr* **5:**10-1128.
3. Deplazes P, Mathis A, Baumgartner R, Tanner I, Weber R. 1996. Immunologic and molecular characteristics of Encephalitozoon-like microsporidia isolated from humans and rabbits indicate that Encephalitozoon cuniculi is a zoonotic parasite. *Clin Infect Dis* **223**:557–559.
4. Shadduck J, Pakes S. 1971. Encephalitozoonosis (nosematosis) and toxoplasmosis. *The Am J pathol* **64**: 657-672.
5. Shete Y, Bhatkar P, Bagul S, Rakshit S, Baghel N, Basu S. 2024. Use of nuclear medicine imaging for diagnosis of spontaneous disease conditions in laboratory animals. *Indian J Vet Pathol* **48**: 364-371.
6. Ozkan O, & Alcigir M. 2018. Subacute stage of Encephalitozoon cuniculi infection in eye lesions of rabbit in Turkey. *Iran J Parasitol* **13**: 301-309.
7. Mathis A, Weber R, Deplazes P. 2005. Zoonotic potential of the microsporidia. *Clin Microbiol Rev* **18**:423–425.
8. Al-Sadi H, Al-Mahmood S. 2014. Pathology of experimental Encephalitozoon cuniculi infection in immunocompetent and immunosuppressed mice in Iraq. *Patholog Res Int* **2**: 857036.
9. Jordan CN, Zajac AM, Lindsay DS. 2006. Encephalitozoon cuniculi infection in rabbits. Compendium on continuing education for the practising veterinarian-north American edition **28**:108-116
10. Valencakova A, Halanova M, 2012. Immune response to Encephalitozoon infection review. *Comp Immunol, Microbiol Infect Dis* **35**:1-7.
11. Abu-Akkada SS, Oda SS. 2016. Prevention and treatment of Encephalitozoon cuniculi infection in immunosuppressed rabbits with fenbendazole. *Iran J Vet Res* **17**: 98–105.
12. Hoskinson J, Tucker L. 2001. Diagnostic imaging of lameness in small animals. *Vet clin North Am Small Anim Pract* **31**:165-180.
13. Leblanc A, Peremans K. 2014. PET and SPECT imaging in veterinary medicine. *Semi Nucl Med* **44**: 47-56.
14. Yitbarek D, Dagnaw G. 2022. Application of advanced imaging modalities in veterinary medicine: A review. *Vet Med Res Rep.***13***:* 117-130.
15. Cray C, Arcia G, Schneider R, Kelleher S, Arheart K. 2009. Evaluation of the usefulness of an ELISA and protein electrophoresis in the diagnosis of *Encephalitozoon cuniculi* infection in rabbits. *Am J Vet Res* **70**: 478–482.
16. Phelps M. 2000. Positron emission tomography provides molecular imaging of biological processes. *ProcNatl Acad Sci* **97:** 9226-9233.
17. Gruber A, Pakozdy A, Weissenbock H, Csokai J, Kunzel F, 2009. A retrospective study of neurological disease in 118 rabbits. *J Comp pathol* **140**:31-37.
18. Frohlich J. 2020. Rats and mice. *Ferrets, rabbits, and rodents* 345-367.
19. Brar R, Sandhu H and Singh A. 2002. Veterinary clinical diagnosis by laboratory methods, Kalyani Publisher, India.
20. Calisi, R.M. and Bentley, G.E., 2009. Lab and field experiments: are they the same animal. *Horm Behav* **56**:1-10.
21. Bays TB, 2012. Behaviour of small mammals. In *Ferrets, Rabbits, and Rodents.* WB Saunders 545-556.
22. Doboși AA, Paștiu AI, Bel LV, Pop R, Tabaran AF, Pusta DL. 2024. Antemortem and postmortem diagnosis of encephalitozoon cuniculi in a pet rabbit (Oryctolagus cuniculus)-A case report. *Pathogens* **13**:1122.
23. Doboși AA, Bel LV, Paștiu AI, Pusta DL. 2022. A review of *Encephalitozoon cuniculi* in domestic rabbits (*Oryctolagus cuniculus*)-Biology, clinical signs, diagnostic techniques, treatment, and prevention. *Pathogens* **11**:1486.
24. Weary D, Huzzey J, Von Keyserlingk M. 2009. Board-invited review: Using behavior to predict and identify ill health in animals. *J Anim Sci* **87**:770-777.
25. Robinson N, Brennan M, Cobb M, Dean R. 2015. Clinical examination and weighing of patients in small animal consultations. *Vet Rec* **176**: 387.
26. Langford D, Bailey A, Chanda M, Clarke S, Drummond T, Echols S, Glick S, Ingrao J, Klassen-Ross T, LaCroix-Fralish M, and Matsumiya L. 2010. Coding of facial expressions of pain in the laboratory mouse. *Nat Methods* **7**: 447-449.
27. Fentener van Vlissingen J, Borrens M, Girod A, Lelovas P, Morrison F and Torres Y, 2015. The reporting of clinical signs in laboratory animals: FELASA Working Group Report. *Lab Anim* **49**:267-283.
28. Latney L, Bradley C, Wyre N, 2014. Encephalitozoon cuniculi in pet rabbits: diagnosis and optimal management. *Vet Med Res Rep* **6**:169-180.
29. Melillo A. 2007. Rabbit clinical pathology. *J Exot Pet Med* **16:**135–145.
30. Meredith AL, Richardson J. 2015. Neurological diseases of rabbits and rodents. *J Exot Pet Med* **24:**21–33.
31. Harcourt-Brown F, Holloway H. 2003. Encephalitozoon cuniculi in pet rabbits. *Vet Rec* **152**: 427–431.
32. Sadeghi-Dehkordi Z, Norouzi E, Rezaeian H, Nourian A, Noaman V, Sazmand A. 2019. First insight into Encephalitozoon cuniculi infection in laboratory and pet rabbits in Iran. *Comp Immunol Microbiol Infect Dis* **65:** 37–40.
33. Casali M, Lauri C, Altini C, Bertagna F, Cassarino G, Cistaro A, Erba A, Ferrari C, Mainolfi C, Palucci A, Prandini N. 2021. State of the art of [18F] FDG PET/CT application in inflammation and infection: a guide for image acquisition and interpretation. *Clin Transl Imaging* **9**: 299-339.
34. Toya L, Latney V, Bradley C, Wyre N, Ryan M. **2014.** Encephalitozoon cuniculi in pet rabbits: Diagnosis and optimal management. *Vet Med Res Rep* **5**:169–180.
35. Rodríguez-Tovar L, Nevárez-Garza A, Trejo-Chávez A, Hernández-Martínez C, Hernández-Vidal G, Zarate-Ramos J, Castillo-Velázquez U. 2016. Encephalitozoon cuniculi: grading the histological lesions in brain, kidney, and liver during primoinfection outbreak in rabbits. *J Pathol* **1**: 5768428.