Indian J. Vet. Pathol., 50(4) : 361-369, 2026: DOI: https://doi.org/10.56093/dgn50794

RESEARCH ARTICLE

Integrated anti-oxidant and anti-inflammatory actions of *Saussurea costus* root attenuate severe hepatic pathophysiology in poultry *(Gallus gallus domesticus)* experimentally challenged with *Salmonella enterica* Serovar Typhimurium

Mridul Soni, Rakesh Kumar*, R.K. Asrani, Sahil Choudhary and R.D. Patil
Department of Veterinary Pathology, Dr. G.C. Negi College of Veterinary and Animal Sciences, CSK Himachal Pradesh Agricultural University, Palampur, Himachal Pradesh, 176062, India

***Address for correspondence**
Dr. Rakesh Kumar, E-mail: rkvetpath@gmail.com
ORCID ID: 0000-0002-8481-2094

Received: 15.11.25; Accepted: 28.4.26

ABSTRACT

The present experimental study was designed to investigate the effect of Kuth (*Saussurea costus*) root extract (80% methanolic) dietary supplementation on *Salmonella enterica* serovar Typhimurium (4, 12: i: 1, 2) in Delham-Red birds, aiming to observe the effects on growth response, clinical signs, mortality, and pathological changes. Three hundred day-old Delham-Red chicks were procured and were randomly divided into six groups: Group I - plain control; Group II - *Salmonella* Typhimurium infection only; Group III - *Salmonella* Typhimurium infection + root extract @ 0.5g/l; Group IV - *Salmonella* Typhimurium infection + root extract @ 1g/l; Group V - *Salmonella* Typhimurium infection + root extract @ 2g/l; Group VI - root extract @ 2g/l only. The infections were induced on the 7th day of age, and plant extracts were administered according to group dosage on the 4th day of age. Sacrifice of the birds in different groups was done at regular intervals. The birds were observed for various parameters like clinical signs, mortality, body weight gain, liver and kidney parameters (ALT, AST, total protein, albumin, and creatinine), gross and histopathology of liver, kidney, and spleen post-sacrifice. The groups with plant extract supplementation showed fewer clinical signs, reduced mortality, improved weight gain, liver and kidney parameters, and ameliorative changes in gross and histopathology. Preservation of the liver's normal structure was observed among treatment groups, suggesting the antimicrobial and hepatoprotective effect of *Saussurea costus* against the pathology produced by *Salmonella enterica* serovar Typhimurium in the experimental bird model.

Keywords: Histopathology, Hepatoprotective, Liver damage, *Salmonella enterica* Serovar Typhimurium, *Saussurea costus*

INTRODUCTION

Poultry diseases play an important role in the down growth of this sector. Lack of proper management is one of the predisposing factors for the occurrence of such infectious diseases. Among these infectious diseases, salmonellosis is causing huge losses to the economy of farmers as well as the private poultry sector[3]. *Salmonella* affects a wide range of hosts and is one of the major pathogens of poultry, causing high mortality and economic losses. *Salmonella enterica* serovar Typhimurium is an important intracellular bacterial pathogen that causes food poisoning and gastroenteritis in millions of people worldwide each year[4]. The economic losses due to salmonellosis are a result of mortality, decreased egg production, decrease in body weight gain and reduced feed conversion ratio[5]. *Salmonella* affects the intestinal tract and causes systemic infections in organs involving the liver and spleen in poultry[6].

The antimicrobial activity of medicinal plants against different pathogenic organisms has been well-known for a long. A decreased interest in the use of plant-based medicines and antimicrobials since the discovery of antibiotics has led to concern about the emergence of antibiotic resistance. Since the emergence of antibiotic resistance against bacteria, fungi, viruses and protozoa, there has been a global shift towards plant-based products and by-products to combat antibiotic resistance[7].

The Indian Himalaya region (IHR) is a rich source of medicinal plants and comprises over 1748 plant species with known medicinal properties. *Saussurea costus* (Syn. *Saussurea lappa* or Kuth) is one of the potent medicinal plants that possesses scientific and traditional medicinal properties and is routinely used against several ailments. The plant has been reported to cure various ailments, including bronchitis, jaundice, cough, cold, fever, dysentery, cholera and ulcers.

How to cite this article: Soni, M., Kumar, R., Asrani, R.K., Choudhary, S. and Patil, R.D. 2026. Integrated anti-oxidant and anti-inflammatory actions of *Saussurea costus* root attenuate severe hepatic pathophysiology in poultry *(Gallus gallus domesticus)* experimentally challenged with *Salmonella enterica* Serovar Typhimurium. Indian J. Vet. Pathol., 50(4) : 361-369.

The roots of this plant are known for their therapeutic activities, including anti-inflammatory, anthelminthic, anti-epileptic, anticancerous, antibacterial and anti-larvacidal[8,9]. The activity of *Saussurea costus* is due to the bioactive compounds such as dehydrocostus lactone and costunolide present in the roots[8].Therefore, the present study was planned to study the pathology of experimental salmonellosis with emphasis on the ameliorative effect of *Saussurea costus* root extract in poultry birds.

MATERIALS AND METHODS

Plant material

Freshly collected *Saussurea costus* plant and roots free from dirt and dust were brought from the Lahaul & Spiti (32.6192N, 77.3784E) district of Himachal Pradesh, India. The plant species was identified at the CSIR-Institute of Himalayan Bio-resource Technology (CSIR-IHBT), Palampur, Himachal Pradesh, India. The extract was prepared using a Rotary Evaporator (Model BUCHI Rotavapor R-210) at 45 °C temperature at 175 mbar vacuum pressure and was concentrated until a thick slurry was obtained. Slurry obtained was subjected to lyophilisation till the powdered form was obtained. The percentage yield was recorded and the lyophilised extract was stored at 4°C until further use.

Procurement, serotyping, and assessment of inhibition of bacterial growth

The strain of *salmonella* used was procured from Lala Lajpat Rai University of Veterinary and Animal Sciences (LUVAS), Haryana, India. The bacterial inoculum was sent to the Central Research Institute (CRI), Kasauli on brilliant green agar (BGA) slants for identification and serotyping. The bacteria were found to be *Salmonella enterica* serovar Typhimurium (4,12:i:1,2) as per the identification receipt NSEC/31/22 dated 17.05.2022 received from CRI, Kasauli, Himachal Pradesh, India. The *in vitro* antibacterial activity of *Saussurea costus* root extract was accessed using the disc diffusion method. The discs impregnated with Dimethyl sulfoxide (DMSO) served as a negative control. The isolated organism was tested against various antibiotics like Ceftriaxone (CTR30), Gentamycin (GEN50), Amoxicillin & Clavulanic acid (AMC30), Enrofloxacin (EX10), Levofloxacin (LE5), Oxytetracycline (O30) and Amoxicillin & Salbactum (AMS30/15). Among all the antibiotics used in the *in vitro* trial, Levofloxacin (LE5) appeared to be the most potent, and thus the discs impregnated with Levofloxacin (LE5) served as a positive control. The empty sterile discs were also mounted on petri plates inoculated with bacterial suspension to check for any zone of inhibition.

Viable bacterial count and determination of LD_{50}

The viable bacterial count was determined by making serial dilutions of the *Salmonella enterica* serovar Typhimurium culture, which was incubated in Nutrient broth for 18 hours and then the colonies were counted on BGA plates. The serial dilutions were made in normal saline ranging from 10-1 to 10-7 and from each dilution 0.1 ml was uniformly spread on the BGA petri plates. The plates were inoculated for 24 to 36 hours at 37°C and after incubation the colonies on the plates were counted and the colony forming unit (cfu) per ml was determined.

Day-old chicks (72) were procured from Poultry Farm, COVAS, CSK HPKV, Palampur, Himachal Pradesh, India for the conduction of the pilot experiment and were reared under strict hygienic conditions. The birds were divided into two groups containing 36 birds in each group and each group was further sub-divided into six groups, comprising 6 birds. In one group (36 birds) the infection was given orally, while in another group the infection was given through intra peritoneal route on day 7 of their age. The birds in the first five groups were infected with 1 ml of the normal saline solution (NSS) containing different concentrations of the organism i.e. ($2x10^8$, $2x10^7$, $2x10^6$, $2x10^5$ and $2x10^4$ cfu ml^{-1}, respectively). The duration of the pilot experiment was 10 days. LD50 dose was calculated by using the method of Reed and Muench[10]. The birds were examined for the development of clinical signs and lesions by experimental infection through both routes. There was no presence of clinical signs, mortality and gross lesions in birds infected with the oral route.

Animals, management, and experimentation

Before the arrival of the chicks, the experimental room and cages were fumigated with 10% formalin and potassium dichromate and cleaned with 2.5 % phenol solution. The feeders and water beakers were also washed with 2.5 % phenol solution and later allowed to dry in the sunlight. Cleaning of the cages along with the disposal of the newspaper bedding was done at regular intervals to ensure proper hygiene until the trial was completed. The present study was conducted on day-old Delham Red (DR) birds that weighed around 25 grams and were procured from Poultry Farm, COVAS, CSK HPKV, Palampur, H.P. The birds were procured in two phases and were accordingly divided for pilot as well as final trial. The animals were kept in well-ventilated rooms and were reared under strict hygienic conditions. The birds were provided with chick mash feed obtained from the Department of Animal Nutrition, COVAS, Palampur. The feed given was priorly autoclaved at 15-pound pressure for 15 minutes. The clean and boiled water was provided to the birds throughout the experiment. The 80% methanolic extract of *Saussurea costus* roots at different doses was provided to the birds in drinking water throughout the experimental trial. The experimental cages were labelled containing animals of different groups with the animal number, dose group and dose levels. To conduct the final trial day-old Delham Red

(DR) birds (300 in no.) were also procured from Poultry Farm, COVAS, CSKHPKV, Palampur, Himachal Pradesh, India, and were reared under strict hygienic conditions and were allowed to acclimatize for four days. The experimental trial was conducted as per the guidelines given by the Committee for Control and Supervision of Experiments on Animals (CCSEA), Delhi. The extract was started from day 4 of their age, while the infection was given at day 7 of their age. The birds in the first group, i.e. group I served as controls and were given normal feed and water. The second group (Group II) served as a plain infection group and was given only infection (2×10^6 cfu ml^{-1}) along with *ad libitum* feed and water. The birds in groups III, IV & V were given infection (2×10^6 cfu ml^{-1}) along with the 80% methanolic extract of *Saussurea costus* roots @ 0.5g, 1g & 2g per litre of water, respectively. Group VI was only provided with 80% methanolic extract of *Saussurea costus* roots @ 2g per litre of water. The birds were closely monitored throughout the experiment, and the trial was continued till 21 DPI (28 days of age).

Clinical symptoms, mortality and body weight

Regular monitoring of the birds was done throughout the experiment, and were observed at least thrice a day to check for any clinical signs and mortality. The clinical signs to be monitored included huddling near the light source, dullness, loss of appetite, soiling of the vent and drooping of the head and wings. The mortality throughout the experiment was properly recorded. To assess the response of the 80% methanolic root extract of *Saussurea costus* on body weight 3 birds from each group were weighed on the days of sacrifice, i.e. 1, 3, 5, 7, 10, 14 & 21 DPI. The data obtained was properly recorded.

Serum biochemical estimation

Three birds from each group were selected on the day of the sacrifice i.e. 1, 3,5,7,10,14 & 21 DPI and approximately 2-3 ml of blood from the heart was collected. The blood sample was allowed to stand and remain undisturbed to obtain the serum. The serum collected was stored at -20°C until further use. The serum obtained was used for the estimation of serum biochemicals, which included alanine aminotransferase (ALT), aspartate aminotransferase (AST), total protein (TP), total creatinine (CRT) & albumin (ALB). Estimation of biochemical parameters was carried out using the diagnostic kits (Agappe diagnostics Ltd, India) and semi-automatic biochemical analyser (AGAPPE MISPA-NEO, India).

Gross pathological examination

The birds were sacrificed throughout the experiment, and those who died during the experiment were subjected to detailed necropsy examination. After the detailed necropsy examination, approximately 0.5 cm thick representative tissue sections of the liver were collected in 10 % neutral buffered formalin (NBF) for histopathological examination from three birds in each group on 1, 3, 5, 7, 10, 14 &21 DPI. After 24 hours 10 % formalin solution was discarded, and freshly prepared 10 % neutral buffered formalin was used for proper fixation of tissue samples.

Histopathological examination

Liver tissue sections were subjected to processing after proper fixation. Tissues were washed overnight in running tap water, dehydrated in ascending grades of alcohol, cleared in benzene and embedded in paraffin as per the standard protocol[11]. Around 3-5 µ thick sections were obtained using a microtome (MICROM, Germany). The sections obtained were stained using routine Haematoxylin and Eosin stain (H&E).

Re-isolation of *Salmonella enterica* serovar Typhimurium

The re-isolation of the *Salmonella* Typhimurium was done by taking swabs from the liver of the birds sacrificed at different intervals. The swabs were taken under aseptic conditions and were later streaked on BGA plates. The streaked plates were incubated for 24 to 48 hours at 370C and bacterial growth was examined.

Statistical analysis

The data related to the body weight, biochemical values, gross and microscopic lesions scoring was subjected to one-way and two-way ANOVA by the GraphPad Prism version 9. Data was presented by mean ± S.E.M. level of significance at $p^* \leq 0.05\%$, $p^{**} \leq 0.01\%$, $p^{***} \leq 0.001\%$ and $p^{****} \leq 0.0001\%$ (One-way ANOVA and two-way-ANOVA followed by Tukey's multiple comparison test).

RESULTS

***In vitro* experimental study**

The percent recovery of *Saussurea costus* roots was found to be 6%. The methanolic extract of *Saussurea costus* roots exhibited the most potent antibacterial potential with a zone of inhibition of 10.0 mm (Fig.1). S*almonella enterica* serovar Typhimurium expressed maximum sensitivity for Levofloxacin, followed by Enrofloxacin & Ceftriaxone. It was found to be resistant to Oxytetracycline.

Clinical symptoms, mortality pattern, and body weight gain

The birds in groups I (plain control) and group VI (plant extract only) were completely healthy and didn't express any clinical signs of illness throughout the experiment. The clinical signs were mainly observed in the birds of groups II, III, IV, and V. On day 1 post-infection, there was a slight reduction in the feed and water intake of the birds in group II which were given *Salmonella enterica* serovar Typhimurium infection alone. The clinical signs were seen progressing with

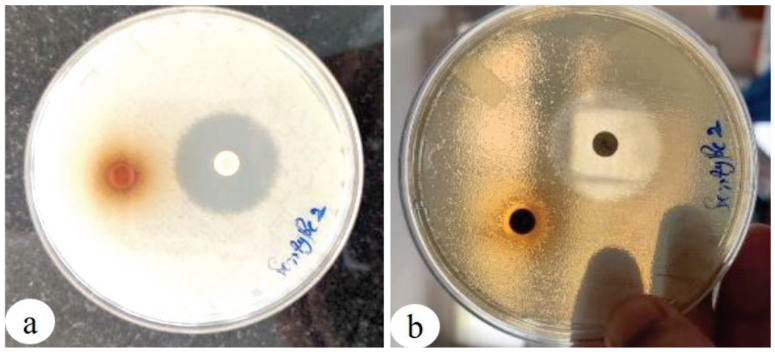

Fig. 1. (a) Photograph depicting the zone of inhibition exhibited by the methanolic extract of roots of *Saussurea costus* against *Salmonella enterica* serovar Typhimurium; **(b)** Photograph depicting the zone of inhibition by the standard antibiotic Levofloxacin.

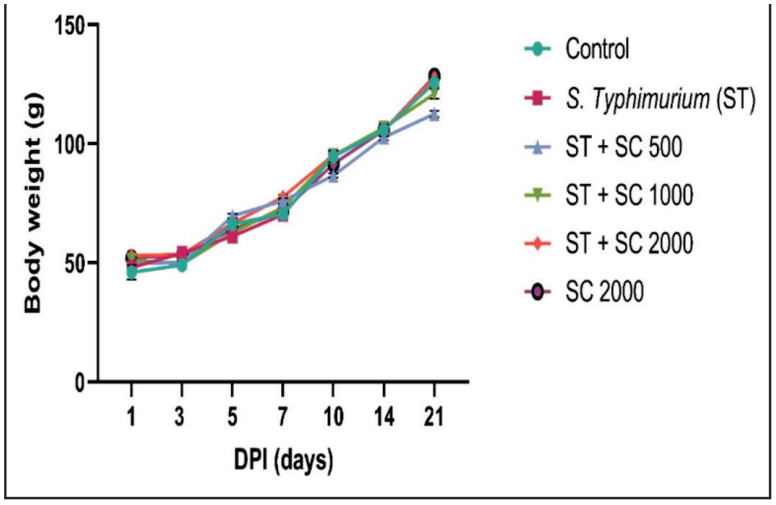

Fig. 2. Effect of different treatments on the body weight of chickens in various treatment groups. Data represent mean ± S.E.M. (n=50) level of significance at p* ≤ 0.05%, p** ≤ 0.01%, p*** ≤ 0.001% and p**** ≤ 0.0001%.

the subsequent days post-infection in group II given infection alone. On day 3 post-infection, the birds in group II showed signs of huddling near the source of light, somnolence, ruffled feathers, greenish-yellow diarrhoea, and reduced feed and water intake. In the present experimental trial, the clinical signs were seen at peak from day 3 to 10 DPI and then gradually tended to decrease but were observed upto 14 DPI with varying intensity. The onset of the clinical signs is attributed to toxaemia produced by the *Salmonella* when it reaches the systemic circulation. The severity of the clinical signs was decreased in the groups treated with the methanolic extracts of *Saussurea costus* roots i.e. groups III, IV, and V. The majority of the clinical signs like ruffled feathers, huddling near the source of light, somnolence, and reduced feed and water intake with soiling of the vent were observed on 3 DPI. The clinical signs were observed upto 10 DPI, but the severity of the signs was significantly decreased in these groups and were seen occasionally at 10 DPI. From 10 DPI onwards, the birds in the groups treated with methanolic extract of *Saussurea costus* roots appeared normal.

In the present experimental study, no mortality was observed in the birds of groups I (plain control) and VI (plant extract only). Mortality was observed and recorded in the birds of groups II, III, IV and V. The peak mortality was observed in infection groups from 1DPI to 3DPI; thereafter, there was a decline in the mortality pattern, though it continued up to 14 DPI. Mortality in the treated groups (III, IV, and V) was lower as compared to the group given infection alone (group II). No mortality was observed in various infected groups after 10 DPI.

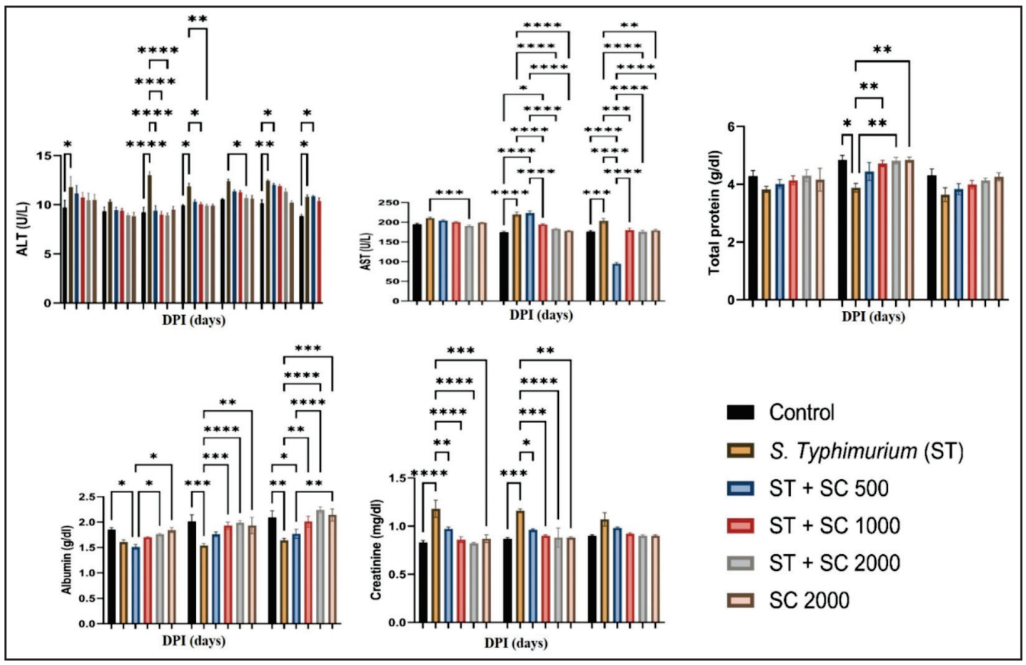

Fig. 3. Effect of different treatments on the serum biochemical parameters of chickens in various treatment groups. Data represent mean ± S.E.M. (n=50) level of significance at p* ≤ 0.05%, p** ≤ 0.01%, p*** ≤ 0.001% and p**** ≤ 0.0001%.

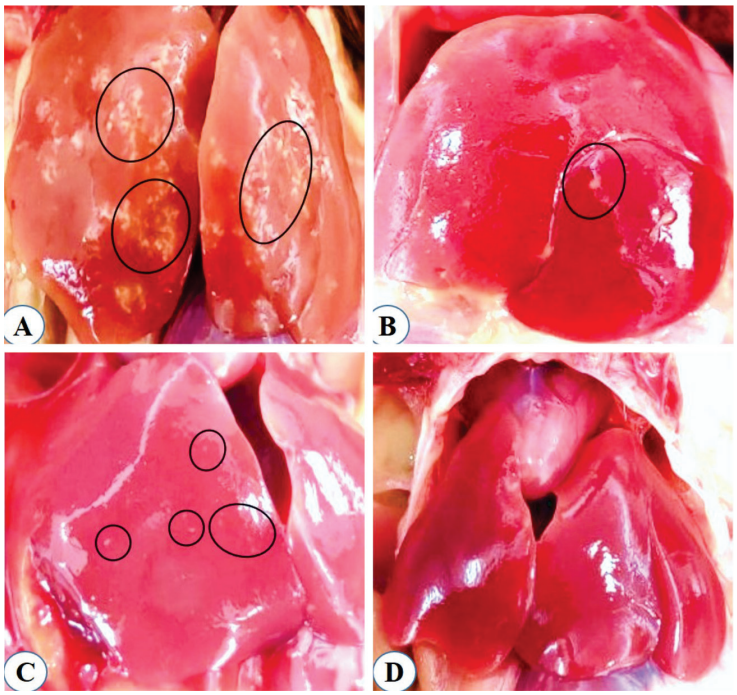

Fig. 4. Gross pathology depicting the effect of different treatments on the liver of poultry birds. **(A)** Positive control group II with severe areas of coagulative necrosis; **(B)** Group III treated with *Saussurea costus* exhibiting multifocal necrotic lesions; **(C)** Group IV treated with *Saussurea costus* reflecting few necrotic foci; **(D)** Group V treated with *Saussurea costus* showing almost normal hepatic parenchyma.

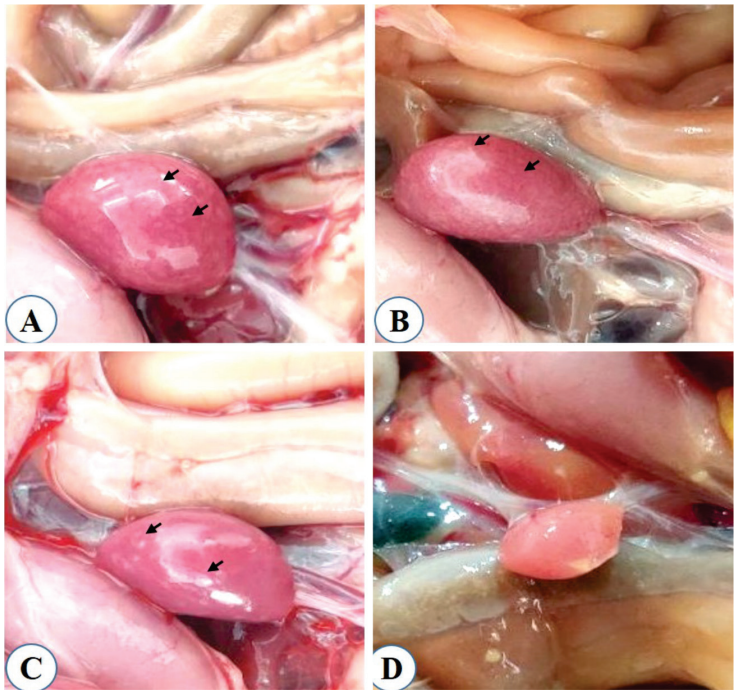

Fig. 5. Gross pathology depicting the effect of different treatments on the spleen of poultry birds. **A.** Positive control group II with multifocal areas of necrosis. **B.** Group III treated with *Saussurea costus* exhibiting multifocal necrotic lesions. **C.** Group IV treated with *Saussurea costus,* reflecting the presence of a few necrotic foci. **D.** Group V treated with *Saussurea costus* showing almost normal spleen.

Overall, there was a rational increase in the body weight of birds with the progression of the experimental trial in all the groups. The mean body weight values were higher in groups IV, & V in comparison to group II throughout the trial period. At 5, 7 and 21 DPI, a significant ($P \leq 0.05$) increase in the body weight of birds in group V was observed in comparison to birds in group II (Fig. 2).

Biochemical changes

The mean serum ALT activity in group II (plain infection) was highest in comparison to the other infected groups (III, IV, and V) at different time intervals. The serum ALT values were highest in infected groups as compared to the control groups I (plain control) and VI (plant extract only). At 5, 10 and 21 DPI, there was a significant ($P \leq 0.05$) difference in the value of ALT in the plain infected group (II) from those of various treated groups. The ALT values of both the groups I and VI were in similar ranges depicting no adverse effect of methanolic root extract of *Saussurea costus* on the liver.

The mean serum AST activity in group II (plain infection) was highest in comparison to the other infected groups (III, IV, and V) at different time intervals. The lowest serum AST activity was observed in groups IV, and V as compared to group II. A significant ($P \leq 0.05$) difference in the values of the AST in different treatment and infection groups was observed at 1, 5, 7, 10 and 21DPI. The AST values in the group SD were more or less close to that of group I depicting no adverse effect of methanolic extract of *Saussurea costus* roots.

The mean value of serum creatinine at 1, 3, 5, 7, 10 and 14 DPI was found to be significantly ($P \leq 0.05$) slightly elevated in group II than in other groups. No significant changes in the creatinine values were recorded in groups III, IV, & V representing the protective effect of the methanolic extract of *Saussurea costus* roots on the kidneys. A significant ($P \leq 0.05$) increase in the value of serum total protein in group V was observed on 3, 7 and 14 DPI in comparison to group II. The value of total protein in groups (IV, & V) was found to be in similar ranges when compared to those in groups (I, & VI). The total protein values were lowest in group II in comparison to the various treatment groups (Fig. 3).

Gross pathology

No visible gross pathology was observed in groups I and VI. Hepatomegaly accompanied

by necrotic foci was the most consistent gross finding in group II throughout the experimental trial. At 1 DPI, hepatomegaly was characterised by rounding of the edges of the liver along with the sinusoidal dilation. These lesions were seen to increase in intensity with the progression of the experimental trial. At 3 DPI, necrotic foci on the liver parenchyma were evident which tend to increase in severity upto 10 DPI. At 3, 5, 7 & 10 DPI multifocal to coalescing, variable-sized, creamish to off-white-coloured necrotic foci were recognisable on the caudodorsal surface of the liver. From 14 & 21 DPI, onwards there was a significant decline in the intensity of visible lesions, especially necrotic foci.The positive control group II showed severe necrosis of liver and spleen at different time intervals and the gravity of necrotic lesions was redued in the groups treated with *Saussurea costus* root extract (Figs. 4 & 5).

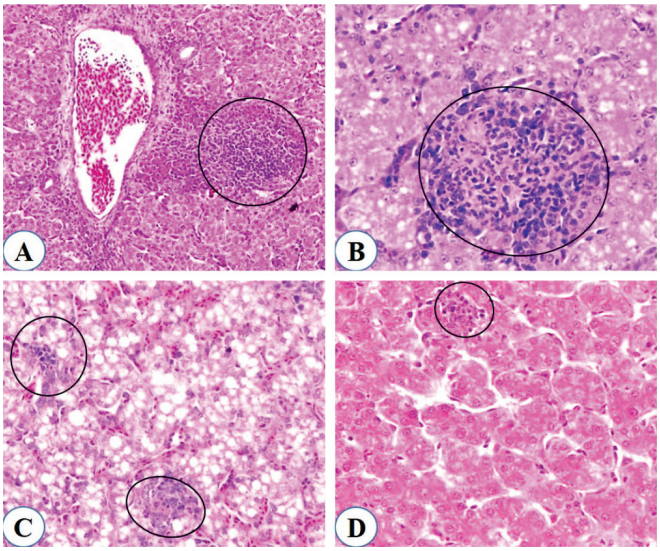

Fig. 6. Histopathology depicting the effect of different treatments on the liver of poultry birds. **(A)** Positive control group II with moderate perivascular infiltration of inflammatory cells in the necrotic area (encircled) (H&E x10); **(B)** Group III treated with *Saussurea costus* exhibiting necrotic foci with lymphocytes (encircled) and increased Kupffer cell activity (H&E x20); **(C)** Group IV treated with *Saussurea costus*, reflecting the presence of multifocal areas of necrosis (encircled) with sinusoidal congestion and fatty degeneration (H&E x20); **(D)** Group V treated with *Saussurea costus* showing mild necrosis. (H&E x20).

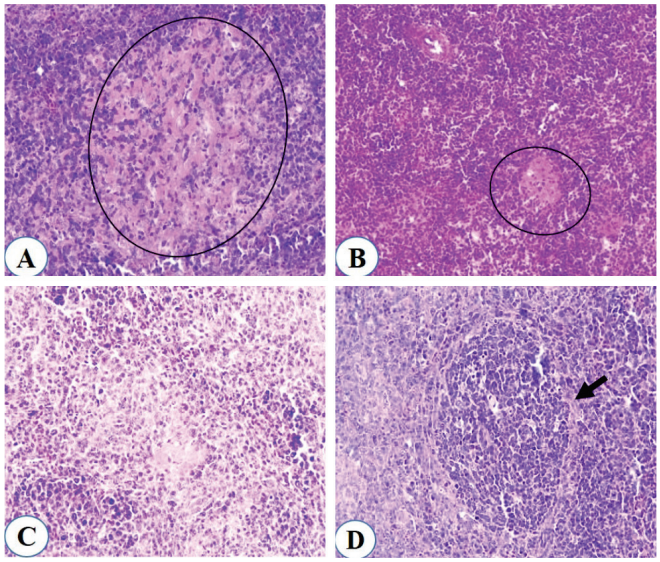

Fig. 7. Histopathology depicting the effect of different treatments on the spleen of poultry birds. **(A)** Positive control group II with focal necrotic foci (encircled) with moderate white pulp hyperplasia (H&E x20); **(B)** Group III treated with *Saussurea costus* exhibiting a focal necrotic area (encircled) (H&E x10); **(C)** Group IV treated with *Saussurea costus*, reflecting the presence of near to normal intact follicle in association with surrounding reticuloendothelial cell hyperplasia (H&E x20); **(D)** Group V treated with *Saussurea costus* with near to normal lymphoid follicle (arrow) (H&E x40).

The histopathological examination of the liver in group II (*Salmonella* Typhimurium infection only) comprised of severe multifocal areas of necrosis, infiltration of heterophils and lymphocytes, sinusoidal dilation, degenerative changes and increased cellular granularity. The microscopic lesion score intensity was highest in group II on 5, 7 & 10 DPI. In groups IV, & V on 10, 14 & 21 DPI, the liver was found to be normal and there was a dose-dependent decline in the severity of occurrence of lesions. The liver was devoid of areas of necrosis, and infiltration of inflammatory cells and few degenerative changes were observed along with sinusoidal congestion (Fig. 6). Severe homogenous eosinophilic areas of necrosis, reticuloendothelial cell hyperplasia, depletion of lymphoid follicles and blood-filled sinuses were present in the spleen in group II as compared with other treatment groups (Fig. 7). In the heart from 3 to 7 DPI severe fibrinous pericarditis and

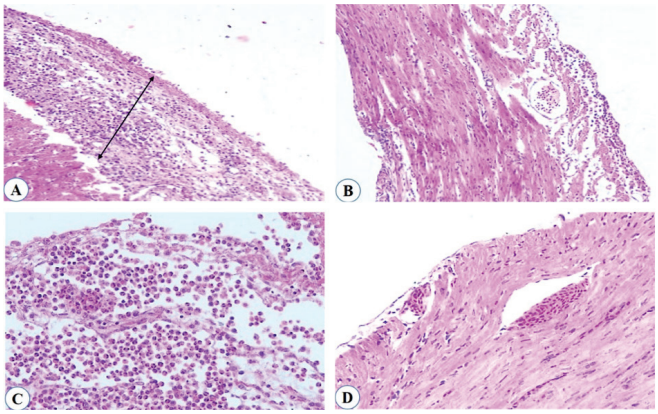

Fig. 8. Histopathology depicting the effect of different treatments on the heart of poultry birds. **(A)** Positive control group II showing severely thickened pericardium with infiltration of heterophils (arrow) (H&E x10); **(B)** Group III treated with *Saussurea costus* exhibiting mild fibrinous pericarditis along with heterophils population (H&E x10); **(C)** Group IV treated with *Saussurea costus* showing thickened pericardium, fibrin and infiltration of heterophils (H&E x20); **(D)** Group V treated with *Saussurea costus* showing near to normal cardiac parenchyma (H&E x10)

infiltration of heterophils and lymphocytes was found. In group III similar lesions were recorded but the intensity of the lesions was reduced in comparison to group II on 5, 7 & 10 DPI. The severity and intensity of lesions in groups IV, & V were reduced and the maximum intensity of lesions was observed upto 7 DPI (Fig. 8).

DISCUSSION

Salmonella is a facultative intracellular pathogen and causes both systemic and acute localized infections whereas chronic infections appear as an asymptomatic carrier state[12]. Fowl typhoid and pullorum disease are septicaemic diseases which are caused by *Salmonella* Gallinarum and *Salmonella* Pullorum, respectively in poultry. *Salmonella enterica* serovar Typhimurium is a bacterial pathogen that causes food poisoning and gastroenteritis in millions of people worldwide each year[4]. *Salmonella enterica* serovar Typhimurium causes food poisoning in humans, and infection also leads to bacteraemia causing cardiovascular, bone and joint infections in humans[13,14]. Eggs are the major vehicle of *Salmonella* transmission and there are mainly two ways through which eggs get infected. Either *Salmonella* infects the ovaries of healthy hens and contaminates the eggs or droppings from the infected birds contaminate the outer shells of eggs and penetrate when shells are cracked[15].

Abdalkareem et al.[16] have shown the antibacterial effect of the methanolic extract of *Saussurea costus* against human bacterial pathogens (*Bacillus cereus, Staphylococcus aureus, Escherichia coli* and *Pseudomonas aeruginosa*) at different concentrations ranging from 6.25 mg/ml to 100 mg/ml. The maximum activity was observed at a concentration of 100 mg/ml against *Bacillus cereus* and *Staphylococcus aureus*, with zones of inhibition of 26 mm and 25 mm, respectively. Khalid et al.[17] demonstrated the antimicrobial activity of three different extracts (methanolic, cold water and hot water) of costus roots against *Staphylococcus aureus, Pseudomonas Aeruginosa, Bacillus subtalis, Salmonella typhi* and *Enterococcus faecalis*. There were no clinical signs in the plain control group, and the intensity of signs among infected groups was least in the group V as compared to other groups. The mortality rate was found to be highest in group II in comparison to other groups III, IV, & V, and no mortality was recorded in groups I & VI. Body weight was minimal in group II and highest in group V treated with the highest dose of plant extract. In the previous studies, the birds have also been shown to exhibit signs of reduced feed and water intake, huddling near the source of light, ruffled feathers and greenish-yellow diarrhoea when infected with *Salmonella* organism[18]. The onset of the clinical signs is attributed to toxaemia produced by the *Salmonella* when it reaches the systemic circulation. The bacterium-mediated phagocytosis, recruitment of neutrophils, cytokine secretion and imbalance in electrolytes are some of the mechanisms of pathogenesis[19]. *Salmonella* can produce both endotoxins as well as exotoxins and the endotoxins are known to produce a variety of biological responses. In contrast, exotoxins consisting of cytotoxins and enterotoxins can kill host cells[20].

The serum biochemical examination revealed that ALT & AST values were significantly elevated while total protein and albumin were lower in concentration in the plain infection group (II) as compared to the control group (I). The values of biochemicals (ALT, AST, total protein, albumin and creatinine) among different treatment groups SA, SB & SC were generally significantly lowered as compared to the group II (*Salmonella* Typhimurium infection only) suggesting an *in vivo* protective effect of 80 % methanolic root extract of *Saussurea costus* against the pathology of infection. The findings are per the results of Shah et al.[21]; Chiroma et al.[18]; and Abou Zeid et al.[22] who found that the ALT values were elevated in *Salmonella*-infected groups during their experimental studies. The elevated values in different infected groups could be attributed to the hepatocellular damage done by the organism. Alnahdi et al.[23] studied the hepatoprotective effect of methanolic extract of *Saussurea costus* against deltamethrin-induced liver toxicity in albino rats. Kadhem[24] performed a study on rabbits to investigate the effect of aqua-ethanolic extract of *Saussurea costus* against hepatic and renal toxic effects of paracetamol toxicity. The paracetamol was administered @ 300 mg/Kg body weight for 14 days and the effect of *Saussurea costus* was studied with a dose of 300 mg/Kg bw.

The gross pathology comprised of hepatomegaly, necrotic foci, liver paleness, splenomegaly and fibrinous pericarditis were reduced in *Saussurea costus* treated groups as compared with group II. No visible gross pathology was observed in groups I, and VI. In the present study based on the gross pathology and lesions intensity score a dose-dependent effect of the 80% methanolic root extract of *Saussurea costus* was evident. The group treated with the highest dose of the extract expressed a significant reduction in gross pathology which was more or less comparable with the control group I.

The histopathological examination of the liver in group II (*Salmonella* Typhimurium infection only) comprised severe multifocal areas of necrosis, infiltration of heterophils and lymphocytes, sinusoidal dilation, degenerative changes and increased cellular granularity. In groups IV, & V , the liver was found to be normal and there was a dose-dependent decline in the severity of occurrence of lesions. Kumar et al.[25] conducted an experimental trial in Japanese quail to study the pathology of *Salmonella* Typhimurium infection. Grossly, they recorded splenomegaly, hepatomegaly, granular appearance of the liver and fibrinous pericarditis.

Histopathological changes recorded were fatty degeneration and heterophils accumulation in the liver, reticuloendothelial hyperplasia in the spleen, catarrhal enteritis and hyalinization of lymphoid follicles.

The present study has evaluated the hepatoprotective effect of *Saussurea costus* root extract against *Salmonella* Typhimurium infection, although a definitive mechanistic confirmation would require targeted evaluation of antioxidant defence systems, xenobiotic-metabolising enzymes, and inflammatory signalling pathways such as NF-Kb.

CONCLUSION

In conclusion, the methanolic root extract of *Saussurea costus* exhibited maximum antibacterial activity against *Salmonella enterica* serovar Typhimurium at a 100 mg/ml concentration in an *in vitro* experimental study. *Saussurea costus* root extract has shown a significant reduction in the serum biochemical parameters (ALT, AST, TP, and Albumin) in the treatment groups indicating its hepatoprotective activity. The 80% methanolic *Saussurea costus* root extract exhibited anti-bacterial activity against pathogenic *Salmonella enterica* serovar Typhimurium indicated by the reduction in the gravity of gross and microscopic pathological lesions such as necrosis, inflammatory cells infiltration & fibrinous pericarditis in different organs. In a nutshell, the present study suggests that *Saussurea costus* root extract is a potential plant to combat bacterial organisms and express a good antibacterial activity and create a scope to explore its active principles further for the treatment/prevention of various bacterial infections along with its exact mechanism of action.

ACKNOWLEDGEMENTS

Authors thank the administration of CSK HPKV, Palampur, Himachal Pradesh, India, and the Director, CSIR-Institute of Himalayan Bioresource Technology, Palampur, Himachal Pradesh, 176061, India for infrastructural support.

Financial support & sponsorship*:* None

Conflict of interest : None

Use of artificial intelligence (AI)-assisted technology for manuscript preparation: The authors confirm that there was no use of AI-assisted technology for assisting in the writing of the manuscript and no images were manipulated using AI.

REFERENCES

1. BAHS (Basic Animal Husbandry Statistics). 2019. Department of Animal Husbandry, Dairying and Fisheries, Government of India. pp. 10.
2. Rajkumar U, SV Rama Rao and RP Sharma. 2010. "Backyard Poultry Farming changing the face of rural and tribal livelihoods." *Ind Farming* **60 (2).**
3. Geetha M and KM Palanivel. 2018. "A Brief Review on Salmonellosis in Poultry". *Internatl J of Current Microbiol and Appl Sci* **7 (5):** 1269-1274. DOI: https://doi.org/10.20546/ijcmas.2018.705.153
4. Grassl GA, Y Valdez, KSB Bergstrom, BA Vallance and BB Finlay. 2008. "Chronic enteric *Salmonella* infection in mice leads to severe and persistent intestinal fibrosis". *Gastroenterol* **134 (3**): 768–780.
5. Ayesha K, MS Mehmood, I Hussain F, Siddique A Rafique and ZR Abbas. 2014. "Bacteriological and epidemiological investigation of pullorum disease in selected poultry farms of Faisalabad, Pakistan". *Global Veterinaria* **12 (4)**: 455-460.
6. Coburn B, GA Grassl and BB Finlay. 2007. "*Salmonella* the host and disease: a brief review*," Immunol and Cell Biol* **85 (2)**: 112–118.
7. Gupta PD and TJ Birdi. 2017. "Development of botanicals to combat antibiotic resistance". *J of Ayurv and Integrat Med* **8 (4):** 266–275
8. Liu ZL, Q He, SS Chu, CF Wang, SS Du and ZW Deng. 2012. "Essential oil composition and larvicidal activity of *Saussurea lappa* roots against the mosquito *Aedes albopictus* (Diptera: Culicidae)". *Parasitol Res* **110(6)**: 2125–2130
9. Negi JS, VK Bisht, AK Bhandari, CP Kuniyal, VP Bhatt and R Bisht. 2014. "Chemical fingerprinting and antibacterial activity of *Saussurea lappa* Clarke". *Appl Biochem and Microbiol* **50 (6)**: 588–593
10. Reed LJ and H Muench. 1938. "A simple method of estimating fifty percent endpoints". *The Am J of Hyg* **27**: 493–497
11. Luna LG. 1968. "Manual of Histological Staining Methods". Armed Forces Institute of Pathology. New York, NY: McGraw Hill Book Company.
12. Shivaprashad HL. 1997. "Pullorum disease and fowl typhoid. In: *Diseases of Poultry*, 10th ed. (BW Calnek *et al*., eds.)", lowa State University press, Ames, IA, USA. 82-9.
13. Bohez L, R Ducatelle, F Pasmans, N Botteldoorn, F Haesebrouck and F Van Immerseel. 2006. "*Salmonella enterica* serovar Enteritidis colonization of the chicken caecum requires the HilA regulatory protein". *Vet Microbiol* **116**: 202–210.
14. Lan R, G Stevenson, K Donohoe, L Ward and PR Reeves. 2007. "Molecular markers with potential to replace phage typing for *Salmonella enterica* serovar Typ himurium. *J of Microbiol Meth* **68**: 145–156.
15. Deryck D and Pattron. 2004. "Scientific status summary on bacteria associated with foodborne diseases and also related to public health significance of Salmonella in institute of food technologists", Chicago.
16. Abdalkareem M, M Aldaw, E Ismail, A Alyaa Abu and K Eitha. 2017. "Evaluation of antimicrobial activity of different solvent extracts of *Saussurea lappa". World Journal of Pharmacy and Pharmaceut Sci* **6 (9)**.
17. Khalid A, U Rehman, A Sethi, S Khilji, U Fatima, MI Khan, MK Waqas, QN Saqib, MHHB Asad, K Farzana, S Mahmood, A Waseem, T Ismail and G Murtaza. 2011. "Antimicrobial activity analysis of extracts of *Acacia modesta, Artimisia absinthium, Nigella sativa* and *Saussurea lappa* against Gram positive and Gram negative microorganisms". *African J of Biotech* **10 (22)**: 4574-4580.
18. Chiroma MA, S Adamu, JJ Gadzama, KAN Esievo, H Abdulsalam, AG Balami, JE Samson, Y Muhammad and AJ Atata. 2017. "Some plasma biochemical changes in layers experimentally infected with *Salmonella* Gallinarum". *African J of Cellu Pathol* **9 (2)**: 66-72.
19. Berhanu G and F Abdisa. 2020. "Pullorum disease and fowl typhoid in poultry: a review." *British J of Poul Sci* **9**: 48-56.
20. Foley SL, TJ Johnson, SC Ricke, R Nayak and J Danzeisen.

2013. "*Salmonella* Pathogenicity and Host Adaptation in Chicken-Associated Serovars". *Microbiology and Mol Biol Rev* **77 (4)**: 582–607

21. Shah NS, KA Shayaib, DM Mohammed, MS Masood and BA Shakoor. 2013. "Haematological and some biochemical changes in experimental fowl typhoid infection in broiler chickens". *Comp Clin Pathol* **22 (1):** 83-91
22. Abou Zeid MAM, SA Nasef, IEA Gehan and AM Hegazy. 2020. "A Field Study on Biochemical Changes Associated with *Salmonella* Infection in Ducklings". *J of World's Poult Res* **10 (2S)**: 250-262.
23. Alnahdi HS, NO Ayaz and ME Elhalwagy. 2016. "Prophylactic effect of cousts *saussurea lappa* against liver injury induced by deltamethrin intoxication". *International Journal of Clinical and Experimen Pathol* **9 (1)**: 387-394.
24. Kadhem M. 2019. "Protective of ethanolic extract of *Saussurea lappa* against paracetamol-induced hepatic and renal damage in male rabbits". *Asian J of Pharmaceu and Clin Res* **12**: 68-73.
25. Kumar S, JR Sadana and SK Mishra. 2001. "Studies on clinical signs, growth response and haematological changes of Japanese quail, (*Coturnix coturnix japonica)* infected with *Salmonella* Typhimurium". *Ind J of Poult Sci* **36 (3)**: 335-337