Indian J. Vet. Pathol., 50(4) : 370-377, 2026: DOI: https://doi.org/10.56093/35b4gy92

RESEARCH ARTICLE

Molecular epidemiology and pathobiology of Newcastle disease virus in chickens in and around Hyderabad

Pavan Kumar Sangamoni, Swathi Bora*, Ravi Kumar Yadala, L. Gopala[2], B. Raju[3] and D. Madhuri
Department of Veterinary Pathology, P.V. Narsimha Rao Telangana Veterinary University, Rajendranagar-500030, Telangana, India
[1]Department of Veterinary Microbiology,
[2]Research scientist, IgY Immunologix India Pvt Ltd, Narsingi village, Rajendranagar-500089

***Address of correspondence**
Dr. Swathi Bora, Associate Professor; E-mail: drswathibora@gmail.com
ORCID ID: 0000-0003-4141-4026

Received: 23.3.26; Accepted: 3.5.26

ABSTRACT

Newcastle disease (ND) is a highly contagious respiratory viral disease affecting various avian species caused by *avian paramyxovirus-1* (APMV-1). The present study aimed to determine the incidence, seasonal distribution, pathological alterations, and molecular prevalence of Newcastle disease virus (NDV) in chickens from different locations in and around Hyderabad. During June to November, 2025, a total of 439 dead birds from 32 poultry flocks were subjected to detailed postmortem examination. Of these, 262 birds showed respiratory lesions, among these 104 were confirmed as viral respiratory infections. The present study recorded an overall incidence of 65 cases (62.50 %) for Newcastle disease virus using RT-PCR targeting F gene. Grossly, affected birds showed pulmonary oedema and congestion of lungs. Trachea showed severe congestion with areas of haemorrhages and air sacs were thickened and cloudy. Microscopically, lesions include tracheal epithelial hyperplasia, deciliation, necrosis, degeneration, vascular congestion and mononuclear infiltration within the lamina propria, mucosa and submucosa. Lung exhibited edema, congestion, bronchial deciliation, heterophilic plugs and epithelial thickening of parabronchi. Viral isolation was carried out in embryonated chicken eggs through the Allantoic cavity route for isolation of the virus and confirmed using RT-PCR. Flock wise analysis revealed that, out of 32 flocks screened, 13 (40.63%) flocks were found positive for NDV. Seasonal wise incidence showed that NDV predominant throughout the study period with higher winter occurrence than the rainy season. Bidirectional sanger sequencing of the 304 bp F gene amplicon revealed >95% nucleotide identity confirming the isolates as Avian paramyxovirus-1 (NDV).

Key words: Egg inoculation, Histopathology, Incidence, Newcastle disease, RT-PCR

INTRODUCTION

New castle disease, also termed as fowl plague is a highly contagious viral disease affecting various avian species[1]. The disease caused by *avian paramyxovirus-1* (APMV-1), a negative sense RNA virus of the genus *Orthoavulavirus*, infecting numerous domestic and wild birds. The virus targets respiratory, nervous, digestive and lymphoid system[2]. It was first documented in 1926 with outbreak noticed in Java, Indonesia and later in Newcastle, England[3]. In India, initial outbreak of NDV occurred in 1927 at Ranikhet in Uttarakhand[4]. The genome of virus consists of nucleocapsid, phosphoprotein, matrix, fusion, haemagglutinin-neuraminidase, and RNA polymerase genes which are essential for virus application, with the fusion (F-protein) cleavage site serving as a key marker of virulence and tissue tropism[5]. The pathogenicity of NDV is determined by the amino acid sequence at the unprocessed F protein cleavage site[6]. Based on F gene nucleotide sequences, NDVs are grouped into class I and class II. Class I NDVs mainly occur in wild birds with low virulence, while class II strains predominate in domestic poultry and typically more pathogenic[4]. NDV categorized into viscerotropic velogenic (Doyle), neurotropic velogenic (Beach), mesogenic (Beaudette), lentogenic (Hitchner), and asymptomatic enteric pathotypes based on virulence and clinical presentation[7].

The virus infects more than 240 bird species, notably domestic poultry-chickens, ducks, turkeys, guinea fowl, quail and pigeons[8]. Waterfowl and wild birds serve as natural reservoirs of NDV[9]. The disease transmission is through oral or aerosol inhalation with a incubation period of 1–3 days[10, 11]. Definitive diagnosis is based on detecting viral antigens, either through virus isolation from swabs or organs using hemagglutination inhibition or molecular methods. The virus can be cultured in cell lines such as African green monkey kidney cells, hepatocytes and chicken embryo fibroblasts[1].

How to cite this article : Sangamoni, P.K., Bora, S., Yadala, R.K., Gopala, L., Raju, B. and Madhuri, D. 2026. Molecular epidemiology and pathobiology of Newcastle disease virus in chickens in and around Hyderabad. Indian J. Vet. Pathol., 50(4) : 370-377.

MATERIALS AND METHODS

Location and duration of the work

The research work has performed at Department of Pathology, College of Veterinary Science, Rajendranagar and IgY Immunologix India Pvt Ltd, located in Narsingi, Hyderabad. Sample collection, processing and interpretation of research work was conducted for a period of six months from June 2025 to November 2025.

Collection of samples

In the present investigation, a total of 439 dead birds were submitted for necropsy from various poultry flocks located in and around Hyderabad and were subjected to a detailed postmortem examination. Birds that exhibited gross respiratory lesions during necropsy were selected for subsequent pathological and molecular investigation. The collected samples were then divided into two sets – one portion of tissue was fixed in 10% neutral buffered formalin for histopathological examination, while the other portion of tissue was collected in Viral Transport Medium (VTM) was prepared using Dulbecco's Modified Eagle Medium (DMEM) as the base, and fetal bovine serum (FBS) was added to a final concentration 5% (v/v) to stabilize viral particles during transport and storage. To prevent bacterial and fungal contamination, the medium was supplemented with gentamicin (50 µg/mL), ciprofloxacin (10 µg/mL), and amphotericin B (10 µg/mL). The final VTM was filter-sterilized (0.22 µm) and stored at 4°C until use for molecular analysis. All collected specimens were properly labelled, documented, and transported to the Department of Veterinary Pathology under refrigerated conditions to prevent decomposition and preserve diagnostic quality.

Gross pathology

Submitted dead birds were subjected for detailed necropsy examination as per standard procedure. Gross lesions were recorded in larynx, trachea and lungs along with other organs for diagnostic correlation.

Histopathology

Based on gross examination of the respiratory lesions and in correlation with lesions on other organs, relevant sample were collected in 10% neutral buffered formalin, washed with PBS, and dehydrated through graded ethanol (70-100%). Tissues were then cleared in xylene and embedded in paraffin at 55-65°C. Thin sections of 5µ thick were cut, placed on clean slides coated with Mayer`s egg albumin, stained by H&E and viewed microscopically[12]. Histopathological scoring of tracheal and pulmonary lesions of ND was performed following the criteria described[13].

Egg inoculation

Tissue samples were finely minced and triturated with sterile sand in a mortar pestle under aseptic conditions in the virology laboratory. A 10% (w/v) organ suspension was prepared in viral transport medium. The homogenate was transferred to sterile tubes and centrifuged at 3000 rpm for 20 minutes at 4°C. The resulting supernatant was collected and passed through a 0.45 µm filter. Fertile eggs were incubated at 37.5°C for nine days prior to inoculation. Viability of embryos was confirmed by candling in a dark room, and the boundaries of the air cell were marked to identify the inoculation site. Eggs showing no embryonic growth were included. Shell surface was disinfected with ethanol, after which a small opening was made at the marked region using a sterile drill, without damaging the underlying membranes. Using a sterile 1mL syringe with a fine gauge needle, 0.1 mL of the virus suspension was injected through the shell and chorioallantoic membrane into the allantoic cavity. The perforation was sealed with sterile wax or adhesive tape, and the eggs were incubated at 37.5°C for 2-4 days and examined every 24 hours by candling to monitor embryo viability. Subsequently, allantoic fluid was collected and embryos were examined in sterile petri dishes for cytopathic changes.

Molecular detection of different viral respiratory agents by PCR

Total RNA was extracted from tissues stored at −20 °C in viral transport medium. Briefly, approximately 50 mg of tissue was aseptically placed in a DNase- and RNase-free 1.5 mL microcentrifuge tube containing 1 mL of TRI Reagent® (Sigma-Aldrich, Cat. No. T9424) and 1 unit of RNase Inhibitor (SRL Chemicals, Sisco Research Laboratories, Cat. No. 62030). The tissue was homogenized using a sterile motorized homogenizer until a uniform suspension was obtained. The homogenate was incubated at room temperature for 15 min to facilitate complete lysis and dissociation of nucleoprotein complexes. Subsequently, 200 µL of chloroform was added, and the mixture was vortexed thoroughly for 15–30 s. The mixture was incubated at room temperature for 15 min and then centrifuged at 12,000 g for 15 min at 4°C.

The aqueous phase containing RNA was carefully recovered and precipitated by adding 500 µL of isopropanol, followed by incubation at room temperature for 15 min. The mixture was centrifuged at 12,000 g for 15 min at 4 °C to pellet the RNA. The RNA pellet was washed once with 75% ethanol prepared in DEPC-treated water and centrifuged at 7,500 g for 5 min. After removing the ethanol, the pellet was air-dried and resuspended in 50 µL of nuclease-free water, followed by incubation at 60 °C for 5 min. The extracted RNA and DNA concentration and purity (A260/280) were measured using a FLUO star Omega filter-based multi-mode microplate reader.

Complementary DNA was prepared by reverse transcription using the First Strand cDNA Synthesis Kit

(Quick Protocol, NEB #M0277). The reaction mixture was incubated at 25 °C for 5 min to allow primer annealing, followed by 42 °C for 1 hour for cDNA synthesis. The enzyme was inactivated by incubating at 85 °C for 5 min. The synthesized cDNA was then used for downstream PCR applications.

PCR amplification was performed using a thermal cycler (Heal Force Touch) using PowerPol 2X PCR Mix with Dye V2 (Cat. No. RK20729). For amplification of NDV-F gene, RT-PCR began with initial denaturation at 98°C for 1minute, followed by 30 cycles consisting of denaturation at 98°C for 10 sec, annealing at 55°C for 30 sec, and extension at 72°C for 1 min, with a final extension step at 72°C for 5 minutes and hold for indefinite time at 4°C. Primers targeting the Fusion (F) gene of Newcastle Disease Virus (NDV; *Avian paramyxovirus-1*) were used. The forward primer (NDV-F) sequence was TACACCTCATCCCAGACAGG and the reverse primer (NDV-R) was AGTCGGAGGATGTTGGCAGC, yielding an expected amplicon of approximately 304 bp[14]. These primers specifically amplify the negative-sense single-stranded RNA (ssRNA) genome region corresponding to the F gene.

RESULTS

Incidence

During the study period, postmortem examinations were performed on a total of 439 dead birds presented to Department of Veterinary Pathology from various farms in and around Hyderabad. Among these, 262 birds exhibited gross lesions suggestive of respiratory diseases, 104 were confirmed to have viral respiratory infections. Among the 104 positive cases of viral respiratory infections in chickens, NDV was the major important pathogen detected in the present investigation, accounting for nearly two-thirds of the positive (65) cases with an incidence rate of 62.5%.

The investigation included sampling from 32 poultry flocks. The flocks varied in scale, each flock comprised between approximately 5,000 and 20,000 birds, reflecting considerable variation in flock size. During the study period approximately 5 tissue samples (trachea or lungs) from each flock were collected, pooled together and considered as a single sample for molecular detection. Out of 32 flocks screened, 13 (40.63%) flocks were found positive for NDV.

The season wise NDV infections in chickens showed marked variation between the winter and rainy months. Detailed seasonal wise incidence was presented in Table 1. In rainy season (June - September), a total of 280 birds were subjected to necropsy. Out of these, 31 birds were positive for ND with an incidence rate of 11.07%. In contrast, during the winter months (October and November), 159 birds were subjected to detailed postmortem examination. Among these, 34 birds tested positive for ND, corresponding to a higher incidence rate of 21.38% in comparison to rainy season. NDV was identified consistently throughout the study period and remained as a predominant respiratory pathogen showing a higher occurrence in the winter season than during the rainy season.

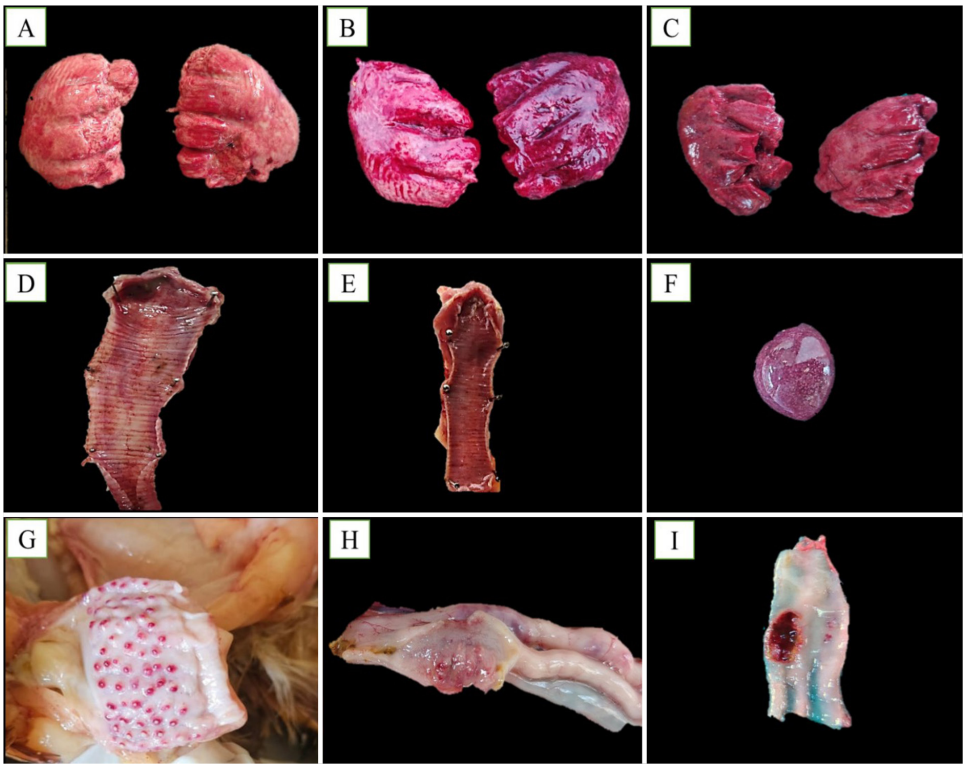

Fig. 1. Gross pathology of different organs in chicken in NDV infection. **A.** Lungs showing moderate to severe congestion. **B.** Lungs showing severe congestion appearing dark red in colour. **C.** Lungs showing moderate congestion along with edema. **D.** Trachea revealed congestion around the tracheal rings along with areas of hemorrhages. **E.** Trachea mucosa showing severe congestion and hemorrhages throughout the entire trachea. **F.** Spleen shows multiple necrotic whitish foci on its surface. **G.** Presence of pin point hemorrhages on proventricular glands. **H.** Enlarged caecal tonsils showing areas of hemorrhages. **I.** Intestinal mucosa showing circular, well demarcated, button like hemorrhagic ulcers.

Table 1. Distribution of lesion scores of tracheas and lungs for NDV

Disease	Organs	Score-1	Score-2	Score-3	Score-4	Total cases
NDV	Trachea	5	8	10	13	**36**
	Lungs	3	6	9	11	**29**

Table 2. Season wise summary of respiratory viral infections in chickens.

Season	Months covered	Total number of dead birds examined	Total number of positive birds	Incidence (%)
Rainy	June to September	280	31	11.07
Winter	October & November	159	34	21.38

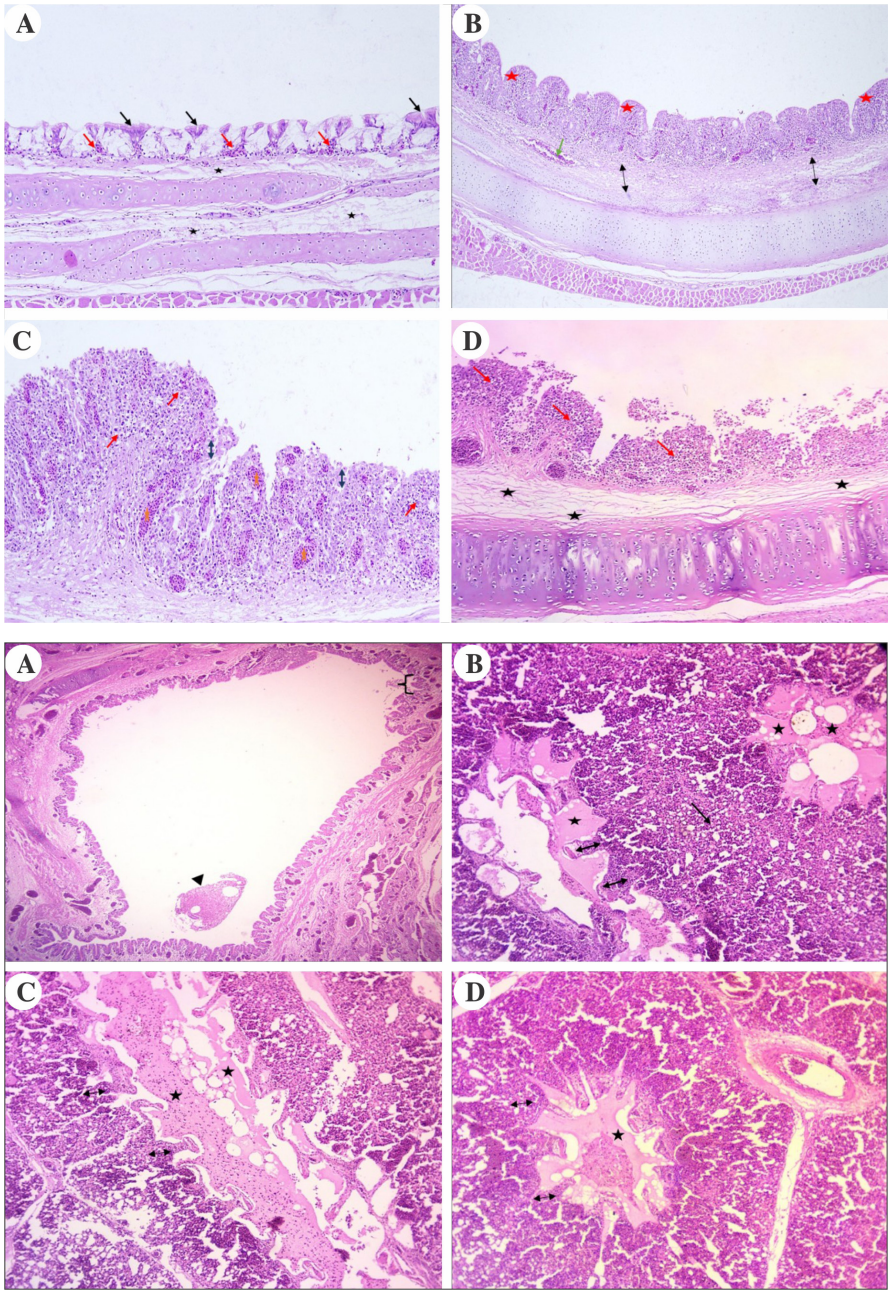

Fig 2. Microscopic alterations of trachea in NDV infection. **A.** Mild- Clumping of cilia (black arrow), Submucosal edema (black asterisk), Mild mononuclear infiltration (red arrow); **B.** Moderate- Epithelial hyperplasia (red asterisk), Mucosal thickening (double headed black arrow), vascular congestion (green arrow); **C.** Severe- mononuclear infiltration (red arrow), haemorrhage (orange asterisk), Necrosis of the epithelial cells (black double-sided arrow); **D.** Very severe- Submucosal edema (black asterisk), Multifocal loss of epithelium, mononuclear infiltration (red arrow).

Gross pathology

On gross examination, birds affected with ND exhibited pulmonary oedema and mild to severe congestion of lungs (Fig. 1, A-C). The trachea revealed severe congestion around the tracheal rings along with areas of hemorrhages (Fig. 1, D, E) and thoracic air sacs were thickened and cloudy. The spleen shows multiple necrotic whitish foci on its surface (Fig.1 F). The majority of cases showed petechial

Fig 3. Microscopic alterations of lungs in NDV infection. **A.** Mild- loss of cilia (bracket), necrotic plug in the lumen of bronchi (arrow head); **B.** Moderate- Epithelial thickening (double headed black arrow), parabronchial edema (black asterik), mononuclear infiltration (black arrow); **C.** Severe epithelial thickening (double headed black arrow), parabronchial edema admixed with inflammatory cells partly obstructed lumen (black asterik); **D.** Very severe epithelial thickening (double headed black arrow), parabronchial edema admixed with inflammatory cells completely obstructed lumen (black asterik).

hemorrhages located at the tip of the proventricular glands (Fig. 1, G). The caecal tonsils were enlarged and exhibited serosal hemorrhages with a congested, haemorrhagic mucosa (Fig.1 H). The intestinal mucosa showed oval, well demarcated, button like hemorrhagic ulcers (Fig.1, I).

Histopathology

In the present study, histopathological lesions of the trachea and lungs in ND were assessed using a lesion-scoring system, wherein score-1 denoted mild lesions, score-2 for moderate lesions, socre-3 severe lesions and score-4 very severe lesions. The detailed distribution of lesion scores is presented in Table 2.

In NDV infected birds, the tracheal mucosal epithelium showed changes ranging from mild to marked hyperplasia, deciliation and infiltration of mononuclear cells within the lamina propria, mucosa and submucosa (Fig. 2 A) In several cases, the trachea exhibited multifocal to diffuse necrosis of epithelial lining, accompanied by vascular congestion, submucosal edema and mild to moderate mononuclear infiltration (Fig. 2 B). In few birds, tracheal epithelial lining showed degenerative and necrotic changes accompanied by hemorrhage, congestion of blood vessels, mononuclear cell infiltrations and submucosal edema (Fig. 2 C-D).

The primary and secondary bronchi revealed denudation of cilia along with heterophil plug formation and mononuclear inflammatory cell infiltration around the bronchi (Fig. 3, A). In most of the cases, the parabronchi showed changes ranging from mild to severe epithelial thickening and mild to severe edema of parabronchi and atria were also observed (Fig. 3, B-D)

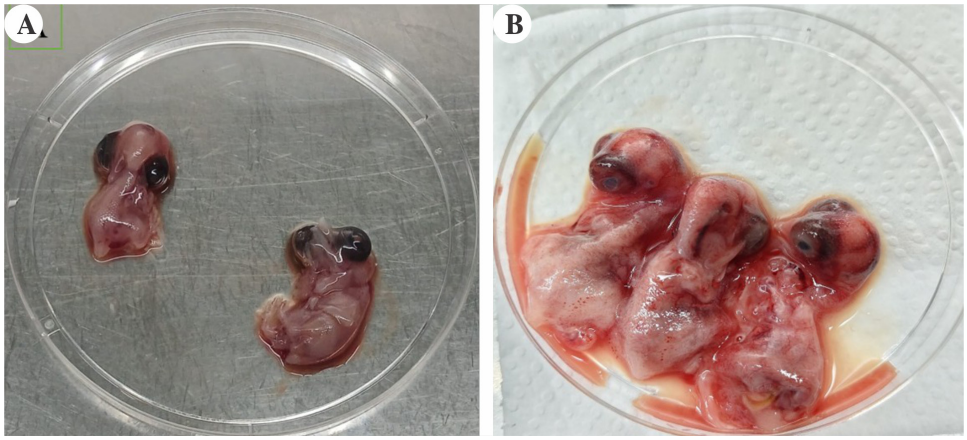

Fig 4. Gross pathological changes in NDV infected chicken embryos. A- Apparently normal embryos. B- Infected embryos showing petechial hemorrhages over the head, neck and limbs along with generalized edema

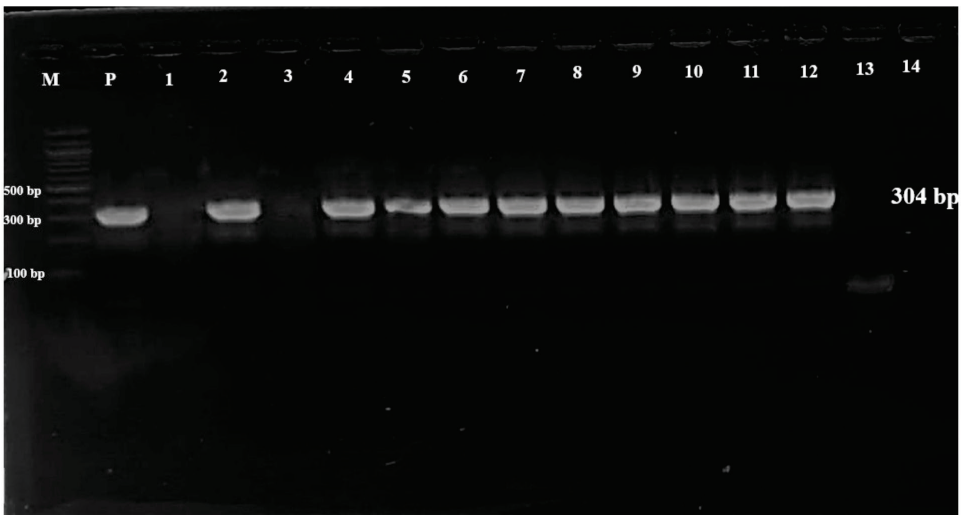

Fig. 5: Agarose gel profile illustrating F-gene- specific PCR amplicons of Newcastle disease virus. Lane M: 100 bp ladder, Lane P: Positive control; Lane 1-14: Field samples, Lane 2,4,5,6,7,8,9,10,11,12-Positive for ND

Egg inoculation

A 9-day old chicken embryo inoculated with the field strain of NDV showed marked pathological changes, including petechial hemorrhages over the head, neck and limbs along with generalized edema of the embryo (Fig.4 A, B).

Molecular detection of NDV

Among the various viral pathogens associated with respiratory infections, NDV was identified in 65 samples, accounting for an incidence of 62.5% of the 104 positive cases. To confirm the presence of NDV in the collected samples, RT-PCR was carried out using primers specific for the Fusion(F) gene. The PCR product was run on a 1.5% agarose gel along with a 100-bp DNA ladder. A distinct band around 304 bp, which matches the expected size for the targeted region of F gene, was visible in the positive samples (Fig. 5).

Nucleotide sequencing of NDV

Sanger Sequencing and Bioinformatic Analysis Bidirectional Sanger sequencing was performed

by Eurofins Genomics India Pvt. Ltd. (Hyderabad) using the same PCR primers (10 pmol/µL). The consensus nucleotide sequence was analyzed using BLASTn against the NCBI non-redundant (nr) database. Results PCR amplification yielded a clear 304-bp amplicon consistent with the expected size of the NDV F gene fragment. Sequencing confirmed the identity of the isolate, with >95% nucleotide identity to reference NDV strains (e.g., GenBank accessions PX409119.1and LC885048.1). Based on molecular evidence, the isolate was conclusively identified as Newcastle disease virus (Avian paramyxovirus 1).

DISCUSSION

In the current investigation, the study aimed for detection NDV. Among the birds examined, 104 birds were found to be positive for viral respiratory. The present study recorded an overall incidence of 65 cases (62.50 %) for Newcastle disease virus as a single infection. It was emerged as the predominant etiological agent responsible for respiratory disease outbreaks. These results corroborate with previous studies that identified the presence of NDV [13, 15-17]. The incidence of ND observed in the present study was marginally higher than that reported in some earlier investigations, which may be related to methodological variations among studies, including variations in number of pathogens targeted, longer study durations, difference in flock size and the number of samples analyzed by other researchers.

Flock wise analysis of viral respiratory infections in the present study showed that, out of 32 flocks screened, 13 (40.63%) flocks were found positive for NDV. The flock wise incidence observed in the present study has been previously reported[18].

In the present study, overall seasonal wise analysis showed a higher incidence of viral respiratory infections during the winter months compared to rainy season. NDV was identified consistently throughout the study period and remained as a predominant respiratory pathogen with an increased occurrence during winter season compared to rainy season. Comparable seasonal patterns have also been documented in previous studies, who also reported higher incidence of NDV in winter months[19,20, 21].

In the present study, chickens that succumbed to Newcastle disease exhibited gross respiratory lesions marked by various degree of congestion and edema of the lungs. In the present report lungs exhibited edema, congestion and areas of hemorrhage. The present investigation shows a close correlation with previously reported studies[22, 23]. Similar lesions were also reported in sonali chickens[24]. Trachea revealed mild to moderate congestion particularly around the cartilaginous rings, hemorrhages and mucosal congestion, as reported in earlier studies [3, 23, 25]. Air sacs were thickened[26] and cloudy or opaque and showed increased vascularity [3, 27].

Intestinal mucosa showed well demarcated, raised, circular button like ulcers which are hemorrhagic and these lesions were accompanied by mucoid to catarrhal enteritis[28]. Similar splenic lesions, characterized by enlargement and multiple discrete small necrotic foci on spleen[29]. In the present study, the caecal tonsils were enlarged and exhibited serosal hemorrhages with a congested, haemorrhagic mucosa. Our findings align with the comparable lesions documented[28]. The most frequent gross lesion observed in our study was pinpoint or petechial hemorrhages located at the tip of the proventricular glands[16].

In the current study, tracheal tissues from birds that died of NDV infection birds exhibited varied degrees of epithelial hyperplasia, loss of cilia and infiltration of lymphocytes in lamina propria and presence of submucosal lymphoid nodule. Comparable tracheal histopathological findings were also reported previously[13]. The trachea exhibited patchy necrosis of epithelium, congestion and edema in submucosa and infiltration. Similar lesions were also observed [23]. In few birds tracheal epithelial lining showed degenerative and necrotic changes accompanied by hemorrhage, congestion of blood vessels and mononuclear cell infiltrations. Comparable findings have also been documented earlier[24].

Pulmonary congestion, edema and mononuclear cell infiltration involving both alveolar septa and air spaces in NDV infection[24]. Comparable lung lesions were also evident in the present study. The bronchi exhibited ciliary loss with heterophilic plug formation and peribronchial mononuclear infiltration and parabronchial edema was consistent with earlier reports[13].

In the present study, embryos infected with NDV exhibited prominent lesions such as petechial hemorrhages over the head, neck and limbs along with generalized edema. These observatons are in agreement with the earlier findings reported[30].

RT-PCR was performed to detect the fusion (F) gene of new castle disease virus. A distinct band around 304 bp, which matches the expected size for the targeted region of F gene, was visible in the positive samples by using specific primers. Similar trends were documented in the present work[31] . These results are consistent with earlier reports[32, 33]. The PCR results confirm that NDV was circulating in the sampled population in Telangana.

ACKNOWLEDGMENTS

We would like to express our gratitude to P.V.

Narsimha Rao Telangana Veterinary University for providing necessary facilities and funds to carry out the research work.

Conflict of Interest : None

Financial Support & Sponsorship*:* None

Use of Artificial Intelligence (AI)-Assisted Technology for Manuscript Preparation: The authors confirm that there was no use of AI-assisted technology for assisting in the writing of the manuscript and no images were manipulated using AI.

REFERENCES

1. Moustapha A, Talaki E, Akourki A and Ousseini M. 2023. Newcastle disease virus in poultry: current status and control prospects. *World's Vet J* **13**(2):240-9.
2. Suarez D L, Miller P J, Koch G, Mundt E and Rautenschlein S. 2020. Newcastle disease, other avian paramyxoviruses, and avian metapneumovirus infections. *Dis Poultry* **13**: 109-66.
3. Gopal P A, Narayanaswamy H D, Sathyanarayana M L, Rao S, Rathnamma D and Hemadri D. 2023. Studies on respiratory tract pathology and molecular diagnosis of Newcastle disease in chickens in Karnataka. *Pharma Innovation* **12**:772-9.
4. Ravishankar C, Ravindran R, John A A, Divakar N, Chandy G, Joshi V, Chaudhary D, Bansal N, Singh R, Sahoo N and Mor S K. 2022. Detection of Newcastle disease virus and assessment of associated relative risk in backyard and commercial poultry in Kerala, India. *Vet Med Sci* **8**(3):1146-56.
5. Wang Y, Jiang Z, Jin Z, Tan H and Xu B. 2013. Risk factors for infectious diseases in backyard poultry farms in the Poyang Lake area, China. *Public Lib Sci One* **8**(6): e67366.
6. Jindal N, Chander Y, Chockalingam A K, De Abin M, Redig P T and Goyal S M. 2009. Phylogenetic analysis of Newcastle disease viruses isolated from waterfowl in the upper midwest region of the United States. *Virol J* **6**(1):191.
7. Dimitrov K M, Afonso C L, Yu Q and Miller P J. 2017. Newcastle disease vaccines— A solved problem or a continuous challenge. *Vet Microbiol* **206**:126 36.
8. Puro K and Sen A. 2022. Newcastle disease in backyard poultry rearing in the northeastern states of India: Challenges and control strategies. *Frontiers in Vet Sci* **9**: 799813
9. Getabalew M, Alemneh T, Akeberegn D, Getahun D, and Zewdie D. 2019. Epidemiology, diagnosis & prevention of Newcastle disease in poultry. *American J Biomedical Sci Res* **3**(1): 50-59.
10. Brown V R and Bevins S N. 2017. A review of virulent Newcastle disease viruses in the United States and the role of wild birds in viral persistence and spread. *Vet Res* **48**(1):68
11. Naz D, Rahman S, Aslam M A and Muhammad F. 2022. Newcastle disease virus in poultry with an interface as a human vector. *Vet Vac* **1**(1):100003.
12. Luna G L H T. 1968. *Manual of histological and special staining techniques*. 2nd ed., The Blakistone Divison McGraw-Hill Book Company, Inc. NewYork, Toronto London: 1-5 and 9-34.
13. Kaore M, Singh K P, Palanivelu M, Kumar, Ashok Kumar M, Reddy M R and Kurkure N V. 2018. Patho-epidemiology of respiratory disease complex pathogens (RDCPs) in commercial chicken. *Indian J Vet Pathol* **42**(4): 231-238.
14. Aldous E W and Alexander D J. 2001. Detection and differentiation of Newcastle disease virus (avian paramyxovirus type 1). *Avian pathology* **30**(2):117-28.
15. Broomand Z, Jafari R A and Mayahi M. 2018. Detection of Newcastle disease, H9N2 avian influenza, and infectious bronchitis viruses in respiratory diseases in backyard chickens in Ahvaz, Iran, in 2014-2015. *Archives of Razi Institute* **73**(1):19-25.
16. Momin A G and Singh D. 2018. Pathology and molecular diagnosis of Newcastle disease in chickens in and around Shillong, Meghalaya. *International J Curr Res* **10**:66251-4.
17. Deka P, Das S, Deka P, Nath M K, Hazarika R, Das G and Sarma M. 2022. Molecular Detection of Newcastle Disease Virus from Field Outbreaks in Assam, India. *Indian J Vet Sci Biotech* **18**(3), 97-99.
18. El-Shall N A, Sedeik M E, El-Nahas A F, Abdel-salam R A and Awad A M. 2019. Epidemiological Surveillance of Some Avian Respiratory Viral Diseases in Broiler Chickens. *Alexandria J Vet Sci* **61**(1).
19. Nwanta J A, Egege S C, Alli- Balogun J K and Ezema W S. 2008. Evaluation of prevalence and seasonality of Newcastle disease in chicken in Kaduna, Nigeria. *World Poultry Sci J* **64**(03): 416-423.
20. Olabode H O K, Damina M S, Ahmed A S, Moses G D and Wun gak Y S. 2012. Retrospective study of Newcastle disease in commercial poultry farms in Ilorin, Kwara State-Nigeria. *Vom J Vet Sci* **9**: 66 -70.
21. Bhutia L D and Singh Y D. 2016. Pathological studies on viral diseases of poultry in Mizoram, India. *Indian J Applied Res* **6**(9):606-10.
22. Bhutia L D, Rajkhowa T K, Ravindran R, Arya R S. Roychoudhury P, Mandakini, R K and Singh Y D. 2017. Occurrence of Newcastle disease in poultry population of Mizoram, India. *Indian J Vet Pathol* **41**(2): 151-154.
23. Dhaygude V S, Sawale G K, Chawak M M, Bulbule N R, Moregaonkar S D and Gavhane D S. 2017. Molecular characterization of velogenic viscerotropic Ranikhet (Newcastle) disease virus from different outbreaks in desi chickens. *Vet World* **10**(3):319.
24. Sajal S S, Rani S, Rahman M M, Mondal A and Alam K J. 2024. Sero-pathological Investigation of Newcastle Disease in Sonali Chicken in Narsingdi District in Bangladesh. *J Patuakhali Sci Tech Univ* **14**(1&2).
25. Regmi S, Bhatta R, Pal P, Shrestha A, Mató T, Puri B and Paudel S. 2024. Clinicopathological and Molecular Investigation of Newcastle Disease Outbreaks in Vaccinated and Non-Vaccinated Broiler Chicken Flocks in Nepal. *Animals* **14**(16):2423.
26. Shafi M, Jan S, Basher A, Shah S A, Shabir S, Mir M S, Kamil S A, Shah F and Mudasir S. 2023. Clinico-pathological assessment of naturally occurring Newcastle disease in broiler chicken reared in northern Himalayas. *Pharma Innovation J* **12**(8): 1436-1449
27. Gowthaman V, Singh S D, Dhama K, Barathidasan R, Anjaneya and Ramakrishnan M A. 2011. Pathology and molecular diagnosis of Newcastle disease virus infection in broiler breeders. *Indian J Vet Pathol* **35**(2):168 170.
28. Ali M, Khan M, Aslam A, Rehman H, Anjum A, Waheed S, Usman S, Masood S, Ullah A and Masood A. 2021. Molecular characterization and pathology of virulent newcastle disease virus isolated from broiler chickens in District Lahore, Pakistan. *Indian J Anim Res* 1420:1-8.
29. Maqbool B and Darzi M M. 2017. Comparative Pathology of Lymphoid Organs of Broiler Chicken in Commonly Encountered Disease Outbreaks. *Vet Res* **10**(2):6-14.
30. Bordoloi S, Nayak A, Singh A P, Singh R V, Jadav K, Dubey A, Jogi J, Shakya P and Himani K. 2021. Isolation and molecular characterization of Newcastle disease virus in layers. *Indian J Anim Res* **1**:9.

31. Collins M S, Bashiruddin J B and Alexander D J. 1993. Deduced amino acid sequences at the fusion protein cleavage site of Newcastle disease viruses showing variation in antigenicity and pathogenicity. *Archives virol* **128**(3-4):363 70.
32. Mihreteab B, Kgotlele T, Neguse F, Petros Y, Habtemariam H, Berhane Y, Wehab M, Cattoli G, Meki I K and Dundon W G. 2023. Phylogenetic analysis of Newcastle disease virus detected in Eritrea between 2017 and 2021. *Avian Pathol* **52**(6):426-31.
33. Molla G, Bitew M, Alemayehu D H, Mohammed A A, Ayele A, Tuki K and Guadie D. 2025. Molecular characterization and genotyping of Newcastle disease viruses using whole-genome sequencing from poultry farms in parts of Amhara Regions, and central Ethiopia. *Virol J* **22**(1):353.