Indian J. Vet. Pathol., 50(4) : 378-380, 2026: DOI: https://doi.org/10.56093/0zh5gx62

CASE REPORT

Pathological effects of immature amphistomosis in a goat – A case report

K. Thilagavathi* and J. Selvaraj
Department of Veterinary Pathology, Veterinary College and Research Institute, TANUVAS, Orathanadu, Thanjavur District, Tamil Nadu - 614 625

***Address for correspondence**
Dr. K. Thilagavathi, E-mail: thilagapatho@gmail.com
ORCID ID: 0000-0002-1624-251X

Received: 12.5.26; Accepted: 7.7.26

ABSTRACT

Immature amphistomosis is yet a very poorly understood disease of ruminants and falls under the category of neglected disease and often remains undiagnosed. An adult female goat carcass was submitted to the Department of Veterinary Pathology, Veterinary College and Research Institute, Orathanadu for necropsy. On necropsy examination, duodenal and proximal jejunal mucosa showed patchy areas of severe haemorrhage with thickened wall. Mucosa also showed multiple grey fleshy spots of 1-2 mm in diameter which were tightly attached to the mucosa. Intestinal scraping on microscopic examination, showed numerous motile immature amphistome flukes of various sizes with oral and ventral suckers. Histopathologically, intestine revealed the presence of cut section of immature amphistome flukes on the mucosa, submucosa and muscularis layer of intestine. The present case reported the pathological effects due to immature amphistomosis infection in a goat.

Key words: Immature amphistomes, Goat, Pathological effect

Livestock plays an important role in the economy of poor people in India. Domesticated small ruminants, especially sheep and goat are important sources of protein for many countries. Due to improper care, unhygienic environmental conditions, extreme climatic variations and close contact with infected animals, livestock get infected with a variety of parasites[1]. Paramphistomosis, a trematode infectious disease in ruminants, has been neglected but has recently emerged as an important cause of productivity loss[2]. Paramphistomosis (Amphistomosis) is a disease caused by digenean trematodes belonging to the family *Paramphistomatidae*. Adult paramphistomes are the main parasites in the rumen and reticulum of sheep, goats, cattle and buffaloes. Their early stages are in the small intestine and then migrate through the abomasum towards the rumen[1]. Immature paramphistomiosis is yet a very poorly understood disease of ruminants and falls under the category of neglected disease and often remains undiagnosed. It results in high death rates, reduced weight gain and milk production. Immature paramphistomiosis is a major problem in Indian subcontinent. The fluke causes havoc mortality in small domestic ruminants. Mortality rate may reach up to 75-88%. Prevalence and outbreak of immature amphistomiasis have been reported from Northern and also from Southern part of India[3]. The present communication reports about the pathological effects due to immature amphistomes infection in a goat.

An adult female goat carcass was submitted to the Department of Veterinary Pathology, Veterinary College and Research Institute, Orathanadu for necropsy. Duodenum and jejunum were collected in 10 % formalin for histopathological examination. Intestinal scrapping was taken for parasite identification. Intestinal tissues were processed in ascending grades of alcohol and cleared in xylene which was impregnated with melted paraffin to made tissue block. The 4µm tissue section was cut in a microtome which was deparaffinise in xylene, rehydrated in alcohol, stained with staining by haematoxylin and Eosin[4].

How to cite this article: Thilagavathi, K. and Selvaraj, J. 2026. Pathological effects of immature amphistomosis in a goat – A case report. Indian J. Vet. Pathol., 50(4) : 378-380.

On necropsy examination, both conjunctival mucous membranes were blanched indicating that the animal had anaemia which was supported by previous report[5] who stated that the clinical signs noticed in immature paramphistomosis, were because of helminthic parasites which adversely affect the absorption and utilization of proteins, minerals and vitamins as well as upset the general metabolism of the host by causing diarrhoea, anaemia and liver disorders.

Peritoneal, thoracic and pericardial cavities contained straw coloured fluid. It was in accordance with previous reports[4,6]. Duodenal and proximal jejunal mucosa showed patchy areas of severe haemorrhage,

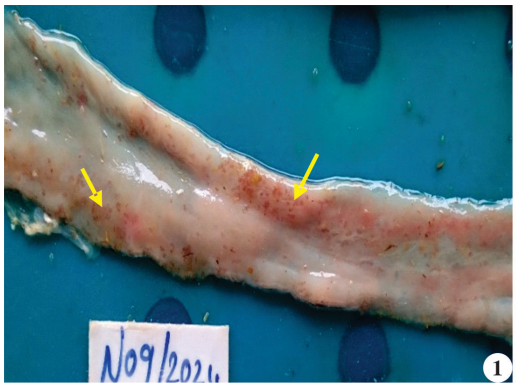

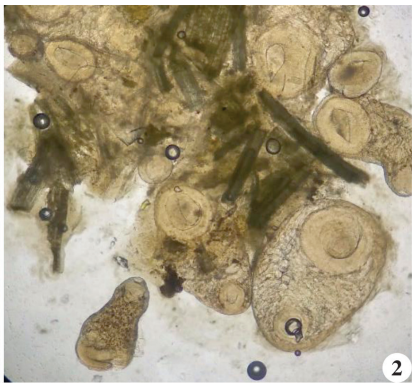

Fig. 1. Intestinal mucosa showing multiple grey fleshy spots of 1-2 mm in diameter (arrow) attached to the mucosa; **Fig. 2.** Intestinal scraping showing immature amphistome flukes with oral and ventral sucker.

petechiae in few areas and thickened wall. Mucosa also showed multiple grey fleshy spots of 1-2 mm in diameter which were tightly attached to the mucosa (Fig. 1). Intestinal scraping on microscopic examination, showed numerous motile immature amphistome flukes of various sizes with oral and ventral suckers (Fig. 2). These lesions were similar to earlier reports[7,8]. Histopathologically, intestine revealed the presence of cut section of immature

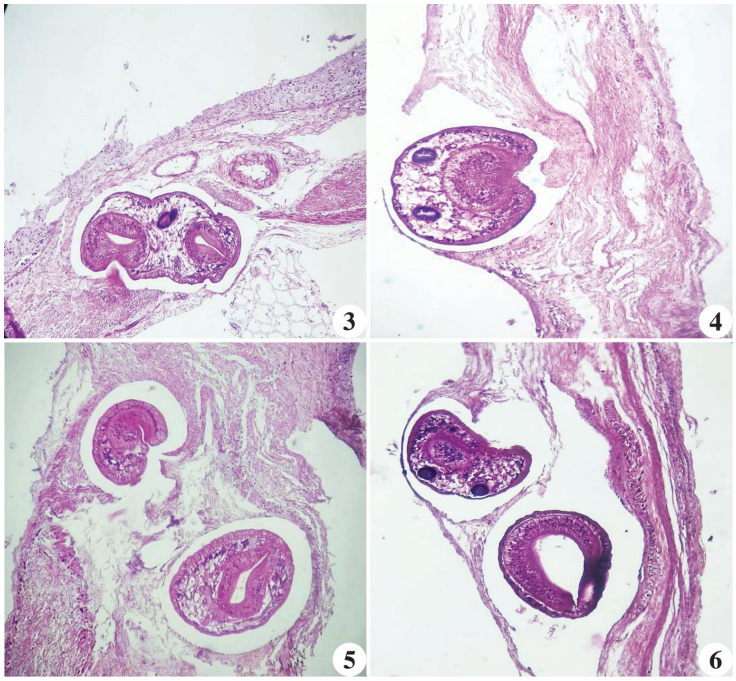

Fig. 3. Intestine showing cut section of amphistome fluke in muscularis layer with oral and ventral sucker (H&E x40); **Fig. 4.** Intestine showing cut section of amphistome fluke with plugging of sub-mucosal layer (H&E x40); **Fig. 5.** Intestine showing cut section of amphistome fluke with plugging of sub-mucosal layer (H&E x40); **Fig. 6.** Intestine showing cut section of amphistome fluke causing compression of inner circular muscle fibres (H&E x40).

amphistomes flukes on the mucosa, submucosa and muscularis layer of intestine. Flukes were attached to the surface of intestine or embedded in the mucosa to the level of muscularis mucosa layer (Fig. 3). Plugging of flukes through suckers into sub-mucosal layer (Figs. 4 and 5) were also observed. The pathological lesions due immature amphistome fluke infection were in strong agreement with previous report[6] who observed similar lesions, in addition with flattened villi and desquamated epithelium were reported. The high number of immature stages of the paramphistomes in the duodenum and upper ileum

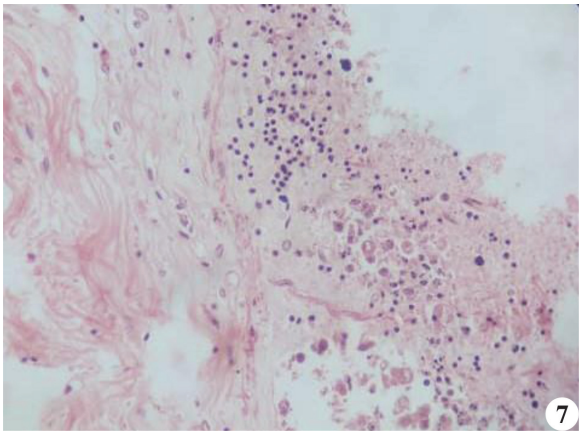

Fig. 7. Intestine showing focal infiltration of mononuclear cells and eosinophils in submucosal layer (H&E x400).

are responsible for severe pathological changes. These are embedded in the mucosa and are plug feeders, drawing pieces of the mucosa into the suckers which pinch them off causing necrosis and haemorrhage[9]. In the present case, fluke invaded into intestinal wall causing displacement as well as compression of inner circular muscle fibres (Fig. 6). There was focal infiltration of mononuclear cells and eosinophils were observed in submucosal layer (Fig. 7) which was supported by previous report[10]. The present case reported the pathological effects due to immature amphistomes infection in a goat.

Financial support & sponsorship*:* None

Conflict of interest : None

Use of artificial intelligence (AI)-assisted technology for manuscript preparation: The authors confirm that there was no use of AI-assisted technology for assisting in the writing of the manuscript and no images were manipulated using AI.

REFERENCES

1. Sivajothi S and Reddy BS. 2014. Immature paramphistomosis in a sheep herd. *Int J Biol Res* **2 (2):** 140-142.
2. Tehrani A, Javanbakht J, Khani F, Hassan MA, Khadivar F, Dadashi F Alimohammadi S and Amani A. 2015. Prevalence and pathological study of paramphistomum infection in the small intestine of slaughtered ovine. *J Parasit Dis* **39(1):** 100-106.
3. Sujatha T, Monda S, De AK, Perumal P, Sawhney S, Bala PA, Sunder J, Praveenraj J, Bhattacharya D and Chakurkar EB. 2023. First recorded outbreak of *Paramphistomum cervi* in Andaman local goats (*Capra aegagrus hircus*) from Bay Island of India: A brief communication. *Indian J Anim Sci* **93 (1):** 29–32.
4. Suvarna SK, Layton C and Bancroft JD. 2018. Bancroft's Theory and Practice of Histological Techniques, 8th Edn. Elsevier, Churchill Livingstone, USA.
5. Anand L, Dhanachand C, Mohilal N and Sharatkumar S. 2000. Prevalence of intestinal helminths in dairy cattle of Manipur, Uttar Pradesh. *J Zool* **20:** 93-95.
6. Balachandran C, Raman A and Pazhanivel N. 2010. An outbreak of amphistomosis in an organized sheep farm. *Tamil Nadu J Vet Anim Sci* **6:** 286-288.
7. Mondal MMH, Alim MA, Shahiduzzaman M, Farjana T, Islam MK, Das PM and Islam MZ. 2002. Pathology of Amphistomiasis in ruminants in Bangladesh. *Bangladesh Vet J* **36(3-4):** 103-108.
8. Kumar PC, Sundar SN and Prasad DV. 2016. Outbreak of immature paramphistomosis in Nellore Jodipi sheep. *J Parasit Dis* **40(2):** 533-35.
9. Soulsby EJL. 2006. Helminths, arthropods and protozoa of domesticated animals, 7th Edn. Bailliere Tindall, London, pp. 69-71.
10. Singh RP, Sahai BN and Jha GJ. 1984. Histopathology of the duodenum and rumen during experimental infections with *Paramphistomum cervi*. *Vet Parasitol* **15:** 39-46.