Indian J. Vet. Pathol., 50(4) : 381-383, 2026: DOI: https://doi.org/10.56093/78agjk39

CASE REPORT

Pathomorphology of ulcerated cutaneous eosinophilic granuloma in a horse

M. Karthick, M. Thangapandiyan, K. Gopal*, D.C. Monisha, P. Srinivasan and K. Balamurugan[1]
Department of Veterinary Pathology, Veterinary College and Research Institute, Namakkal, Tamil Nadu Veterinary and Animal Sciences University, Tamil Nadu
[1]Veterinary Assistant Surgeon

***Address for correspondence**
Dr. K. Gopal, E-mail: drvetpal@gmail.com
ORCID ID: 0000-0002-8747-9776

Received: 12.5.26; Accepted: 3.6.26

ABSTRACT

Eosinophilic granuloma is a non-neoplastic inflammatory dermatopathy of horses, characterized typically by nodular or occasionally ulcerative lesions associated with marked eosinophilic infiltration and collagen degeneration. A 5-year-old stallion was presented with a solitary, gradually enlarging mass on the right mandibular region. The lesion was firm, ulcerated, non-pedunculated and had irregular margins. Histopathological examination revealed a well-defined granulomatous lesion with dense infiltration of eosinophils admixed with macrophages and lymphocytes. The dermis showed marked collagen degeneration with formation of characteristic "flame figures," representing degenerated collagen fibres coated with eosinophilic granule proteins. Fibroplasia, neovascularization and perivascular inflammatory cell infiltration were also observed. No evidence of cellular atypia, mitotic activity or parasitic structures was observed. Based on the histopathological findings, the lesion was diagnosed as eosinophilic granuloma.

Keywords: Eosinophilic granuloma, Histopathology, Horse, Skin

How to cite this article: Karthick, M., Thangapandiyan, M., Gopal, K., Monisha, D.C., Srinivasan, P. and Balamurugan, K.2026. Pathomorphology of ulcerated cutaneous eosinophilic granuloma in a horse. Indian J. Vet. Pathol., 50(4) : 381-383.

Cutaneous nodular lesions are commonly encountered in equines and may arise from neoplastic, inflammatory or parasitic causes. Among the non-neoplastic conditions, eosinophilic granuloma is a frequently observed dermatopathy, typically presenting as firm dermal nodules that may occasionally undergo ulceration[1]. In certain cases, eosinophilic dermatoses may represent a component of a broader multisystemic eosinophilic disorder involving epithelial tissues[2]. Although the exact etiopathogenesis remains unclear, the condition is generally considered to be associated with hypersensitivity reactions to insect bites, trauma, allergens or foreign materials[3]. Similar lesions have also been reported in other equids, including mules[4].

Parasitic infections, particularly those caused by *Habronema* spp., have also been implicated in the development of eosinophilic granulomatous lesions[5]. Pathologically, the lesion is characterized by collagen degeneration (collagenolysis) accompanied by marked eosinophilic infiltration and granulomatous inflammation[6]. Histologically, a distinctive feature is the presence of "flame figures," which consist of degenerated collagen fibres coated with eosinophilic granule proteins and are considered a hallmark of this condition[7]. Clinically, such lesions may resemble neoplastic conditions, including equine sarcoids and squamous cell carcinoma, thereby necessitating confirmation through cytological and histopathological examination. The present report describes a case of eosinophilic granuloma affecting the mandibular region of a horse.

A 5-year-old stallion was presented with a solitary, progressively enlarging mass on the right side of the mandible. The lesion was ulcerated, firm and non-pedunculated with irregular margins. No systemic abnormalities were observed. A biopsy sample was collected and fixed in 10% neutral buffered formalin. Routine paraffin embedding was carried out and sections of 4 µm thickness were stained with haematoxylin and eosin (H&E) for microscopic examination.

Grossly, a solitary, firm, raised, non-pedunculated mass was observed on the right mandibular region, showing surface ulceration, irregular margins and moderate adherence to the underlying tissues (Fig 1). The cut surface appeared grey to yellowish. Histopathological examination revealed a large area of necrosis on the overlying epidermis with clumps of bacteria, severe infiltration of neutrophils and dermis showing severe inflammatory changes with dense inflammatory infiltration. The infiltrate predominantly

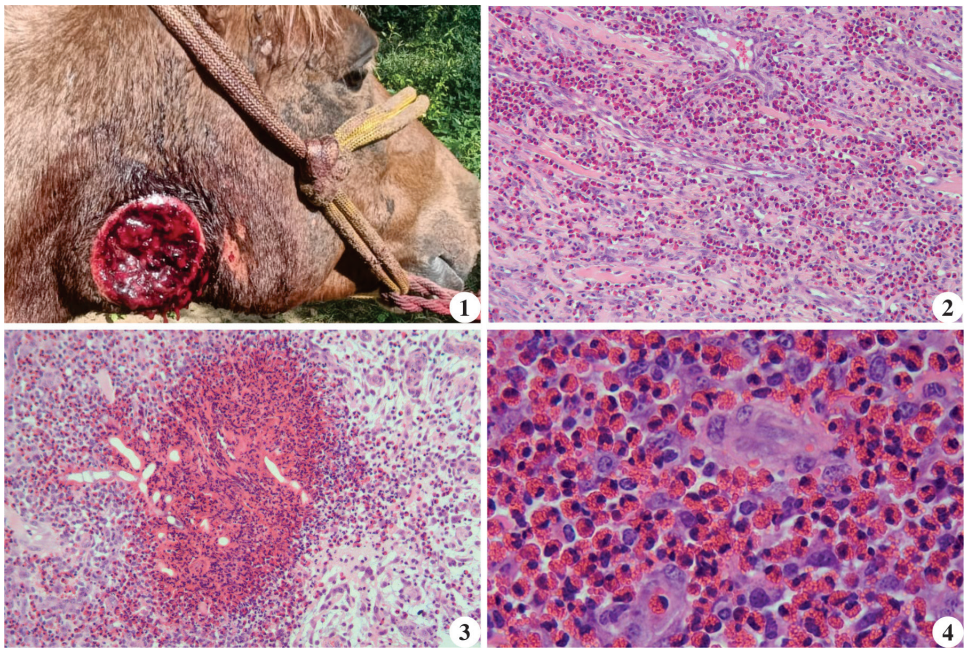

Fig. 1. Ulcerated solitary mass on the right mandibular region of the horse; **Fig. 2.** Dense eosinophilic infiltration in the dermis with collagen degeneration and early flame figure formation (H&E x100); **Fig. 3.** Collagenolysis with characteristic flame figures surrounded by numerous eosinophils (H&E x100); **Fig. 4.** Higher magnification showing eosinophil-rich granulomatous inflammation with multinucleated giant cells (H&E x400).

minor trauma[1,3] and may occasionally be associated with parasitic infections such as habronemiasis[5]. In the present case, although the exact aetiology could not be established due to lack of clinical history, the lesion is most likely attributable to a localized hypersensitivity reaction, possibly triggered by insect bite or minor trauma, in the absence of parasitic involvement or systemic disease. The lesion, located in the mandibular region, represents an uncommon site, as most reported cases involve the neck, back or withers[1,4]. The ulcerated appearance of the mass necessitated differentiation from neoplastic conditions such as equine sarcoid and squamous cell carcinoma. However, the absence of cellular atypia and invasive behaviour supported a non-neoplastic inflammatory origin.

Microscopic examination revealed features such as dense eosinophilic infiltration, collagenolysis, granuloma formation and perivascular cuffing, which are consistent with earlier reports[1,2]. The identification of flame figures, along with associated fibroplasia and vascular changes, further substantiates the diagnosis and aligns with previously described eosinophilic collagenolytic granulomas in horses[1,3,6,7]. Although eosinophilic dermatoses may be associated with systemic involvement, the lack of such findings in this case indicates a localized condition[2]. Differential diagnoses, including parasitic granulomas and neoplastic lesions[5], were excluded in the present case based on the absence of parasitic structures and neoplastic features. From a therapeutic standpoint, eosinophilic granulomas may respond to corticosteroid treatment; however, surgical excision is often recommended for large or solitary lesions[1,5]. The well-defined nature of the lesion in the present case supports surgical management, which is generally associated with a good prognosis.

composed of eosinophils admixed with macrophages and lymphocytes, resulting in disruption and separation of collagen bundles (Fig. 2). Marked collagen degeneration (collagenolysis) with formation of characteristic flame figures was observed, surrounded by numerous eosinophils and occasional multinucleated giant cells (Fig. 3). Additionally, areas of eosinophil-rich granulomatous inflammation characterized by the presence of multinucleated giant cells were evident (Fig. 4). No evidence of neoplastic proliferation or parasitic structures was observed.

Eosinophilic granuloma is considered to arise from a hypersensitivity reaction to insect bites, allergens or

ACKNOWLEDGEMENT

The authors are thankful to the Department of Veterinary Pathology, Veterinary College and Research Institute, Namakkal for providing the laboratory facility.

Financial support and sponsorship: None

Conflict of interest: None

Use of artificial intelligence for manuscript preparation: The author confirms that there was no use of AI-assisted technology for assisting in the writing of the manuscript and no images were manipulated using AI.

REFERENCES

1. Abbasi MF, Azizi S, Kheirandish R, Paidar A and Oloumi MM. 2015. Surgical treatment of too large eosinophilic granuloma in an Arabian horse. *Iran J Vet Surg*. **10**(2):73–76.
2. Wilkie JSN, Yager JA, Nation PN, Clark EG, Townsend HGG and Baird JD. 1985. Chronic eosinophilic dermatitis: a manifestation of a multisystemic eosinophilic epitheliotropic disease in five horses. *Vet Pathol*. **22**:297–305.

3. Slovis NM, Watson JL, Affolter VK and Stannard AA. 1999. Injection site eosinophilic granulomas and collagenolysis in horses. *J Vet Intern Med*. **13**(6):606–612.
4. Grigoletto R, Fantinato-Neto P, Strefezzi RF and Dória RGS. 2015. Eosinophilic granuloma in a mule. *J Cytol Histol*. **S3**:016.
5. Tyrnenopoulou P, Diakakis N, Psalla D, Traversa D, Papadopoulos E and Antonakakis M. 2018. Surgical management of eosinophilic granuloma associated with *Habronema* spp. infection. *Equine Vet Educ*. **30**(4):194–198.
6. Caston SS and Fales-Williams AJ. 2016. Eosinophilic granuloma in the forelimb of an Arabian mare. *J Equine Vet Sci*. **39**:78–81.
7. Devi VR, Hewicker-Trautwein M and Rohlmann B. 2006. Eosinophilic collagenolytic granuloma in a horse. *Indian J Vet Pathol.* **30(2):** 54