Indian J. Vet. Pathol., 50(4) : 384-385, 2026: DOI: https://doi.org/10.56093/v41vkr83

CASE REPORT

Fibrosarcoma in a labrador retriever dog

K. Kalai, B. Debroy* and S.W. Monsang[1]
Department of Veterinary Pathology, College of Veterinary Sciences and A.H., R.K. Nagar, Tripura (West) -799008, India
[1]Department of Veterinary Surgery

***Address for correspondence**
Dr. B. Debroy, E-mail: biplabvets@yahoo.co.in
ORCID ID: 0000-0002-8013-6498

Received: 2.5.26; Accepted: 3.7.26

ABSTRACT

Fibrosarcoma is an aggressive malignant tumour originating from fibrous connective tissue. The present case report describes a 7-year-old female Labrador Retriever dog presented with a prominent, firm, tennis ball–sized mass on the right side of the face. The lesion was extending into the oral cavity and causing marked discomfort and difficulty in feeding. Microscopic examination revealed densely packed spindle-shaped fibroblastic cells arranged in an interwoven and herringbone pattern, exhibiting marked cellular atypia, pleomorphism and increased mitotic activity. Areas of inflammation, angiogenesis and necrosis were also evident within the tumour mass. Based on these characteristic histopathological features, the lesion was diagnosed as fibrosarcoma. This report emphasizes the importance of early recognition, histopathological confirmation and timely intervention to improve clinical management and prognosis in affected animals.

Keywords: Dog, Fibrosarcoma, Labrador Retriever, Tumour

How to cite this article: Kalai, K., Debroy, B. and Monsang, S.W. 2026. Fibrosarcoma in a labrador retriever dog. Indian J. Vet. Pathol., 50(4) : 384-385.

Fibrosarcoma is a highly aggressive malignant neoplasm arising from fibroblasts of fibrous connective tissue and is characterized by infiltrative growth and a tendency for local recurrence[1]. In dogs, fibrosarcoma is reported in the skin and subcutaneous tissues; however, they may also occur in various anatomical locations including the oral cavity, extremities and facial region[2]. Canine oral fibrosarcoma is the third most frequently encountered malignant mesenchymal tumour affecting the oral cavity of dogs[3]. Tumours involving the facial area are of particular clinical concern because of discomfort, facial deformity, feeding difficulties and impairment of normal oral functions. The diagnosis of fibrosarcoma generally relies on a combination of clinical findings, cytological and histopathological examination. Early recognition and accurate diagnosis are essential for timely therapeutic or surgical intervention and improved clinical outcomes. The present case report describes the clinical presentation and diagnosis of facial fibrosarcoma in a Labrador retriever dog.

A 7-year-old female Labrador Retriever was presented with a history of a progressively enlarging swelling on the right side of the face. According to the history, the mass had gradually increased in size over time and was associated with noticeable discomfort during feeding. On physical examination, a firm, well-demarcated multilobulated mass approximately the size of a tennis ball was observed on the right facial region (Fig. 1). The swelling extended internally into the oral cavity, causing distortion of the adjacent tissues. The mass was non-ulcerated externally but appeared to exert pressure on surrounding structures, contributing to the feeding difficulties. No other significant systemic abnormalities were detected during the general clinical examination.

For confirmatory diagnosis, biopsy samples from the mass were aseptically collected and fixed immediately in 10% neutral buffered formalin. The samples were processed by routine paraffin embedding technique. Sections of 4-5 µm thickness were cut using rotary microtome and stained with routine haematoxylin and eosin (H&E) following standard protocol[6]. Microscopic examination revealed a highly cellular neoplasm composed predominantly of densely packed spindle-shaped cells arranged in interwoven fascicles (Fig.2). The neoplastic cells exhibited elongated nuclei, moderate cytoplasm and indistinct cell borders. Marked cellular atypia and pleomorphism were evident, along with increased mitotic figures in several fields (Fig.3). In addition, multifocal areas of inflammatory cell infiltration, prominent angiogenesis and focal necrosis were observed within the tumour mass (Figs. 4, 5).

Based on the clinical presentation and characteristic microscopic findings, the tumour was diagnosed as fibrosarcoma. Surgical excision of the tumour mass with wide margins was performed based on the biopsy report. The histopathological examination of the excised tumour mass also revealed similar features of fibrosarcoma. The oral gross lesions observed in the present case are similar with earlier report[3].The microscopic

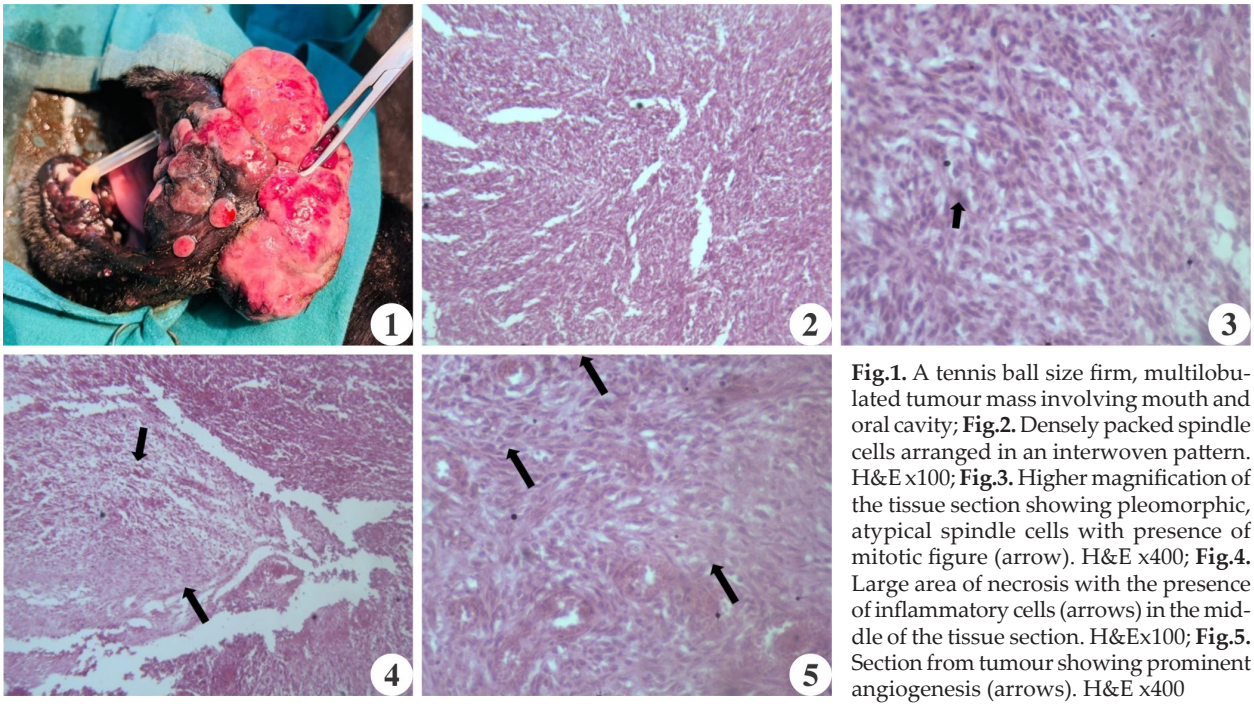

Fig.1. A tennis ball size firm, multilobulated tumour mass involving mouth and oral cavity; **Fig.2.** Densely packed spindle cells arranged in an interwoven pattern. H&E x100; **Fig.3.** Higher magnification of the tissue section showing pleomorphic, atypical spindle cells with presence of mitotic figure (arrow). H&E x400; **Fig.4.** Large area of necrosis with the presence of inflammatory cells (arrows) in the middle of the tissue section. H&Ex100; **Fig.5.** Section from tumour showing prominent angiogenesis (arrows). H&E x400

features observed in the present case were consistent with the classical morphology of fibrosarcoma reported in dogs and similar histopathological findings, including proliferation of spindle-shaped fibroblastic cells with cellular atypia and focal necrosis were also documented in canine fibrosarcoma cases [4,5]. Anaplasia and angiogenesis also reported earlier in a case of vaginal fibrosarcoma in dog[7]. Recognition of these characteristic features is crucial for differentiating fibrosarcoma from other soft tissue sarcomas and for guiding suitable therapeutic strategies. Early recognition of such aggressive neoplasms is essential for timely therapeutic intervention. Complete surgical excision of the tumour at an early stage plays a crucial role in prolonging life span and reducing the chances of recurrence.

ACKNOWLEDGEMENT

The authors thank the Principal, C.V.Sc. & A.H. R.K. Nagar, Tripura (W) for providing necessary facilities to carry out the research.

REFERENCES

1. Augsburger D, Nelson P, Kalinski T, Udelnow A, Knosel T. 2017. Current diagnostics and treatment of fibrosarcoma -perspectives for future therapeutic targets and strategies, *Oncotarget* **8** (61): 638–653.
2. Goldschmidt MH and Hendrick MJ. 2002 Tumors of the Skin and Soft Tissues. In: Meuten, D.J., Ed., Tumors in Domestic Animals, 4th Edition, Wiley, USA.
3. Verma A, Madhu Swamy Y, Shobha J, Dubey A, Rajput N. 2024. Oral fibrosarcoma in dog: Cytological, histopathological and immunohistochemical diagnosis. *Indian J Anim Res* **58**(3): 422-428.
4. Begum S, Deka A, Tamuli SM, Dutta B, Buragohain M. 2022. Fibrosarcoma in a dog: Case report. *Pharm Innov J* **11**(11): 1098-1100.
5. Soujanya S and Madhuri D. 2019. Cutaneous fibrosarcoma in dog. *J Entomol Zool Stud* **7**(1):861-863.
6. Luna LG. 1968. Manual of histological staining methods of the Armed Forces Institute of Pathology, 3rd edn., McGraw-Hill Book Company, New York, USA.
7. Mumba C, Pandeyl GS, Chijikwa J, Munjita S. 2013. Multiple Vaginal fibrosarcoma in a dog. *Indian Vet J* **90**(2):108-109.