Indian J. Vet. Pathol., 50(4) : 386-387, 2026: DOI: https://doi.org/10.56093/nqct3w45

CASE REPORT

An unusual case of fibroma in a Japanese quail

D.C. Monisha*, K. Gopal, P. Srinivasan, M. Karthick and P. Thirunavukkarasu[1]
Department of Veterinary Pathology, [1]Department of Poultry Science, Veterinary College and Research Institute, Namakkal
TANUVAS, Tamil Nadu, India

***Address for correpondence**
Dr. D.C. Monisha, Ph.D., Scholar, E-mail: dcmonishadpi@gmail.com
ORCID ID: 009-0003-1360-054X , 0000-0002-8747-9776

Received: 29.4.26; Accepted: 2.6.26

ABSTRACT

The incidence of fibroma is commonly reported in domestic animals. In chicken so far fibrosarcoma has been reported. The present case describes about the unusual case of cutaneous fibroma in a quail. A 6-months old Japanese quail was presented to Department of Veterinary Pathology, Namakkal for postmortem examination. The mass was located on 3rd toe of left leg of about 1.5 cm in diameter. On cut section it was greyish white in colour and rubbery in consistency. Histopathological examination revealed wavy bundles of spindle shaped fibroblasts. The cells are oval, elongated and indistinct nucleoli with abundant collagen. The collagenous fibres were in the form of whorls and they stain blue with Masson's trichrome staining. Immunohistochemistry showed strong expression for vimentin. Based on histopathology, histochemistry and immunohistochemistry this case was diagnosed as fibroma.

Keywords: Cutaneous fibroma, Masson's trichrome, Quail and Vimentin

How to cite this article: Monisha, D.C., Gopal, K., Srinivasan, P., Karthick, M. and Thirunavukkarasu, P. 2026. An unusual case of fibroma in a Japanese quail. Indian J. Vet. Pathol., 50(4) : 386-387.

Fibromas are non-malignant tumors of mesenchymal origin and consists of fibrous connective tissue arising from the fibroblasts. These growths tend to enlarge slowly and are well-defined[1]. These tumors are commonly located in eyelids, wings, between the toes and beak commissure[2]. The incidence has been reported in 24-week-old layer pullet while multifocal visceral fibrosarcoma has been reported in 2 years old hen[2] and petbirds[3]. The development of tumorous growth like fibroma is due to several factors such as hereditary influences, persistent stress, exposure to radiation, viral agents, endocrine imbalances and prolonged contact with various chemical and physical irritants[4]. The cutaneous fibromas are classified into two types as hard (dermato fibromas) and soft fibromas. Hard fibromas are predominantly composed of dense collagen fibres with a little cellular component, whereas soft fibromas (fibroma molle) are made up of loose arrangement of cells with minimal fibrous connective tissue[5]. These tumors are well defined, white to gray, elevated or rounded masses usually firm in consistency, measuring about 0.5×2 cm in diameter. The fibroma and fibrosarcoma are similar in appearance on gross examination, the only distinguishing feature of fibrosarcoma is that these tumors have irregular margins and often ulcerated[6].

A 6 months old Japanese quail was brought to Department of Veterinary Pathology, Veterinary College and Research Institute, Namakkal for postmortem examination. Detailed postmortem examination was carried out. On gross examination, the mass was located on the left leg – 3rd toe. The respective sample was collected in 10 % formalin. Paraffin embedded tissue sections were cut into 4µm thickness and stained with Haematoxylin and Eosin (H&E). Further, Masson trichrome staining was done as per the procedure[7] and immunohistochemistry for Vimentin was done as per the protocol of earlier author[8].

The mass was located on 3rd toe of left leg measuring about 1.5 cm in diameter (Fig. 1). On gross examination, the mass was white to grey in colour, firm and rubbery in consistency. The histological examination of the mass revealed numerous oval to spindle shaped fibroblasts with interlacing bundles of collagenous fibre and had elongated to oval nuclei and indistinct nucleoli (Fig. 2). Special staining was done to confirm the collagen in the neoplastic mass and it was positive for Masson's trichrome. The collagenous fibres were in the form of whorls and appeared blue in colour (Fig. 3). The immunohistochemical staining showed strong positive expression for vimentin with abundant interlacing bundles of collagen fibres (Fig. 4).

Fibromas are benign mesenchymal tumors of the skin and soft tissues which originates from the fibrocytes with predominance of collagen fibres. These tumors are most commonly observed in adult animals with no significant influence on sex or species[9]. Actually, collagen determines the type of tumor to

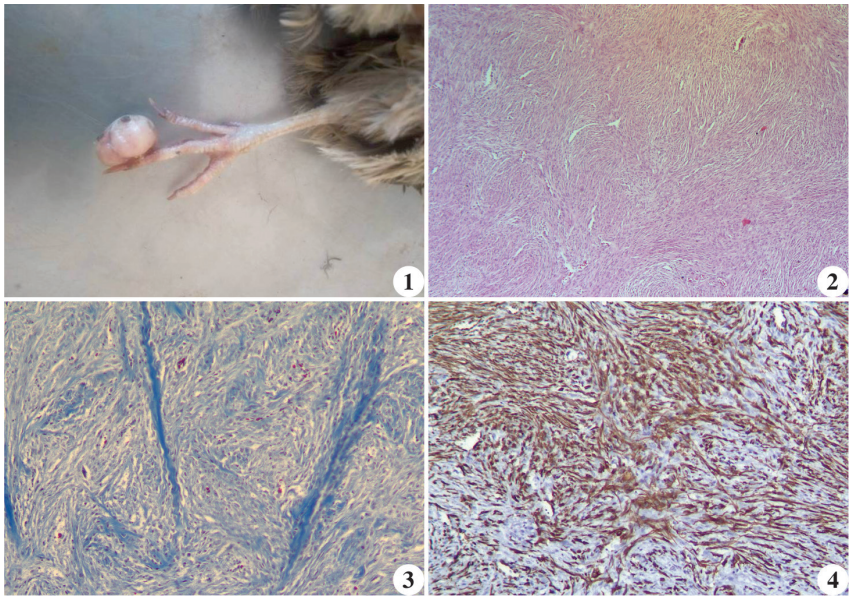

Fig. 1. The pedunculated oval mass in the third toe; **Fig. 2.** The histopathological examination revealed abundant collagen with oval to spindle shaped fibroblast and interlacing bundles of collagen fibres (H&E x40); **Fig. 3.** Masson trichome stain revealed numerous collagenous fibres which were arranged in the whorls and appeared blue in colour (Masson trichome stain x100); **Fig. 4.** The immunohistochemical staining for vimentin showed strong positive expression in interlacing bundles of fibroblast (IHC x100)

Masson's trichrome staining which showed positive for collagen fibres by a characteristics blue staining of stromal fibres. This finding further supports the fibroblastic origin of the tumor and is well correlated with the dense collagenous stroma observed in the histopathological sections. These observations are in agreement with previous reports, where fibromas were similarly confirmed using special stains such as Masson's trichrome[12].

The immunohistochemical staining in the present case showed strong positive expression of vimentin which further confirms the mesenchymal origin. This finding correlates well with the histopathological observation of spindle shaped fibroblastic cells arranged in interlacing bundles[9]. Absence of marked cellular atypia and low mitotic figures confirms the benign nature of the tumor. Hence, IHC plays a important role in substantiating the diagnosis of fibroma in this case.

Financial support and sponsorship: None

Conflict of Interest: None

Use of Artificial Intelligence for manuscript preparation: The author confirms that there was no use of AI-assisted technology for assisting in the writing of the manuscript and no images were manipulated using AI.

REFERENCES

1. Goldschmidt MH, Hendrick MJ. 2002. Tumors of the skin and soft tissues. In: Tumors of Domestic Animals, 4th ed., Iowa State Press, Iowa. Pp. 78-81.
2. Reece RL. 1996. Some observations on naturally occurring neoplasms of domestic fowls in the State of Victoria, Australia (1977–87). *Avian Pathol* **25**(3): 407-447.
3. Sanchez Godoy F, Ledesma Ramirez I and Morales Salinas E. 2020. A retrospective study of neoplasms in ornamental and pet birds diagnosed at the Hospital de Aves of the Universidad Nacional Autonoma de Mexico (2007-2014). *Braz J Vet Pathol* **13**(1): 1-11.
4. Jubb KVF and Kennedy PC. 1963. The Skin and Appendages. In: Jubb KVF, P.C. Kennedy PC and Palmer N, Pathology of Domestic Animals, 4th ed. 2:565.
5. Kumar KM, Rao CM, Veena P, Amrita V, Reddy KS, Kumari DV and Baba MS. 2014. Surgical management of fibroma in a bullock: A case report. *Int J Sci Environ Technol* **3**: 2284-2286.
6. Schmidt RE, Reavill DR, Phalen D. 2003. Pathology of pet and aviary birds. Ames (IA): Iowa State Press. pp. 153–92.
7. Bancroft JD and Gamble M. 2012. Theory and practice of histological techniques. 7th ed. Edinburgh. Churchill Livingstone, London. Pp.105-125.
8. Gopal K, Vijayakumar M, Kokila S, Thilagavathi K, Arulmozhi A and Balachandran P. 2024. Gingival haemangioma in a Jersey cross bred calf. *Indian J Vet Pathol* **48**(4): 372-374.
9. Meuten DJ. 2002. Tumors in domestic animals. 4th ed. Iowa: Iowa State Press, pp. 84-86.
10. Mana HP, Haruna AA, Mohzo DL and Abba A. 2021. Fibroma Molle (Acrochordon) in a Caucasian female Dog: case report. *Int J Vet Sci Anim Husb* **6**(6): 11-15.
11. Subapriya S, Vairamuthu S, Pazhanivel N, Ali M and Sumathi D. 2020. Pathology of cutaneous fibroma in a German Shepherd Dog. *Pharma Innov* **9**(4): 176-177.
12. Chonat A, Sharma A, Santha Devi A, Narayane R, Sanguida A and Raja R. 2026. The rare occurrence of a solitary collagenous fibroma in the gingiva of a 2-year-old child: A case report. *Case Rep Dent* **2026**(1): 5566658-5566673.