

## Management of exuberant granulation tissue in horses: review of 18 cases

Brihaspati Bharti<sup>1</sup>, Satyaveer Singh<sup>2</sup>, Shailendra Singh<sup>3</sup> and Balendra Singh<sup>4</sup>

Government Veterinary Hospital, Satna-485 001 (Madhya Pradesh)

<sup>1</sup>Veterinary Surgeon, Government Veterinary Hospital, Satna-485 001 (MP); <sup>2</sup>Assistant Professor, Department Veterinary Surgery, PGIVER, RAJVASU, Jaipur (Rajasthan), <sup>3</sup>Assistant Professor, Department Veterinary Pathology, COVSc, NDVSU, Rewa (MP).

DOI: 10.5958/0973-9726.2025.00013.9

Received: February, 2025

The retrospective study included 18 horses with the history of exuberant granulation tissue. Analysis of the condition was done based on age and sex of the animal, affected anatomical site, treatment and recovery status. Highest incidence of exuberant granulation tissue was noticed on limbs (n=12) followed by thorax, abdomen, pelvis (n=4) and head and neck (n=2). Mean age of the affected horses was 5.05 yr; 14 were males and 4 females. Surgical excision was done in most of the horses followed by firing, cauterization with potassium permanganate crystals and application of corticosteroid ointment. Postoperative medication included administration of antibiotic and anti-inflammatory drugs and oral serratiopeptidase, along with application of pressure bandage in most of the cases. All the horses recovered uneventfully in about 10-90 days. Histopathological examination confirmed the granulation tissue, characterized by the proliferation of fibrous tissue along with blood vessels.

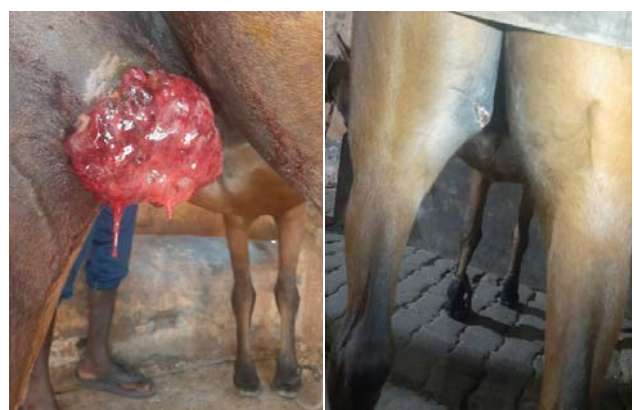**Key words:** Granulation tissue, Horse, Surgical Excision

Exuberant granulation tissue (EGT) is commonly known as proud flesh/fibroplasia. The anatomical characteristics of the distal limb (absence of the *Panniculus carnosus* muscle) and an inappropriate hygiene with development of a local infection are some of the most common and frustrating complications that disturb the healing and develop a fibroproliferative disorder known as exuberant granulation tissue (Naldaiz-Gastesi *et al.*, 2018). Although a number of therapies have been developed and assessed (Theoret and Wilmink, 2008), and several reports focusing on the pathogenesis of EGT in horses are available ((Theoret and Wilmink, 2008), the treatment of wounds in horses remains challenging. This paper discusses the successful management of EGT in 18 horses at different anatomical sites.

The study included 18 horses with EGT, which were 12 days to 5 months old. The highest incidence of EGT was seen in limbs (n=12, 66.66 %) followed by thorax, abdomen, pelvis (n=4, 22.22%), and head and neck (n=2, 11.11%). Mean age of the horses affected was 5.05 yr. Out of 18 horses, 14 were males and 4 females. In all the cases, surgical excision was done as per the anatomical site.

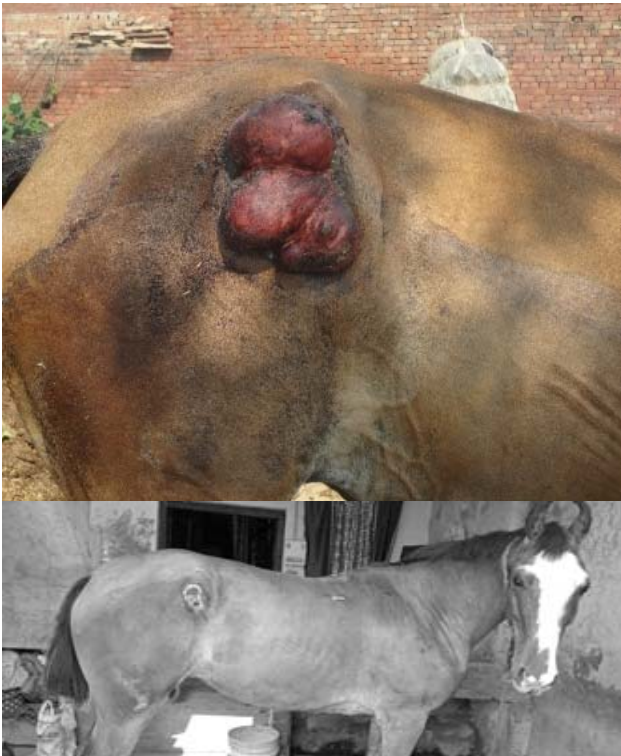All the horses were fasted for 12 hr and were administered with inj. Tetanus toxoid (1500 IU) intramuscularly prior to surgery. The horses were premedicated with xylazine (1.1 mg/kg body wt.) and butorphanol (0.01 mg/kg body wt.) administered intravenously. Anaesthesia was induced using ketamine (2.2 mg/kg body wt.). The granulation tissue was surgically excised and the bleeding was arrested by application of vascular ligatures using absorbable suture or by local application of potassium permanganate crystals. The granulation tissue was excised up to the level of the skin edges. Once the tissue resection was complete, a pressure bandage was applied to prevent any further bleeding. The representative tissue sample was preserved 10% formalin and processed for histopathology by H&E staining (Luna, 1968).

Postoperative care included application of pressure bandage with corticosteroid ointment, and administration of inj. procaine penicillin (22000 IU/kg body wt., i.m., OD) and inj. phenylbutazone (4.4 mg/kg body wt., i.v., OD) for 5 days. Bolus Serratiopeptidase OD was advised for 7 days. Small growths recurred were treated with cauterization, pressure bandaging with corticosteroid ointment,



**Fig. 1:** Exuberant granulation tissue in a horse before, and after treatment

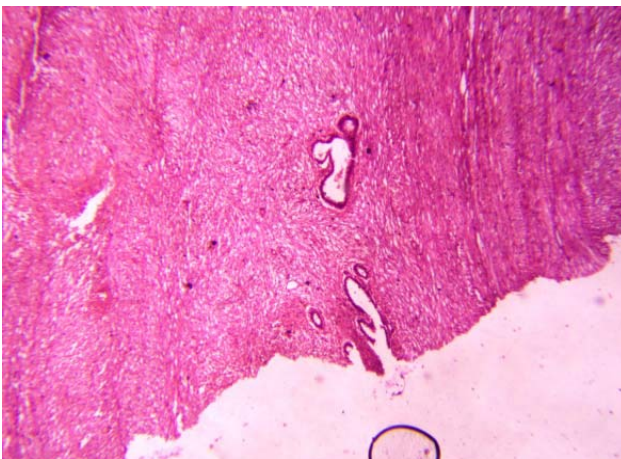
<sup>†</sup>Correspondence; E-mail: [brihaspati.vet@gmail.com](mailto:brihaspati.vet@gmail.com)



**Fig. 2:** Another horse with exuberant granulation tissue, before and after treatment.

along with similar protocol of antibiotics and analgesics.

All the horses recovered uneventfully within 10-90 days. Histopathological examination revealed the presence of granulation tissue in all the cases and no neoplasia was detected in any case. Granulation tissue was characterized by the proliferation of fibrous tissue along with blood vessels (Fig. 3). Wilmink and Weeren (2004) opined that formation of



**Fig. 3:** Histological section shows granulation tissue characterized by the proliferation of fibrous tissue along with blood vessels.

exuberant granulation tissue was affected by several factors such as bandaging, location and motion at the wound site, tissues involved, breed and iatrogenic factors. Wound healing in horses is often complicated by the formation of exuberant granulation tissue/proud flesh in which the granulation tissue proliferates to an excessive end thereby preventing wound re-epithelization (Cochrane *et al.*, 2003). Neovascularization with the proliferation of endothelial cells along with infiltration of different mononuclear cells and fibroblasts on H&E staining of the tissue samples is regarded as confirmation for EGT (Basha *et al.*, 2019). The surgical resection of the exuberant granulation tissue is considered the best treatment modality (Shivaraju *et al.*, 2021) because it is easy to perform, provides tissue for histological evaluation, and preserves the epithelial margin. The healing in surgically resected EGT cases is faster than in non-surgically treated masses (Eesa and Bader, 2011). The current study further indicates that large exuberant granulation tissue can be effectively managed by surgical resection, whereas small granulations can be treated by medical management.

## References

- Basha, K.M.A., Shah, M.A., Khan, S. and Amarpal 2019. Surgical management of proud flesh-a report of two equines. *Intas Polivet* **20**: 307-309.
- Cochrane, C.A., Pain, R. and Knottenbelt, D.C. 2003. In-vitro wound contraction in the horse: Differences between body and limb wounds. *Wounds* **15**: 175-181.
- Eesa, M. and Bader, O. 2011. Treatment of hyper-granulated limb wounds in horses. *Iraqi J. Vet. Sci.* **25**: 71-80.
- Luna, L.G. 1968. *Manual of Histologic Staining Methods of the Armed Forces Institute of Pathology*, 3<sup>rd</sup> edn. McGraw-Hill, New York. pp 111-112.
- Naldaiz-Gastesi, N., Bahri, O., Lopez-de-Munain, A. and Mccullagh, K. 2018. The *Panniculus carnosus* muscle: an evolutionary enigma at the intersection of distinct research fields. *J. Anat.* **233**: 275-288.
- Shivaraju, S., Maiti, S.K., Kalaiselvan, E., Prakash, G.V., Divya, M., Aswathy, G. and Kumar, S.S.P. 2021. Successful management of exuberant granulation tissue in two horses (*Equus caballus*) and a donkey (*Equus asinus*). *Large Anim. Review* **27**: 367-369.
- Theoret, C.L. and Wilmink, J.M. 2008. Treatment of exuberant granulation tissue. *In: Equine Wound Management*, Stashak, T.S. (Ed), 2<sup>nd</sup> edn. Wiley Blackwell, Ames, Iowa, USA. pp 445-462.
- Wilmink, J.M. and Weeren, P.R. 2004. Treatment of exuberant granulation tissue. *Clin. Tech. Equine Pract.* **3**: 141-147.