

Perineal hernia in an intact male dog and its surgical management through hernioplasty

Deny Jennes^{1†}, Nijin Jos B.M.², Reji Varghese², Lakshmi Padmanabhan³, Anuja, D.A.³ and Syam K. Venugopal⁴

Kerala Veterinary and Animal Sciences University, Pookode, Wayanad-673576 (Kerala)

¹PhD Scholar, ²Assistant Professor, ³MVSc Scholar, ⁴Professor and Head, Department of Veterinary Surgery and Radiology, College of Veterinary and Animal Sciences, Mannuthy, Thrissur

DOI: 10.5958/0973-9726.2025.00019.7

Received: August 2024

The present paper describes surgical management of perineal hernia in an intact male dog through hernioplasty.

A two and half year old intact Pomeranian male dog weighing 5.4 kg was presented with the history of a swelling in the right perineal region for a period of about two months. The animal had difficulty in urination and defaecation. On palpation, a soft fluctuating fluid filled mass was noticed. On radiographic examination, bladder opacity was not found in the normal location, suggestive of herniation of urinary bladder (Fig. 1). A sterile urinary catheter was passed without any obstruction and urine was relieved, which subsequently reduced the size of the swelling confirming the diagnosis of perineal hernia. Haematological analysis revealed anaemia with granulocytosis. Increased blood urea nitrogen and creatinine level were observed in serum biochemistry. It was decided to perform corrective hernioplasty.

The surgical site was prepared aseptically. The animal was positioned in sternal recumbency with elevated pelvic region. Tail was secured over the back to prevent the interference with the surgical site. A sterile gauze sponge was introduced into the rectum to prevent the surgical site contamination. A urinary catheter was placed in position for the correct identification of the urethra during the surgery. The animal was premedicated with atropine SO₄ (0.045

mg/kg body wt., s.c.), xylazine HCl (1 mg/kg body wt., i.m.) and tramadol HCl (2 mg/kg body wt., i.m.). Induction of anaesthesia was done with ketamine HCl (5 mg/kg body wt.) and midazolam (0.2 mg/kg body wt.) administered intramuscularly. Maintenance of anaesthesia was done with isoflurane (1-2%) in oxygen through an endotracheal tube.

A curvilinear incision was made on the perineal region over the swelling and the herniated urinary bladder was exposed along with enlarged prostate gland and some retroperitoneal fat. The animal owner was not willing for the castration, necessitating medical management for the enlarged prostate. Following reduction of the herniated contents, the hernial ring of about 5- 6 cm in diameter was closed with polyglactin 910 (2-0) in continuous lock stitch pattern and reinforced with a piece of polypropylene mesh (6 cm × 6 cm) as onlay graft (Fig. 2). The skin was then apposed using fine nylon in horizontal Mattress pattern.

Postoperatively the dog was treated with tab. cephalaxine (15 mg/kg body wt.) for five days, tab. meloxicam (0.2 mg/kg body wt.) for three days and tab. finasteride (0.5 mg/kg body wt.) for 3 months administered orally along with stool softeners. The skin sutures were removed on 10th postoperative day. The haemato-biochemical parameters returned to normal range by 10th day.

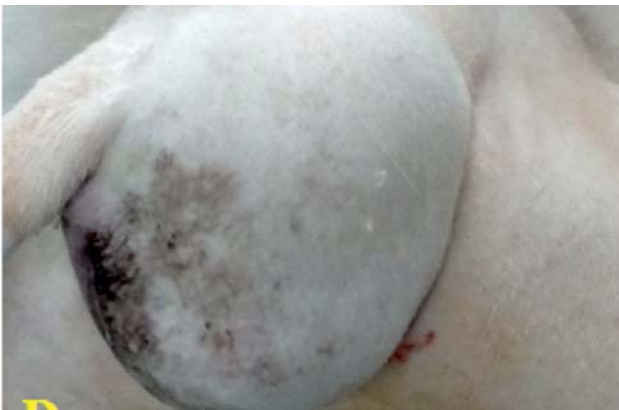

Fig. 1: A - Animal exhibited severe swelling in the right perineum

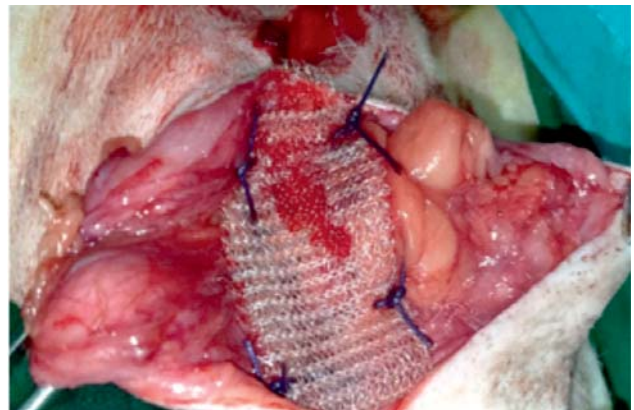


Fig. 2: Hernioplasty with polypropylene mesh

[†]Correspondence; E-mail: denyjennis@gmail.com