

Ultrasonography of udder oedema in goat: a case report

Surya Pratap Singh^{1†}, Sanjay Purohit², R.P. Pandey², and Gulshan Kumar²

Pandit Deen Dayal Upadhyaya Pashu Chikitsa Vigyan Vishwavidyalaya Evam Go-Anusandhan Sansthan, Mathura-281 001(Uttar Pradesh)

¹PG Scholar, ²Professor, Department of Veterinary Surgery and Radiology, College of Veterinary Science and Animal Husbandry

DOI: 10.5958/0973-9726.2025.00021.4

Received: January 2025

Ultrasonography is useful in early diagnosis of pathological changes that occur in the mammary glands such as injuries, trauma, udder affection and preclinical mastitis (Senthilkumar *et al.*, 2020). The present paper described ultrasonographic evaluation of udder oedema in a goat.

A 3-year-old Sirohi goat with history of udder swelling was presented just after kidding. The goat was in 4th parity, clinical examination revealed udder oedema on both half of the udder but more on right udder and teat (Fig. 1). The rectal temperature was 102°F, and the surface temperature of udder was slightly lower than the normal when palpated manually. Feed and water intake was slightly decreased while the defecation and urination were normal.

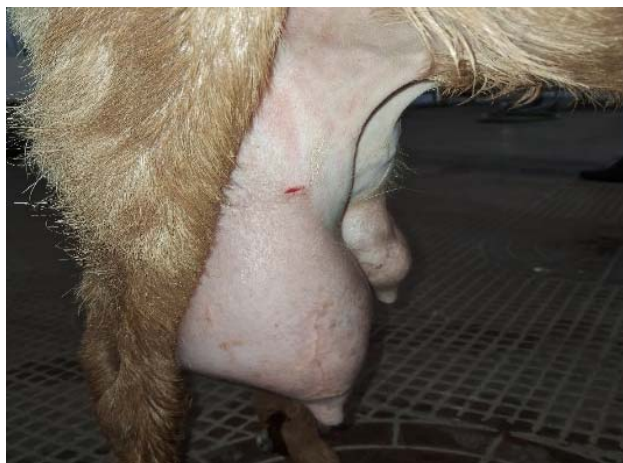

Fig. 1: Udder showing subcutaneous swelling indicating udder oedema

On ultrasonographic examination udder parenchyma appeared more anechoic as compared to normal homogenous parenchyma indicating the fluid accumulation below the subcutaneous tissue; venous congestion could be seen clearly (Figs. 2 and 3).

In the present case, measuring the rosette of Furstenberg proved difficult, and accurate measurements were not possible due to the loss of differentiation in the echotexture of the rosette, streak canal and teat cistern. These observations align with

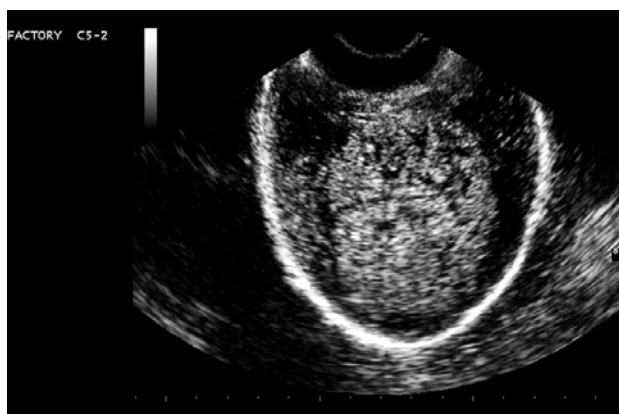


Fig. 2: Ultrasonogram of udder showing increased anechoic area in homogenous parenchyma indicating udder oedema.

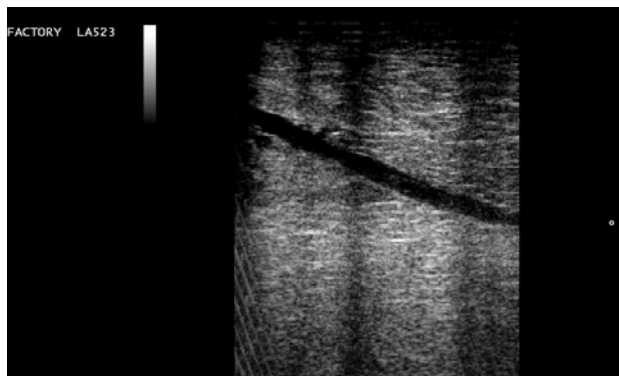


Fig. 3: Ultrasonogram of udder showing anechoic venous congestion within the parenchyma.

the findings of Flock and Winter (2006) and Amin *et al.* (2018) who have also reported a loss of differentiation in the echotexture of these structures in their study. Based on the observations of this study, it can be concluded that the typical normal echotexture of the udder parenchyma and the teat cistern are lost in case of oedema of udder and teat.

Reference

Senthilkumar, S., Kannan, T.A., Gnanadevi, R., Ramesh, G. and Sumathi, D. 2020. Ultrasonographic anatomy of udder in indigenous Madras Red sheep. *Haryana Vet.* 59: 182-184.

[†]Correspondence; E-mail: suryapratapsingh31299@gmail.com