

Clinical and radiographic findings of mid-shaft femoral fractures treated with Tie-in ESF assembly in young dogs

Jyoti¹, A.K.Bishnoi^{2†}, Ruchi Patwa³, Meena Kumari Puniya¹, Komal Galgat³, Mohan Lal Sharma³, Shivraj Bishnoi¹, S.K. Jhirwal² and P. Bishnoi⁴

Rajasthan University of Veterinary and Animal Sciences, Bikaner- 334 001 (Rajasthan)

¹MVSc scholar, ²Assistant Professor, ³PhD scholar, ⁴Professor and Head, Department of Veterinary Surgery and Radiology, CVAS, Bikaner

DOI: 10.5958/0973-9726.2024.00023.4

Received: April, 2024

In this study, Tie-in ESF with negative profile transcortical pins and simple intramedullary pin was used for stabilization of closed mid-shaft femur fractures in eight young dogs aged 5.13±0.98 months with the mean body weight of 6.64±0.86 kg. The fracture was either long oblique (n=4) or short oblique (n=4). The treated dogs showed initial partial weight bearing from 1st to 5th postoperative day. Final outcome in terms of limb function was found to be excellent in 7 cases (87.50%). In 6 cases having long follow up, radiographic bone union was achieved. The mean period of ESF assembly removal was 43±4.02 days, (range 34-64 days). The complications observed included slight pin tract exudation (n=8), ESF clamp pressure sore (n=1), and reduced stifle joint function (n=6), which were minor and they did not affect the final outcome of the patients.

Key words: Dogs, Femur, Fracture fixation, Tie-in ESF

Several methods and implants can be utilized for stabilizing the long bone fractures. These include external immobilization techniques, internal fixation techniques (such as intramedullary pins, interlocking nails, cerclage wires, bone plate and screws etc.) and external skeletal fixation (ESF), as well as the combination of more than one technique (Piermattei *et al.*, 2006; Popkov *et al.*, 2014; and Aydin *et al.*, 2022).

Femur fractures in dogs can be managed by a variety of surgical techniques. The most commonly used method for femur fracture fixation in dog is intramedullary pinning (Piermattei *et al.*, 2006; Fossum, 2007), but it offers poor resistance to overcome the rotational and axial compression force of the bone (Radke *et al.*, 2006; Johnson, 2007; Shete and Gaikwad, 2020). Bone plating and interlocking nailing techniques require lot of instrumentation, and are time consuming, expensive and more invasive than other alternatives (Vallefuoco *et al.*, 2016). Among the external skeletal fixators, more rigid configurations such as unilateral biplanar and bilateral frames cannot be used above the elbow or stifle due to the presence of large muscle masses and fixator interference with the body wall (Egger and Greenwood, 1985). A type-I uniplanar ESF frame is too weak to resist the forces produced by the combination of limb loading and large muscle masses

in these regions. The basic type-I frame can be strengthened for such applications by tying-in an intramedullary pin (Corr, 2005). Thus, femur fractures which cannot be rigidly stabilized by only IMP or only type-I ESF technique, to achieve the strong fracture fixation, Tie-in (IMP with ESF) procedure is a better choice. Threaded transcortical pins offer stronger holding power than non-threaded pins and are used to reduce the frequency of early loosening and the related morbidity (Palmer *et al.*, 1991).

The objective of the present study was to evaluate the efficacy of tie-in ESF technique for immobilization of femoral fractures in young growing dogs.

Materials and Methods

The study included eight cases of dogs having simple closed femur fractures (Table 1). Out of which 6 were non-descript and remaining 2 were of mixed breed. The mean age of the dogs was 5.13±0.98 months (range 3-12 months) with the mean body weight of 6.64±0.86 kg (range 4.5-10.3 kg). All the 8 fractures were of femoral mid-shaft and the fracture configuration was long oblique and short oblique in 4 cases each. The fractures in all cases were treated by immobilization with Tie-in ESF assembly. Intramedullary pin (IMP) placement was initially attempted with closed reduction method under the C-arm fluoroscopic guidance, but it was unsuccessful, and finally it was placed by open reduction method in retrograde manner in all the cases. The IM pins were 9/12 inch long, non-threaded smooth stainless steel (316L) Steinmann pins or K-wires of approximate diameter (40-50% of medullary cavity diameter at the level of isthmus). In cases with long oblique fracture, cerclage wiring was also performed to achieve compression between fracture fragments at the fracture site. The externally applied ESF was in linear unilateral-uniplanar configuration, and the transcortical pins used were negative profile end-threaded pins. The pins were placed using low speed battery driven electric drill. The numbering of transcortical pins was done from proximal to distal

[†]Corresponding author; E-mail: bishnoisurge@gmail.com

end of each segment. The diameter transcortical pins was kept approximate 20-30% of cortex-to-cortex diameter of bone fragments (the cortex-to-cortex bone diameter and medullary cavity diameter at isthmus were determined in all cases from their preoperative radiographs). The external ends of transcortical pins were interconnected with a smooth stainless steel connecting bar using stainless steel Jess clamps. Tie-in ESF was achieved by bending the proximal external end of IMP towards the long proximal end of ESF connecting bar and then interconnecting the both with either a single medium sized Jess clamp or AO stainless steel clamp. The distance of bending of proximal external end of IMP from the gluteal surface and of the applied ESF clamps from the lateral thigh

surface was kept about 10 mm to allow space for the postoperative swelling, regular dressing of pin-skin interface, and for the free movement of hip joint. After proper placement and tightening of all the clamps with Allen key (Jess clamps) or spanner (AO clamps), the extra external protruding ends of transcortical pins and IMP were cut down, the skin-pin interface were wrapped with thin strips of sterile gauzes impregnated with povidone iodine, and finally the whole Tie-in ESF assembly was laterally and dorsally wrapped with bandage after placing thin cotton padding over it. The external bandaging of ESF assembly excluded stifle and hip joints to allow their free movement in the postoperative period. Unless the protective bandage got soiled or wet with the

Table 1: Findings of the treated femoral fracture cases: signalment, fracture type, and ancillary fixation.

| Case No. | Age (month) | Sex | Body weight (kg) | Breed | Etiology | Limb | Fracture configuration | Concomitant injury/treatment | Ancillary fixation (cerclage wire) |
|----------|-----------------------------|-----------------|-----------------------------|--------------------------------|--|--------------------|---------------------------------------|--|------------------------------------|
| C1 | 5 | F | 5.0 | Non-descript | Automobile Accident | RH | Long oblique | Ipsilateral tibia-fibula fracture/medial side splint application | 1 cerclage wire |
| C2 | 6 | F | 8.2 | Non-descript | Automobile Accident | RH | Short oblique | None | Nil |
| C3 | 12 | M | 10.3 | Mixed | Automobile Accident | RH | Long oblique | None | 2 cerclage wire |
| C4 | 3 | F | 4.5 | Non-descript | Automobile Accident | RH | Short oblique | None | Nil |
| C5 | 4 | M | 5.0 | Non-descript | Automobile Accident | LH | Short oblique | Ipsilateral hip joint luxation | Nil |
| C6 | 4 | F | 9.0 | Mixed | Automobile Accident | LH | Long oblique | Contralateral limb in extended position | 1 cerclage wire |
| C7 | 3 | M | 4.5 | Non-descript | Automobile Accident | RH | Short oblique | None | Nil |
| C8 | 4 | F | 6.2 | Non-descript | Fall from height | RH | Long oblique | None | 2 cerclage wire |
| | Mean± SE= 5.13 ±0.98 | M= 3 F=5 | Mean± SE =6.64 ±0.86 | Non-descript= 6 Mixed=2 | Accident=7; Fall from height= 1 | LH= 2 RH= 6 | Long oblique=4 Short oblique=4 | Concomitant injury (n= 03) | Cerclage wiring (n= 04) |

Table 2: Lameness grading; slight modification from Larin *et al.* (2001)

| Lameness Grade | Description |
|----------------|---|
| 0 (Excellent) | No apparent visible lameness or gait abnormality while walking or trotting |
| 1 (Very good) | Intermittent mild weight bearing lameness or minimal gait abnormality while walking or trotting |
| 2 (Good) | Intermittent non-weight bearing lameness while walking or trotting |
| 3 (Fair) | Toe touching while standing or walking |
| 4 (Poor) | Remained always non weight bearing |

Table 3: Postoperative radiographic evaluation of fracture healing as per slight modification in the scale provided by Hammer *et al.* (1985).

| Radiographic healing score | Callus formation | Fracture line | Stage of union |
|----------------------------|--|--------------------|----------------|
| 5 | Homogeneous bone structure | Obliterated | Achieved |
| 4 | Massive Callus, Bone trabeculae crossing fracture line | Barely discernible | Achieved |
| 3 | Apparent callus, Bridging of fracture line | Discernible | Uncertain |
| 2 | Trace callus, No bridging of fracture line | Distinct | Not achieved |
| 1 | No callus formation | Distinct | Not achieved |

urine or faeces of the animal, it was changed once every 5 days. Postoperatively, the animal owners were advised to restrict the free movement of the animals, to protect ESF assembly along with bandage from entangling in any external object, and to preferably keep the Elizabethan collar to avoid any self-mutilation of the surgical site. Oral administration of antibiotic (Cefpodoxime Proxetil) twice a day for 7 days, NSAID (Meloxicam) once a day for 3 days, calcium-phosphorus and multi-vitamin supplements twice a day for one month were advised. Postoperatively, all the animals were clinically and radiographically evaluated at regular time intervals, through clinical revisits or telephonic contact, for the weight bearing status, surgical wound condition, exudation from pin-skin interface, stability of components of ESF assembly, fracture healing progress, final outcome, and development of any other complication. On every clinical visit, the applied ESF clamps were checked for any loosening, and were retightened, if required. Lameness grading of the treated animal was done at weekly interval as described by Larin *et al.* (2001) with a slight modification (Table 2), while radiographic evaluation of fracture healing progress was done by the grading procedure described by Hammer *et al.* (1985) (Table 3). The complete ESF assembly was removed in all the cases after the radiographic confirmation of bone union.

Results and Discussion

The mean value of diameter of medullary cavity at isthmus of bones was found 6.51 ± 0.43 mm, mean diameter of IMP used was 2.44 ± 0.11 mm (range 2.0-3.0 mm), hence the percentage (%) of medullary cavity diameter at isthmus occupied with single IMP was $41.23 \pm 0.91\%$. The average size of transcortical pin used in proximal and distal fragment was 2.43 ± 0.19 mm (range 2.0-3.5 mm), and the mean percentage (%) of cortex-to-cortex bone diameter occupied with transcortical pin in proximal segment and distal segment was $22.48 \pm 1.18\%$ and $20.16 \pm 0.81\%$, respectively. The mean diameter of connecting bar used was 3.44 ± 0.24 mm (range 3-5 mm). Research studies have advocated the use of ESF transcortical pins with 20-30% of the bone diameter (Piermattei *et al.*, 2006). Transcortical pin size is one of the factors

influencing the strength and stiffness of the fixator and its ability to resist the axial loading, bending and rotation associated with the weight bearing of the animal (Fossum, 2019). Narrower diameter ESF pin creates a less stiff ESF construct and thus the potential for greater fracture instability, higher gap strain and impaired fracture healing (Palmer *et al.*, 1992). Except in one case (C8), 2 transcortical pins were applied in each fracture segment in all cases. Usually, a minimum of two pins should be placed per bone segment but many authors recommend 3-4 transcortical pins per segment (Egger, 1991; Palmer *et al.*, 1992; Knudsen *et al.*, 2012; Beever *et al.*, 2018).

Immediate postoperative radiographs revealed complete fracture reduction and apposition of fracture fragments in all the cases. Inadequate fracture reduction can result in a gap that is too large for the healing process to bridge, hence minimal acceptable reduction is at least 50% cortical contact (Egger, 1991). In none of the case, any transcortical pin piercing the far-cortex beyond its limit, which could injure the medial side surrounding soft tissue of thigh, was seen. In all cases, the transcortical pins inserted immediate next to fracture site were found to having at appropriate distance from the fracture line, but in one case (C4) having 3P:2D (P: proximal; D: distal) transcortical pin configuration, the 3rd transcortical pin of proximal fragment adjacent to fracture site was found at less than appropriate distance from the fracture line. Studies indicated that maximum ESF stability was accomplished by inserting the pins near the proximal and distal ends of the bone fragment rather than by inserting both pins near the ends or near the fracture site. The pins should be kept half the bone diameter distant from the fracture line (Piermattei *et al.*, 2006). In the above mentioned case of this study, on 3rd postoperative day, after loosening the clamp, the pin near to the fracture site was withdrawn completely, leaving the configuration 2P:2D. Immediate postoperative radiograph of one case (C5) having concurrent traumatic ipsilateral hip joint luxation injury, showed relaxation of intraoperatively reduced hip joint.

The dogs showed initial partial weight bearing at 1st to 5th postoperative day (mean 1.75 ± 0.46 days). The mean value of lameness grades at weekly intervals were 2.00 ± 0.25 , 1.62 ± 0.30 , 1.25 ± 0.34 ,

1.57±0.40, 1.50±0.31 and 1.50±0.31 at 1st, 2nd, 3rd, 4th, 5th, and 6th postoperative week, respectively. It was observed that in the postoperative period the lameness initially decreased up to 3 weeks, which increased transiently in the 4th week but thereafter it again decreased progressively up to the end of the study period. The functional outcome was excellent in 7 cases, which was achieved in the average period of 7.0±0.80 weeks, and in the remaining one case (C6) it was found good till the follow up of 5th postoperative week (Fig. 1). Similar findings were observed by Aydin *et al.* (2022), who found that use of the relevant extremities was not difficult in the first 3 days after the surgical fixation in all the cases treated with tie-in osteosynthesis technique with intramedullary threaded pin in humeral, tibial, and femoral diaphyseal fractures in dogs. However, they noted that from the days 3-15, the animals were cautious to use their respective extremities when pressing the ground, either reluctantly or not at all, and after day 15, the animals used their extremities without any difficulty. Rao *et al.* (2017) in their study found that the dogs, which were treated for femoral and humeral diaphyseal fractures with the Tie-in configuration of ESF, showed partial weight bearing from 3rd to 6th postoperative day. ESF has the advantage of keeping soft tissue trauma at the fracture site at the lowest and allowing weight bearing on the healing bone at the earliest (Egger, 1998; Johnson and Decamp, 1999; Lewis *et al.*, 2001). Early limb usage promotes fracture

healing by allowing axial micromotion at the fracture site and also prevents inactivation atrophy in patients with bone fractures (Carnmicheal, 1991; Lincolan, 1992; Radke *et al.*, 2006; Yardimci *et al.*, 2018). The major purpose of all fracture treatment methods is to obtain the soonest possible recovery and early functional limb use (Egger, 1991).

Radiographically, in postoperative follow-up, the fracture healing progressively improved throughout the study period, with the mean score of 2.75±0.15, 3.83±0.15, 4.6±0.21, and 4.83±0.15 at 2nd, 2nd-4th, 4th-6th, and 6th-8th postoperative week, respectively (Figs. 2-4). Rao *et al.* (2017) observed progressive bone healing from postoperative radiographs of femoral and humeral diaphyseal fractures in dogs treated with tie-in configuration of ESF. Callus formation was seen on 15th postoperative day with distinct fracture line, and primary callus formation was seen from 30th-45th postoperative day. At this time the linear fixator (Type Ia ESF) was removed, and they noted that at a mean period of 43.16±4.46 days sufficient callus was formed. Devarapalli (2014) also used tie-in configuration of ESF for the treatment of femoral fractures in 6 dogs. Bridging callus was evident radiographically on 15th postoperative day in the form of cortical and medullary continuity. Moderate amount of hard callus was seen on 30th postoperative day. Peirone *et al.* (2002) used "tie-in" configuration for treatment of femoral and humeral fractures in 19 growing dogs (n=11) and cats (n=8), and in their study,

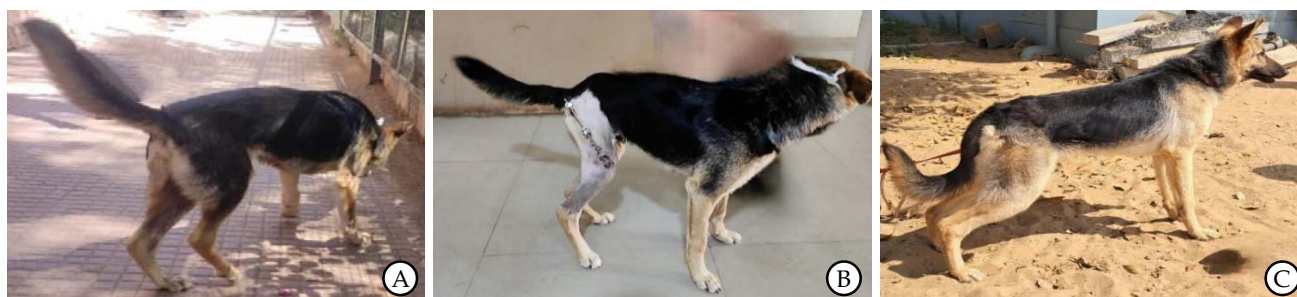
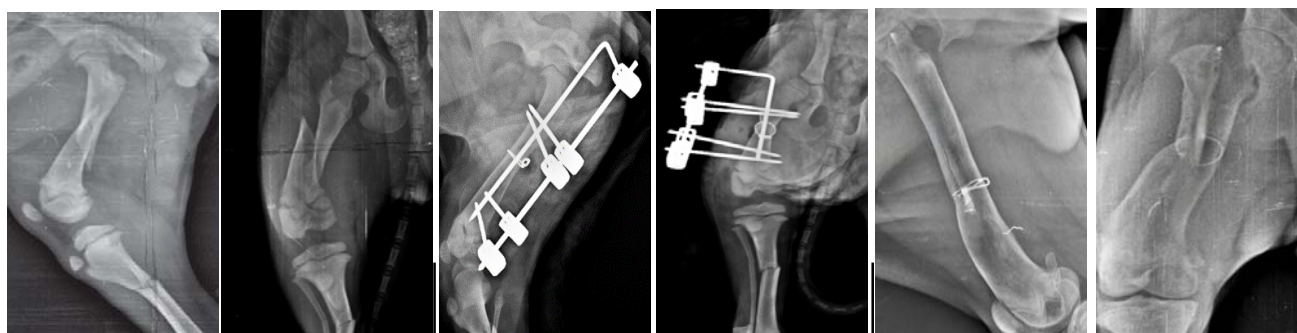


Fig. 1: Photographs of case C3 showing non-weight bearing on the affected limb before treatment (A); weight bearing with applied Tie-in ESF in 1st postoperative week (B); and completely normal limb function after ESF removal in 20th postoperative week (C).



A: Preoperative radiographs showing mid-shaft long oblique femur fracture.

B: Immediate postoperative radiographs: (2P:2D) ESF transcortical pin configuration, showing good reduction and alignment.

C: 10th week postoperative radiographs, after ESF assembly removal.

Fig. 2: (A-C) Pre- and Post-operative Radiographic findings of Case C1.

radiographic examination showed bone healing within 8 weeks in all of the patients.

In the present study, in one case (C5), radiographic examination during the 2nd, 4th, and 6th post-operative week revealed that the distal pointed end of IMP was piercing out through the cortex because of loosening of proximal end Tie-in ESF clamp. Every time the IMP was slightly withdrawn and the Tie-in clamp was tightened, with the final outcome of achievement of bone union and normal limb function.

Two cases (C6 and C7), which were showing signs of progress in fracture healing with the achievement of radiographic grade 3 at 2nd postoperative week interval, with intact ESF assembly, and excellent limb function in one case (C7) died in later study period due to unrelated causes. The mean period of ESF assembly removal was 43.00±4.02 days (range 34-64 days). In one case (C3) with transcortical pin configuration 2P:2D, 2nd transcortical pin of distal fragment was found broken at the threaded and non-threaded junction on 32nd day, but radiographic fracture healing was achieved at that period. Rao *et al.* (2017) used tie-in ESF configuration for the treatment of femoral and humeral diaphyseal fractures in dogs, where staged disassembly was performed in two cases on 30th and 45th postoperative

day, as linear ESF was removed after formation of primary callus, and the intramedullary pin was removed 2 weeks thereafter. In their study, tie-in configuration was removed between 30 and 55 days (mean 43.16±4.46 days). Devarapalli (2014) stabilized the femoral fracture in six dogs with the use of Tie-in configuration of type-I ESF and single IMP combination. In his study, the mean time of the ESF removal was 39.00±5.53 days (range 24-60 days), and all the fractures healed well.

Complications associated with Tie-in fixation in the present study were of short-term nature only, and did not affect the fracture healing progress and final outcome. These include slight pin tract exudation with in-situ ESF assembly in all cases, single site ESF clamp pressure in one case (C4), reduced stifle joint function without affecting limb usage in 6 cases (except C4 and C7). The pin tract exudation observed with intact ESF assembly during the fracture healing period stopped, and the clamp pressure sore and pin tract wounds healed within a period of one week post ESF assembly removal. The stifle joint movement became completely normal with regain of normal limb function in mean period of 9.83±2.38 days (range 3-18 days) after ESF assembly removal. Short-term minor complications are those that cause discomfort

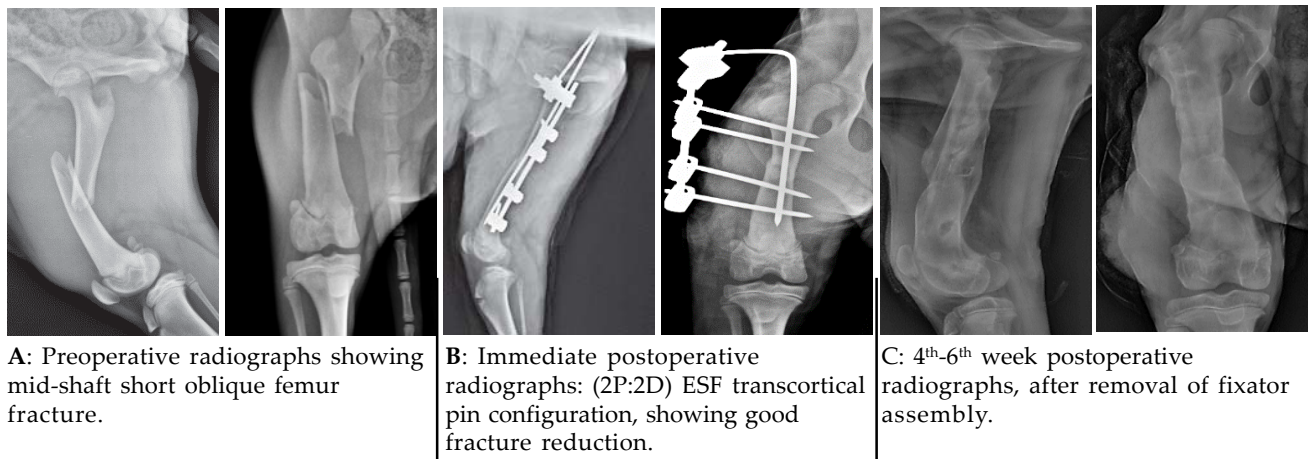


Fig. 3: (A-C) Pre- and post-operative radiographic findings of Case C2.

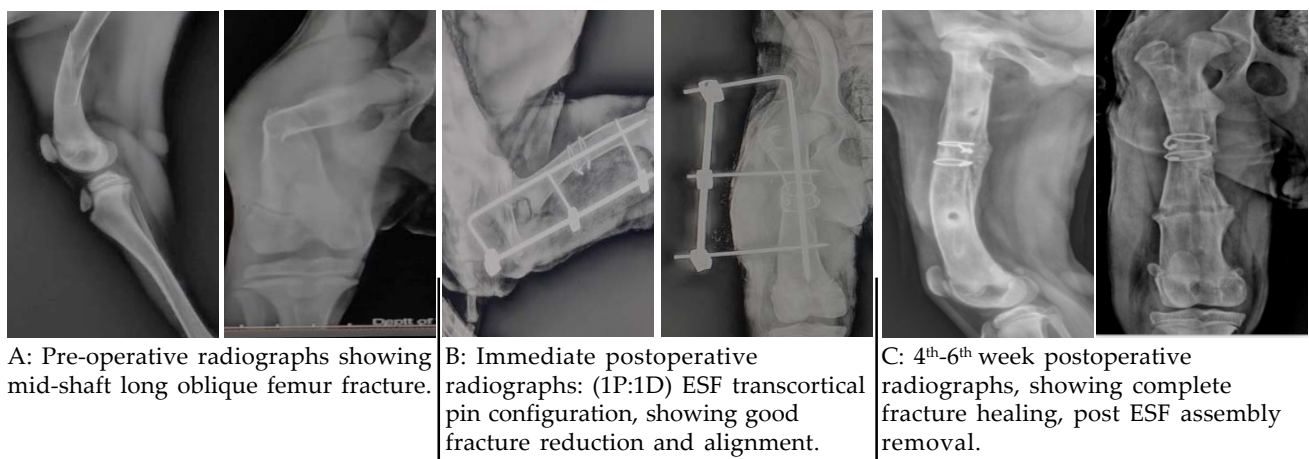


Fig. 4: (A-C) Pre- and post-operative radiographic findings of Case C8

to the patient or inconvenience to the client but do not result in failure of fracture healing (Egger, 1991).

It was concluded from this clinical study that application of Tie-in ESF assembly with negative profile transcortical pins in femoral mid-shaft fractures of young lesser body weight dogs can remain intact for a sufficient longer period to allow complete fracture healing, and the complications associated with applied ESF are of short-term nature only without affecting the fracture healing progress and final outcome.

References

- Aydin, U., Ozaydin, I., Aksoy, O., Ermutlu, C.S., Kilic, E., Yildiz, U. and Tanriverdi, E. 2022. Clinical and radiological evaluation of tie-in osteosynthesis with intramedullary threaded pin in diaphyseal humeral, tibial, and femoral fractures in dogs. *Kafkas Univ. Vet. Fak. Derg.* **28**: 593-599.
- Beever, L.J., Giles, K. and Meeson, R.L. 2018. Postoperative complications associated with external skeletal fixators in dogs. *Vet. Comp. Orthop. Traumatol.* **31**: 137-143.
- Carmichael, S. 1991. The external fixator in small Animal orthopaedics. *J. Small Anim. Pract.* **32**: 486-493.
- Corr, S. 2005. Practical guide to linear external skeletal fixation in small Animal. In *Pract.* **27**: 76-85.
- Devarapalli, B. 2014. Tie-in configuration of type-I external skeletal fixator with intramedullary pin for the fixation of femoral fractures in dogs. PhD thesis submitted to Sri Venkateswara Veterinary University, Tirupati (AP), India.
- Egger, E.L. and Greenwood, K.M. 1985. External skeletal fixation. In: *Textbook of Small Animal Surgery*, Slatter, D.H. (Ed.). W.B. Saunders, Philadelphia. pp 1972-1978.
- Egger, E.L. 1991. Complications of external fixation: a problem-oriented approach. *Vet. Clin. North Am. Small Anim. Pract.* **21**: 705-733.
- Egger, E.L. 1998. External skeletal fixation. In: *Current Techniques in Small Animal Surgery*, Bojrab, M.J. (Ed), 4th edn. Williams and Wilkins, Baltimore, USA. pp 941-950.
- Fossum, T.W. 2007. *Small Animal Surgery*, 3rd edn. Mosby Elsevier, Missouri USA. pp 930-931.
- Hammer, R.R.R., Hammerby, S. and Lindholm, B. 1985. Accuracy of radiologic assessment of tibia shaft fracture union in humans. *Clin. Ortho. Rel. Res.* **199**: 233-237.
- Johnson, A.L. 2007. Tibial and fibular diaphyseal fractures. In: *Text book of Small Animal Surgery*, Slatter, D.H. (Ed), 3rd edn. Cheryl S Hedlund. pp 1126-1142.
- Johnson, A.L. and Decamp, C.E. 1999. External skeletal fixation - Linear fixators. *Vet. Clin. North Am. Small Anim. Pract.* **29**: 1135-1152.
- Knudsen, C.S., Arthurs, G.I., Hayes, G.M. and Langley Hobbs, S.J. 2012. Long bone fracture as a complication following external skeletal fixation: 11 cases. *J. Small Anim. Pract.* **53**: 687-692.
- Larin, A., Eich, C.S., Parker, R.B. and Stubbs, W.P. 2001. Repair of diaphyseal femoral fracture in cats using interlocking intramedullary nails: 12 cases (1996-2000). *J. Am. Vet. Med. Assoc.* **219**: 1098-1104.
- Lewis, D.D., Cross, A.R., Carmichael, S. and Anderson, M.A. 2001. Recent advances in external skeletal fixation. *J. Small Anim. Pract.* **42**: 103-112.
- Lincoln, J.D. 1992. Treatment of open, delayed union, and nonunion fractures with external skeletal fixation. *Vet. Clin. North Am. Small Anim. Pract.* **22**: 195-207.
- Palmer, R.H., Hulse, D.A. and Polio, F. 1991. Pin loosening in external skeletal fixation. The effects of pin design and implantation site. *Proc. Vet. Orthopaed. Soc.* pp 18-50.
- Palmer, R.H., Hulse, D.A., Hyman, W.A. and Palmer, D.R. 1992. Principles of bone healing and biomechanics of external skeletal fixation. *Vet. Clin. North Am. Small Anim. Pract.* **22**: 45-68.
- Peirone, B., Camuzzini, D., Filippi, D. and Valazza, A. 2002. Femoral and humeral fracture treatment with an intramedullary pin/external fixator tie-in configuration in growing dogs and cats. *Vet. Comp. Orthop. Traumatol.* **15**: 85-91.
- Piermattei, D., Flo, G. and DeCamp, C. 2006. Fractures: classification, diagnosis, and treatment. In: *Brinker, Piermattei, and Flo's Handbook of Small Animal Orthopedics and Fracture Repair*, 4th edn. Saunders Elsevier, Missouri, USA. pp 25-159.
- Popkov, D.A., Popkov, A.V., Kononovich, N.A., Barbier, D., Ceroni, D., Journeau, P. and Lascombes, P. 2014. Experimental study of progressive tibial lengthening in dogs using the Ilizarov technique. Comparison with and without associated intramedullary K-wires. *Orthop. Traumatol. Surg. Res.* **100**: 809-814.
- Radke, H., Aron, D.N., Applewhite, A. and Zhang, G. 2006. Biomechanical analysis of unilateral external skeletal fixators combined with IM pin and without IM pin using finite element method. *Vet. Surg.* **35**: 15-23.
- Rao, J.R., Kumar, V.G., Rao, T.M., Kumar, D.P., Reddy, K.C.S. and Raghavender, K.B.P. 2017. Use of Tie-in configuration technique in the repair of femoral and humeral diaphyseal fractures in dogs. *Int. J. Adv. Res.* **5**: 436-442.
- Shete, S.M. and Gaikwad, S.J. 2020. Tie-in configuration for management of femur fracture in a pup. *Intas Polivet* **21**: 206-207.
- Vallefuoco, R., Le Pommellet, H., Savin, A., Decambon, A., Manassero, M., Viateau, V. and Fayolle, P. 2016. Complications of appendicular fracture repair in cats and small dogs using locking compression plates. *Vet. Comp. Orthop. Traumatol.* **29**: 46-52.
- Yardimci, C., Onyay, T., Inal, K.S., Ozbakir, B.D. and Ahmet, O.Z.A.K. 2018. Management of humeral fractures in dogs by using semicircular external fixator and intramedullary pin tie-in combination. *Kafkas Univ. Vet. Fak. Derg.* **24**: 129-136.