

## Evaluation of two techniques of pericardiostomy for the management of pericarditis in cattle

D.R. Manjunatha<sup>1†</sup>, R.V. Suresh Kumar<sup>2</sup>, V. Shivakumar<sup>3</sup>, P. Veena<sup>4</sup>, N. Priyanka<sup>3</sup>, D. Vilas<sup>3</sup>, B.R. Balappanavar<sup>4</sup> and N. Nagaraju<sup>5</sup>

Karnataka Veterinary, Animal and Fisheries Sciences University, Bidar- 585401 (Karnataka)

<sup>1</sup>Associate Professor & Head, Department of Veterinary Clinical Complex, <sup>3</sup>Assistant Professor, <sup>4</sup>Associate Professor, <sup>5</sup>Associate Professor and Head, Department of Veterinary Surgery & Radiology, Veterinary College, Hassan, <sup>2</sup>Professor & University Head, <sup>4</sup>Professor, Department of Veterinary Surgery & Radiology, College of Veterinary Sciences, SVVU, Triupati

DOI: 10.5958/0973-9726.2024.00028.6

Received: March, 2024

Twelve cases of cattle presented to the Veterinary College Hospital, Hassan, over a period of five years with the history of pyrexia, decreased milk yield, coughing, recurrent bloat and dyspnea were used in the study. Upon clinical examination it was observed that all the cattle were showing jugular pulsation, and brisket and submandibular oedema. These cattle were subjected to haematological, biochemical, ultrasonographic, radiographic and electrocardiographic evaluation. Based on the findings all the cases were diagnosed as those of pericarditis. These cases were randomly divided into two groups of six animals each and subjected for ultrasound aided pericardiostomy using Foley's catheter No. 18 with the help of artificial inseminating gun as stylet and a 28 FG trocar catheter under local analgesia in standing position. The catheter was fixed to the skin and kept in position for 7-10 days. In serous or purulent pericarditis cases Foley's catheter was employed for pericardiostomy technique to drain the pericardial fluid, however, in cases with fibrinous pericarditis 28 FG trocar catheter was found to be more helpful to drain the pericardial fluid.

**Key words:** Cattle, Foley's catheter, Pericardiostomy, Pericarditis, Trocar catheter

Pericarditis is an inflammation of the pericardium with an accumulation of serous or fibrinous exudates. It is often attributed to a reticular foreign body that has penetrated the reticular wall, diaphragm and pericardial sac (Radostits *et al.*, 2007). The incidence of traumatic pericarditis was found more in pregnant or recently parturated animals, might be due to increased intra-abdominal pressure pushing the foreign body towards the thorax (Athar *et al.*, 2012). The diagnosis of pericarditis in cattle is generally based on clinical examination, pericardiocentesis, ultrasonography and thoracic radiography (Imran *et al.*, 2011). Prominent clinical signs are tachycardia, muffled heart sounds, asynchronous heart sounds such as rubbing or splashing sounds, jugular vein distension and brisket oedema (Braun *et al.*, 2007). In the present study, ultrasound aided 18 FG Foley's catheter with the help of AI gun stylet (Fig. 1a) and 28 FG trocar catheter (Fig. 1b) pericardiostomy techniques were compared in six cases each.

### Materials and Methods

Twelve cattle aged 6 m to 10 yr presented to Veterinary College Hospital, Hassan, over a period of five years, with the history of fever, decreased milk yield, depression, coughing, recurrent bloat, dyspnea, jugular pulsation, brisket and submandibular oedema (Braun *et al.*, 2007) were subjected to haematological, biochemical, electrocardiographic, ultrasonographic and radiographic evaluation. Based on history, clinical signs, haemato-biochemical changes, electrocardiogram, ultrasonographic and radiographic findings, pericarditis was diagnosed. The cases were randomly divided into two groups of six animals each. In group I (Table 1), the animals were subjected to ultrasound aided pericardiostomy under local analgesia in standing position by making a nick incision using No. 11 BP blade on the skin at the 5<sup>th</sup> intercostal space separating muscles by blunt dissection, and then 18 G Foley's catheter was inserted into pericardial space with the help of artificial insemination gun (AI) as stylet (Fig. 2) and the catheter was fixed to the skin. The pericardial fluid was drained. In group II (Table 2) the animals were subjected to ultrasound aided pericardiostomy under local analgesia in standing position. A nick incision was made with No. 11 BP blade on the skin at the 5<sup>th</sup> intercostal space and the muscles were separated by blunt dissection and then a 28 FG trocar catheter was inserted into the pericardial space and the catheter was fixed to the skin (Fig. 3). The pericardial fluid was drained.

In both groups the pericardial cavity was flushed with 2 L of warm normal saline followed by 200 mL of metronidazole solution once daily for five days and the catheter was kept in position for 7-10 days.

In animals which had the evidence of radio-dense foreign body in the reticulum, rumenotomy was performed after pericardiostomy, under left paravertebral nerve block (Tranquilli *et al.*, 2007) and the foreign bodies were retrieved employing standard surgical procedure.

<sup>†</sup>Corresponding author; E-mail: manjuvet328@gmail.com

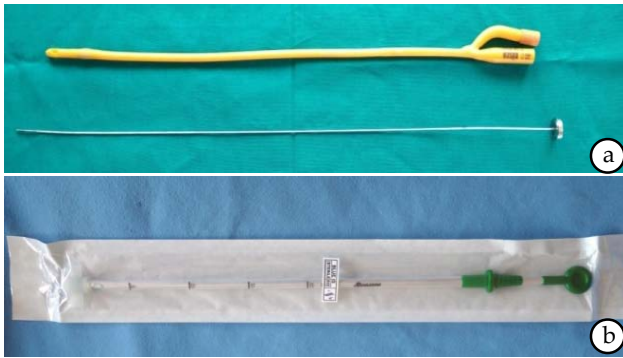


Fig. 1: a) 18 FG Foley's catheter and AI gun stylet; b) 28 FG trocar catheter.

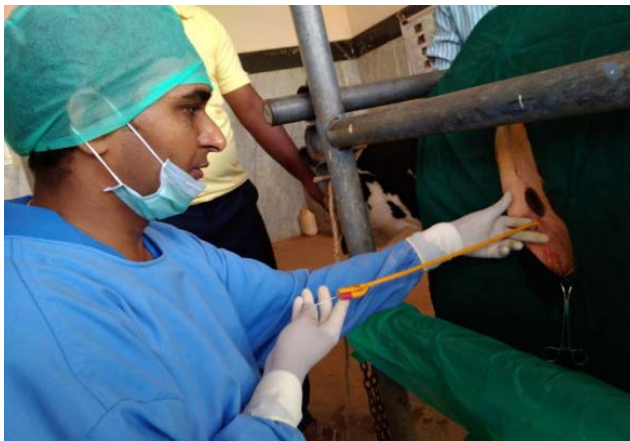

Fig. 2: Group I- placement of Foley's catheter into pericardial sac with the help of AI gun stylet

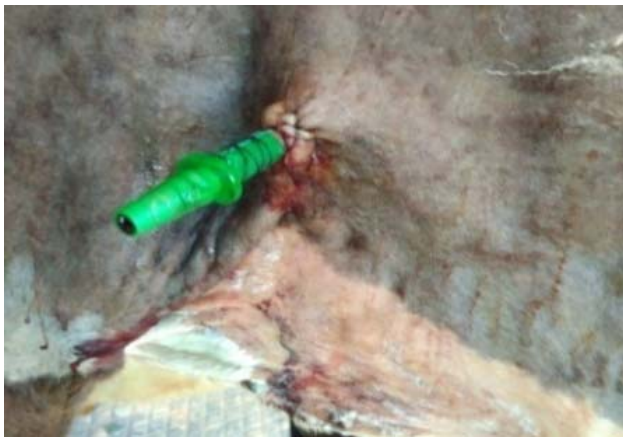

Fig. 3: Group II- fixing of 28FG trocar catheter to skin.

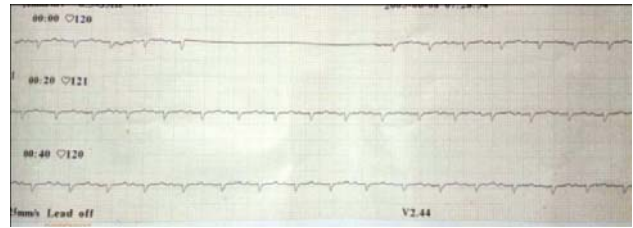


Fig. 4: ECG depicting decreased amplitude of QRS complex.

**Results and Discussion**

Cattle suspected for pericarditis showed common clinical signs such as fever, decreased milk yield, depression, cough, recurrent bloat, dyspnoea, jugular pulsation, brisket and submandibular oedema, abduction of elbow, fluid splashing heart sound in all the 12 animals (Imran *et al.*, 2011; Tharwat, 2011; Kumar *et al.*, 2012; Anteneh and Ramaswamy, 2015).

In cattle with pericarditis, the haemato-biochemical values showed reduced haemoglobin, total erythrocyte count and packed cell volume suggestive of anaemia. The animals also showed leukocytosis with shift to left and slightly higher total protein (Table 3). Similar observations were also made by Athar *et al.* (2012). Hussein and Staufenbiel (2014) reported leukocytosis with regenerative shift to the left in buffaloes with traumatic pericarditis and vegetative endocarditis.

All the 12 cattle were subjected to electrocardiography by employing base-apex lead system. Electrocardiograms showed non-significant increase in the heart rate, increased P-R interval and decreased QRS complex in pericarditis affected animals (Fig. 4). Similar observations were also made by Reef and Mc Guirk (1996), Tharwat (2011) and Athar *et al.* (2012), which might be attributed to monomorphic ventricular tachycardia.

Ultrasound examination in 12 animals suspected for pericarditis revealed the presence of anechoic area with echogenic to hyperechogenic deposits in the region of pericardial sac. It indicated mild to massive fluid accumulations with or without fibrin threads along with mild to moderate compression of cardiac chambers on both left and right side between 4<sup>th</sup> and 5<sup>th</sup> intercostal space (Fig. 5). Ultrasonography helped

**Table 1:** Group I cattle subjected for ultrasound aided pericardiostomy using Foley's catheter with the help of artificial inseminating (AI) gun as stylet.

Case No.	Breed	Age	Gender	Pregnancy status	Brisket oedema	Subman-dibular oedema	Abduction of elbow	Jugular pulsation
1	Jersey cross breed	4.5 yr	M	NA	+++	+++	+++	+++
2	HF cross breed	2 yr	F	1 m after calving	+	+	+	+
3	HF cross breed	4 yr	F	6 m	+++	+++	+++	+++
4	Amrit Mahal	8 m	M	NA	+++	+++	+++	+++
5	HF cross breed	6 yr	F	7 m	+++	+++	+++	+++
6	Jersey cross breed	7 yr	F	5 m	+++	+++	+++	+++

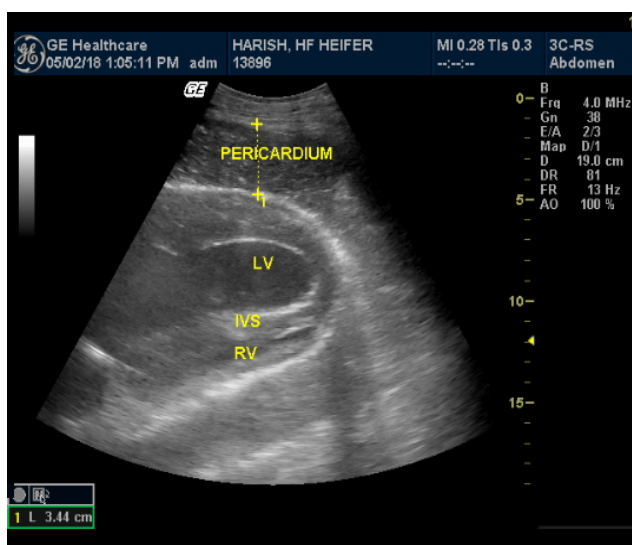
**Table 2:** Group II details of cattle subjected for ultrasound aided pericardiostomy using 28 FG trocar catheter.

Case No.	Breed	Age	Gender	Physiological Status	Brisket oedema	Subman dibular oedema	Abduction of elbow	Jugular pulsation
1	HF cross breed	3.5 yr	F	Non pregnant	+++	+++	+++	++
2	Jersey cross breed	5 yr	F	15 days after calving	+++	+++	+++	+++
3	HF cross breed	8 yr	F	8 m pregnant	++	+	++	++
4	Amrit Mahal	5.5 yr	M	NA	++	+	+	+
5	Jersey cross breed	4.5 yr	F	7 m pregnant	+++	++	++	++
6	Jersey cross breed	2.5 yr	F	1 m after calving	+++	++	+++	+++

**Table 3:** Physiological, haematological and biochemical values in group I and II affected with pericarditis.

Parameters	Group-I (Mean±SE)	Group-II (Mean±SE)
Heart rate (beats/min)	100.67± 1.52	99.67± 2.72
Respiratory rate (breaths/min)	27.2±0.5	24.34± 2.22
Hemoglobin(g/dL)	6.94±0.18	7.12± 0.35
Packed cell volume (PCV) (%)	23.2±0.92	24.12±1.71
Total erythrocyte count (TEC) (millions/μL)	5.04±0.13	5.21±0.25
Total leukocyte count (TLC) (cells /μL)	13500±642.28	14391.67±783.02
DLC- Lymphocytes (%)	51.34 ±0.82	52.4±1.07
DLC- Neutrophils (%)	42.17±0.83	41±0.82
DLC- Monocytes (%)	4.33 ±0.42	4.57±0.41
DLC- Eosinophils(%)	2.21±0.15	1.72±0.41
Platelets (lakhs/μL)	3.2±0.18	3.35±0.17
Alanine amino transferase (ALT)(IU/L)	54.2±1.33	55.2±0.72
Aspartate amino transferase (AST)(IU/L)	77±3.61	76.4±3.84
Total protein (g/dL)	8.81±0.15	8.53±0.22
Glucose (mg/dL)	92.3±2.46	93.87±2.29
Plasma fibrinogen (g/dL)	0.74±0 .01	0.73 ±0 .02

to confirm the pericarditis (Braun *et al.*, 2007; Imran *et al.*, 2011; Athar *et al.*, 2012 and Kumar *et al.*, 2012). However, Abdelaal *et al.* (2009) reported the presence



**Fig. 5:** Ultrasound image showing anechoic area with echogenic to hyperechogenic deposits in the pericardial sac with mild compression of cardiac chamber.

of hypoechoic contents in pericardial sac corresponding to pus and suppurative pericarditis.

Radiographic examination was aimed at localizing the foreign bodies. Left lateral caudoventral thoracic and reticular radiography in standing position was effective in identifying the presence or absence of radio-opaque foreign body in the thorax or reticulum. Out of 12 animals only 5 animals showed the presence of radio-opaque foreign body. The radiographic evidence of foreign body was less, probably due to the presence of fluid and thick radio dense adhesions, which could have obscured the foreign body from the view (Chaudhary *et al.*, 2009 and Hussain *et al.*, 2018). Similar observations were also made by Braun (2009), Imran *et al.* (2011), Athar *et al.* (2012), Sasikala *et al.* (2018) and Premkumar *et al.* (2019).

Pericardiostomy by using Foley’s catheter No. 18 was good enough to drain pericardial fluids and flush the pericardial cavity with warm normal saline and metronidazole, which helped in reducing the infection. In one case, blockage of Foley’s catheter was observed, as also observed by Manjunatha *et al.* (2018).

Pericardiostomy using 28 FG trocar catheter was very helpful in draining of pericardial fluid along with debris. In one case the catheter came out of the pericardium but no blockage was seen. Jesty *et al.* (2005) performed ultrasound aided pericardiocentesis using thoracic trocar catheter through left 5<sup>th</sup> intercostal space.

In serous and slightly purulent pericarditis cases Foley's catheter was good enough to drain the pericardial fluid, whereas in slightly fibrinous pericarditis cases Foley's catheter was blocked due to fibrin material or debris, in those cases 28 FG trocar catheter was very much useful to drain the fluids (Linde and Melgarejo, 2010). However, the cost of 28 FG trocar catheter was much more as compared to Foley's catheter (Kathirvel *et al.*, 2014).

It can be concluded from present study that, in serous or purulent pericarditis cases Foley's catheter can be employed for pericardiostomy technique to drain the pericardial fluid; however, in cases with fibrinous pericarditis, 28 FG trocar catheter is much useful to drain the pericardial fluid. Ultrasonography is a good tool for early diagnosis and differentiation of different forms of pericarditis. Ultrasound aided pericardiostomy technique is less painful as compared to pericardiotomy. So early recovery may be seen and the cost of treatment can be reduced by early diagnosis and timely treatment with pericardiostomy techniques in animals suffering with pericarditis. In advance stage of pregnancy, early diagnosis and treatment will help to prolong the life of mother and save the life of young one.

## References

- Abdelaal, A.M., Floeck, M., ElMaghawry, S. and Baumgartner, W. 2009. Clinical and ultrasonographic differences between cattle and buffaloes with various sequelae of traumatic reticuloperitonitis. *Vet. Medicina* **54**: 399-406.
- Anteneh, M. and Ramswamy, V. 2015. Hardware disease in bovine (review article). *Acad. J. Anim. Dis.* **4**: 146-159.
- Ashwani Kumar, Saini, N.S., Mohindroo, J. and Sood, N.K. 2012. Ultrasonographic features of normal heart and liver in relation to diagnose pericarditis in bovine. *Indian J. Anim. Sci.* **82**: 1489-1494.
- Athar, H., Parrah, J.D., Moulvi, B.A., Singh, M and Dedmari, F.H. 2012. Pericarditis in bovines- A review. *Int. J. Adv. Vet. Sci. Tech.* **1**: 19-27.
- Braun, U. 2009. Traumatic pericarditis in cattle: Clinical, radiographic and ultrasonographic findings. *Vet. J.* **182**: 176-186.
- Chaudhary, K.S., Thorat, M.G., Yadav, G.U., Mulani, J.B., Suryawanshi, A.A. and Ingale, S.S. 2009. Role of radiological examination in diagnosis of foreign body in bovines. *Vet. World* **9**: 339.
- Hussein Awad, H. and Rudolf, S. 2014. Clinical presentation and ultrasonographic findings in buffaloes with congestive heart failure. *Turkish J. Vet. Anim. Sci.* **38**: 534-545.
- Hussain, T., Kumar, A., Kumar, A. and Bansal, B.K. 2018. Ferroscopy for detection of metallic foreign body in traumatic pericarditis and pleural effusions in cattle and buffaloes. *J. Entomol. Zool. Studies* **6**: 23-26.
- Jesty, S.A., Sweeney, R.W., Dolente B. A. and Reef, V. B. 2005. Idiopathic pericarditis and cardiac tamponade in two cows. *J. Am. Vet. Med. Assoc.* **226**: 1555-1558.
- Kathirvel, S., Rajendran, N., Dharmaceelan, S., Vijayakumar, G., Subramanian, M. and Balasubramaniam, G.A. 2014. Ultrasound aided pericardiocentesis for the management of serous form of traumatic pericarditis in cattle. *Indian J. Vet. Surg.* **35**: 57-58.
- Linde, A. and T. Melgarejo, 2010. Interventional treatment of pericardial effusion. *SRX Vet. Sci.* doi: 10.3814/2010/725492. [www.hindawi.com](http://www.hindawi.com). Access date: 24.03.2011.
- Manjunatha, D.R., Nagaraju, N, Basavarju, B., Suresh, L., Dilipkumar, D., Shivaprakash, B.V. and Vasanth, M.S. 2018. Traumatic pericarditis in bovines: Its diagnosis and surgical management. *Indian J. Vet. Surg.* **39**: 96-99.
- Premkumar, C., Dharmaceelan, S., Rajendran, N. and Jagadeeswaran, A. 2019. Ultrasound diagnosis and pericardiocentesis under local analgesia for traumatic pericarditis in cattle - a clinical study. *Pharma Innov. J.* **8**: 92-96.
- Radostits, O.M., Gray, C.C., Hinchcliff, K.W and Constable, P.D. 2007. *Veterinary Medicine: A Textbook of the Diseases of Cattle, Horses, Sheep, Pigs and Goats*, 10<sup>th</sup> edn. Saunders Elsevier, Philadelphia. pp 430-432.
- Reef, V.B. and Mc Guirk, S.M. 1996. Diseases of the cardiovascular system. *In: Large Animal Internal Medicine*, Smith B.P. (Ed), 2<sup>nd</sup> edn. Mosby, USA. pp 532-536.
- Sasikala, K., Vijayakumar, G., Sivaraman, S. and Balasubramaniam, G.A. 2018. Clinico diagnostic studies on traumatic reticulopericarditis in cattle - A review of 56 cases. *Int. J. Curr. Microbiol. Appl. Sci.* **7**: 513-523.
- Sheikh Imran, Tyagi, S.P., Amit Kumar, Adarsh Kumar and Shivali Sharma 2011. Ultrasonographic application in the diagnosis and prognosis of pericarditis in cows. *Vet. Med. Int.* **1**: 4061-4785.
- Tharwat, M. 2011. Traumatic pericarditis in cattle: sonographic echocardiographic and pathologic findings. *J. Agri. Vet. Sci.* **4**: 45-59.
- Tranquilli, W.J., Thurmon, J.C. and Grimm. K.A. 2007. *Lumb and Jones' Veterinary Anesthesia and Analgesia*, 4<sup>th</sup>edn. Blackwell Publishers. pp 731-743.