

Surgical management of a sebaceous adenocarcinoma in ear canal of a dog

Sulekha^{1†}, Sandeep Kumar², Babu Lal Jangir¹ and Paras Saini¹

Lala Lajpat Rai University of Veterinary and Animal Sciences, Hisar-125 004 (Haryana)

¹PG Scholar, ²Assistant Professor, Department of Veterinary Surgery and Radiology, College of Veterinary Sciences, Hisar

DOI: 10.5958/0973-9726.2024.00014.2

Received: December, 2023

A non-descript female dog of 8 yr, weighing 22 kg, was presented with a history of growth in the right ear canal since 5-6 months along with foul smelling discharge. On visual examination it was observed that the growth was nodular, non-ulcerative and its origin was from the upper part of vertical ear canal (Fig. 1). Straw yellow coloured discharge was present in the affected ear. Other physiological parameters such as heart rate, respiratory rate and rectal temperature were normal. Otoscopic examination of the right ear revealed no evidence of deep roots or any remnant of the growth in the ear canal. Skull radiograph showed no growth in the vertical and horizontal ear canals. Thoracic radiograph (Fig. 2) showed lungs having miliary pattern, suggestive of metastatic lesions.

The animal was aseptically prepared for surgery and tumour mass was excised surgically using an electrocautery under general anaesthesia.

Postoperatively ear drop Ciplox was advised (3 drops, 3 times a day) and cleaning of the ear canals with Epiotic solution once daily. Antibiotic ceftriaxone (25 mg/kg body wt, i.v.) was advised for 5 days and anti-inflammatory analgesic drug meloxicam (0.2 mg/kg body wt, i.m.) for 3 days.

Microscopically was characterized by the presence of large, pleomorphic nuclei containing prominent nucleoli, intracytoplasmic vacuolations

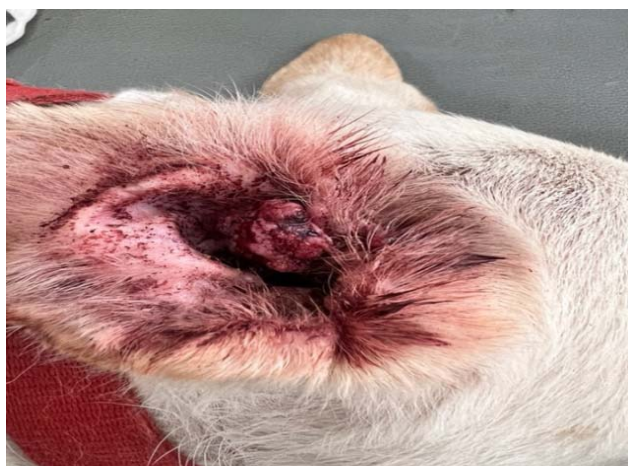

Fig. 1: Nodular mass in right ear.

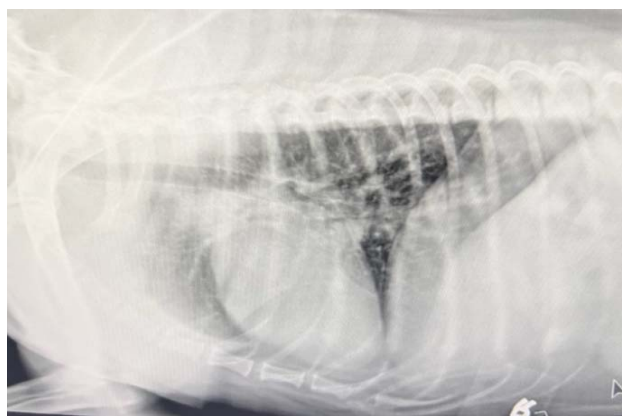

Fig. 2: Lateral radiograph of thorax shows miliary pattern, suggestive of metastatic lesions.

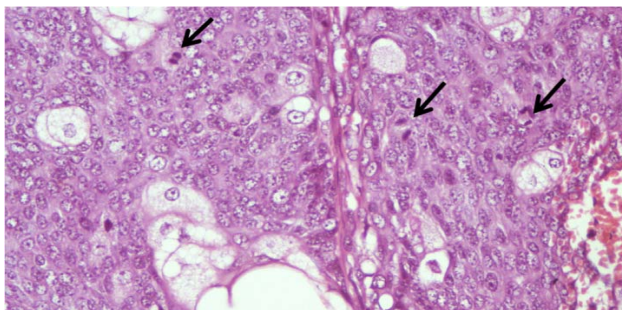


Fig. 3: Sebaceous carcinoma depicting moderately pleomorphic neoplastic cells and presence of mitotic figures (arrows) (H&E ×400)

and numerous mitotic figures along with various sized lobules separated by fibrovascular connective tissue (Fig. 3). Tumours of sebaceous glands can be classified according to the level of cell maturation, such as nodular hyperplasia, sebaceous adenoma, sebaceous epithelioma, and sebaceous adenocarcinoma (Amaravathi *et al.*, 2017). In the present case, a rare tumour of sebaceous gland was successfully treated by surgical intervention.

Reference

Amaravathi, M., Murthy, R.V.R., Naik, S.H., Nasreen, A., Srilatha, Ch., Sujatha, K., and Saibaba, M. 2017. Sebaceous gland adenocarcinoma in a dog. *J. Livestock Sci.* 8: 18-20.

[†]Corresponding author; E-mail: sulks.vet@gmail.com