

Evaluation of stainless steel and titanium miniplate systems for tibio-tarsus fracture stabilization in pigeons (*Columba livia*)

D. Jahangirbasha¹, D. Dilipkumar², B.V. Shivaprakash³, B. Bhagavantappa⁴, Kartik Bidari^{1*}, Gurudev Karajagi¹ and Syeda Mumtaz¹

Karnataka Veterinary and Fisheries Sciences University, Bidar-585 401 (Karnataka)

¹PG Scholar, ⁴Professor and Head, Department of Veterinary Surgery and Radiology, Veterinary College, Bidar;

²Dean PG and ³Director Research, KVAFSU, Bidar.

DOI No.: 10.5958/0973-9726.2026.00010.2

Accepted: Jan. 2026

Twelve pigeons (*Columba livia*) presented with tibiotarsal fractures were randomly and equally divided into two groups and treated using a bone plating technique. In one group, a 1.3 mm, 6-hole stainless steel miniplate was used, while in the other a 1.3 mm, 6-hole titanium miniplate was used for fixation. Fixation was performed via open reduction and internal fixation (ORIF) under anaesthesia induced with xylazine HCl (3 mg/kg) and ketamine HCl (50 mg/kg). Clinical and radiographic healing were evaluated on days 7, 14, 28, 45, and 60. Fracture healing occurred through primary union in all cases. Weight bearing was achieved in all birds by day 10, and complete functional recovery was observed by day 21. Comparative evaluation revealed similar healing outcomes between the two groups; however, stainless steel miniplates were associated with fewer implant-related complications than titanium miniplates.

Keywords: Miniplate, Osteosynthesis, Pigeon, Radiographic evaluation, Tibio-tarsus fracture

Fractures are common in avian practice, particularly in birds weighing less than 1000 g (Helmer and Redig, 2006). Avian orthopaedics remains a developing field, and advancements in this area are of considerable value to clinical practitioners. Bone plate fixation is infrequently employed in avian surgery due to several limitations, including the need for exceptionally small and relatively expensive implants, technical difficulty requiring specialized surgical expertise, prolonged anaesthesia and operative time, and extensive surgical exposure that may result in soft tissue damage (Bennett and Kuzma, 1992; Miller, 1998).

Despite these challenges, bone plates offer significant advantages, including rigid internal fixation by counteracting bending, rotational, shear, and compressive forces. They help maintain anatomical reduction and alignment without compromising joint function, thereby facilitating early return to function (Levitt, 1989). Additionally, bone plates can be left *in situ* after fracture healing unless complications arise (Miller, 1998).

In avian species, bone plates have been successfully utilized for tibiotarsal fracture repair in a bald eagle (Davidson *et al.*, 2005) and an African grey parrot, for tibial osteotomy in rhea (Bush *et al.*, 1976) and emu

(Bauk *et al.*, 1987), and for corrective osteotomy of a malunited humeral fracture in a turkey vulture (Kuzma and Hunter, 1998). Gull *et al.* (2012) also evaluated three different miniplate systems for fracture stabilization in pigeons.

The present study was undertaken to evaluate the feasibility and application of 6-hole miniplate systems, using stainless steel and titanium implants, for the repair of tibiotarsal fractures in pigeons.

Materials and Methods

Twelve pigeons (*Columba livia*) with tibiotarsal fractures were treated using open reduction and internal fixation (ORIF) by bone plating with 6-hole, 1.3 mm miniplates made of either stainless steel or titanium, following the fundamental principles of fracture fixation commonly applied in mammalian orthopaedics. The birds were randomly and equally allocated into two groups. Group I birds were treated with stainless steel plates, whereas in group II birds titanium plates were used.

The pigeons weighed between 230 g and 265 g, and were of either sex with fractures involving either limb. Clinically, the birds were presented with an inability to fly and showed signs of non-weight bearing on the affected limb, which was typically held elevated and flexed. Some birds also exhibited hopping movements and tended to remain seated in one place for prolonged periods.

On physical examination, all birds were found to be in good body condition with adequate hydration. Palpation of the tibiotarsal area elicited pain, and the birds resisted handling. Swelling and subcutaneous haemorrhage were evident, accompanied by dark discolouration of the overlying skin. Owing to the minimal musculature surrounding the tibiotarsus, the location of the fracture and movement of the fracture fragments could be easily appreciated during palpation.

Radiographic examination was performed using orthogonal projections (craniocaudal and medio-lateral views) to determine the type and location of the fracture and to evaluate the dimensions of the tibiotarsus. Preoperative measurements of cortical thickness and bone length aided in selecting the

*Corresponding author; E-mail: kartikbidari2@gmail.com

appropriate implant size for the study. All birds included in the study were presented with mid-diaphyseal transverse fractures of the tibiotarsus.

The implants and instruments required for bone plating, including 1.3 mm, 6-hole stainless steel and titanium miniplates, 1.3 mm cortical screws ranging from 6 mm to 8 mm in length, a 1.2 mm drill bit, a universal handheld drill machine, and a screwdriver, were sterilized by autoclaving. Additionally, a general surgical instrumentation set consisting of a No. 3 BP handle compatible with a No. 15 blade, rat-tooth Adson forceps, curved mosquito forceps, and a 4-inch needle holder was also sterilized. The procedure also required sterile drapes, sterile mops, poliglecaprone-25 (No. 4-0) for muscle suturing, and polypropylene (No. 4-0) for skin suturing.

The birds were administered preoperative injections of meloxicam (0.2 mg/kg body weight, i.m.) and enrofloxacin (10 mg/kg, i.m.). General anaesthesia was achieved by intramuscular administration of xylazine HCl (3 mg/kg) and ketamine HCl (50 mg/kg) into the pectoral muscles using an insulin syringe. The minimum number of feathers required to obtain a clean and sterile surgical field was plucked. The birds were then positioned in lateral recumbency on a thermostatically controlled heating pad, with the head and neck maintained in an elevated position. The surgical site was prepared aseptically using standard protocol, and the distal extremity of the limb was wrapped with a cotton bandage. The birds were subsequently draped with sterile surgical drapes, and the affected limb was exposed through an opening in the drape to facilitate a mediolateral approach to the tibiotarsus.

The skin was incised medially along the shaft of the tibiotarsus. The fibularis longus muscle, tibialis cranialis muscle, and the medial head of the gastrocnemius muscle were separated to expose the fracture site. The fracture fragments were reduced and aligned by manual manipulation and the application of slight traction. The bone plate (stainless steel or titanium) was then positioned over the medial surface of the tibiotarsus. A hole in the bone plate nearest to the fracture site on the proximal fracture fragment was drilled perpendicular to the plate using a 1.2 mm drill bit attached to a universal hand drill. The drill was advanced across the bone diaphysis through both cortices, ensuring that the drill site was at least 0.5 mm away from the fracture line to avoid the formation of cracks and splintering. The site was continuously irrigated with sterile normal saline during drilling to cool the drill bit, thereby preventing thermal necrosis and flushing out debris from the drilled hole. A screw of appropriate length was then inserted into the drill hole and tightened using an orthopaedic screwdriver until it engaged the far cortex, thereby securing the plate to the bone. The procedure was repeated for the hole nearest to the fracture site on the distal fracture fragment, followed by placement of bicortical screws

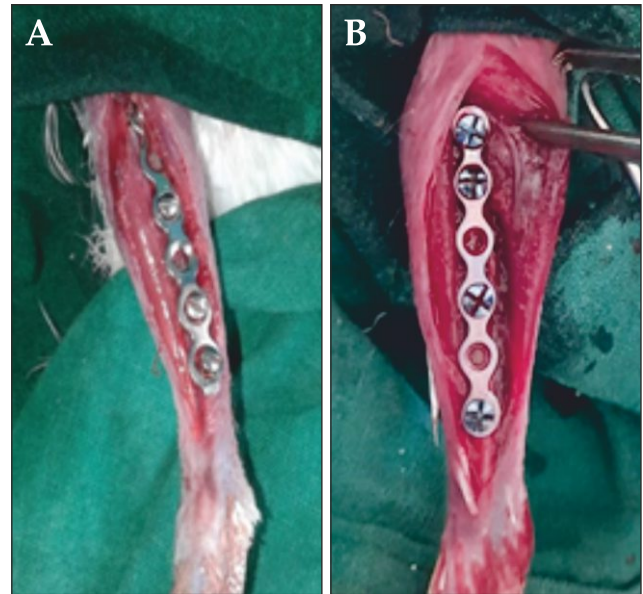


Fig. 1: Application of the bone plate: stainless steel (A), titanium (B).

in the proximal-most and distal-most screw holes, with two screws each in the proximal and distal fragments (Fig. 1).

The surgical site was lavaged with 5% povidone-iodine diluted in normal saline and thoroughly mopped to remove all residual fluid. The muscles were apposed using poliglecaprone-25 No. 4-0 in a continuous pattern, and the skin was sutured with polypropylene No. 4-0 in an interrupted pattern. The wound site was dressed, and additional support was provided through external immobilization using bandage and tape reinforced with ice-cream sticks to stabilize the site and prevent auto-mutilation.

Postoperative radiographic evaluation of implant placement and fracture stabilization was performed while the birds were still under anaesthesia (day 0). The birds recovered smoothly from anaesthesia approximately 15-20 min after the surgical procedure.

After surgery, the birds were housed individually in aerated cardboard boxes to restrict movement for up to 12 days. Postoperatively, meloxicam (0.2 mg/kg, i.m.) was administered once daily for 5 days, and enrofloxacin (10 mg/kg, i.m.) was administered once daily for 7 days. Antiseptic wound dressing was also performed on alternate days for up to 10 days. Radiographic evaluation to assess the progression of fracture healing was carried out on days 7, 15, 30, 45, and 60. The birds were clinically monitored for assessment of lameness until complete, painless weight-bearing was observed, and to evaluate any postoperative complications.

Results and Discussion

Tibiotarsus fractures are among the most common orthopaedic problems encountered in birds. These fractures are usually located a few millimeters distal to

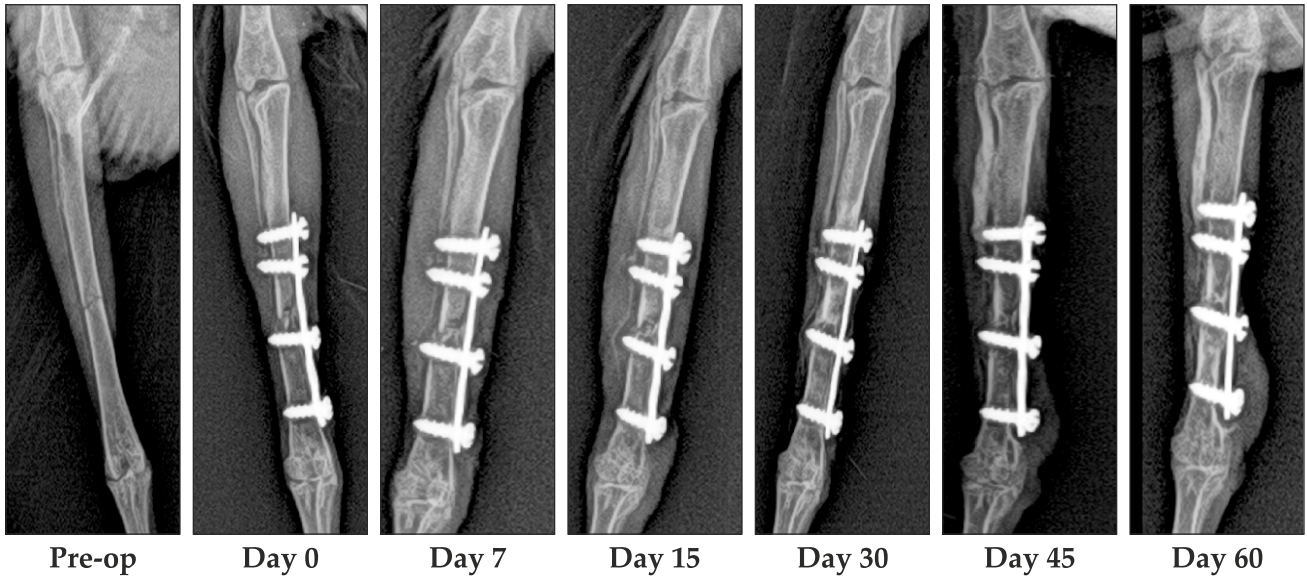


Fig. 2 A: Group I: Radiographic observations at different intervals

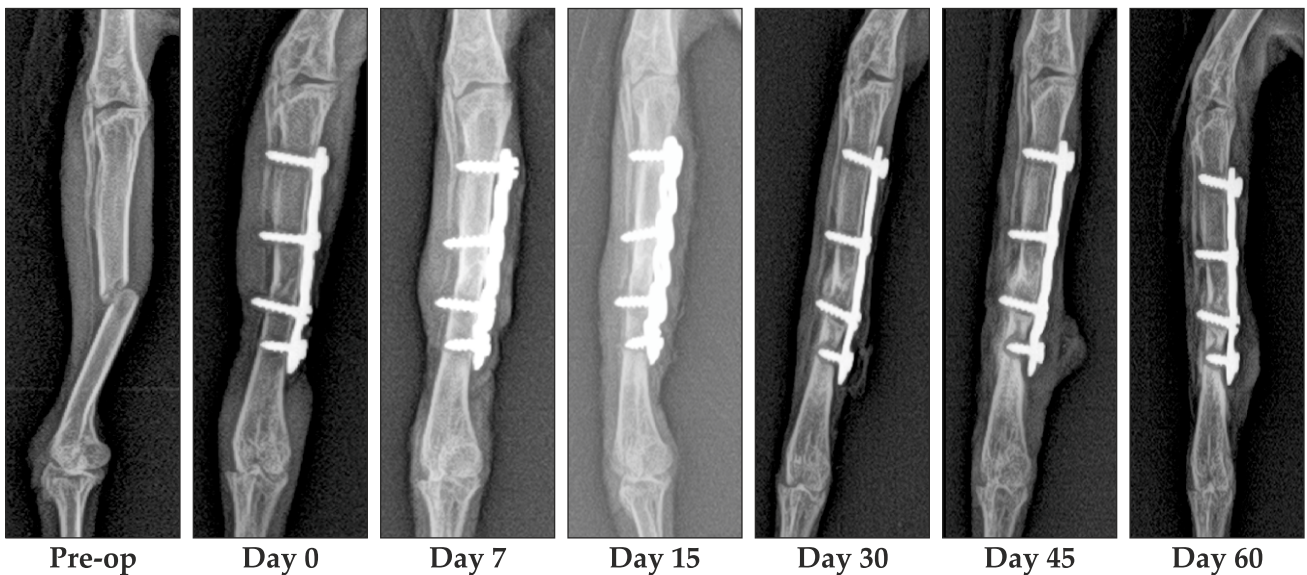


Fig. 2 B: Group II: Radiographic observations at different intervals

the fibular crest, where the tibiotarsus changes from an almost triangular shape proximally to a rounder configuration distally (Harcourt-Brown, 1996), as also observed in the present study. The fractures observed in the present study were predominantly simple transverse fractures. Similar findings have been reported by Helmer and Redig (2006), Guzman *et al.* (2007), Wright *et al.* (2018), and Pallavi *et al.* (2022).

In the present study, the use of stainless steel and titanium miniplate systems for the repair of tibiotarsus fractures and the subsequent fracture healing at different intervals in pigeons were evaluated. The technique of open reduction and internal fixation using bone plates was similar to that employed for tibial fracture repair in dogs. However, it was observed that the procedure required considerable patience and delicate handling of the bone because of the limited surgical exposure. Drilling of the bone had to be performed very carefully, as excessive force could

result in cracking, splintering, or refracture of the bone during the procedure. Kuzma and Hunter (1991) and Bennett and Kuzma (1992) reported that the thinner cortices of avian bones make them more susceptible to iatrogenic fractures.

With regard to the comparison between the stainless steel and titanium plate systems, no differences were observed in the surgical technique, ease of bone plate application, or duration of surgery between the two groups. In both groups, difficulties were encountered during screw insertion into the bone. The intraoperative complications observed during the initial stages of standardizing the technique were probably due to limited surgical experience and inadequate instrumentation. During the early phase of the study, drilling resulted in cracking, splintering, or breakage of the bone in three pigeons. Similar findings were reported by Gull *et al.* (2012) and Bennert *et al.* (2016), who suggested that fissures or breakage may

occur intraoperatively during manipulation with surgical instruments and implants because avian bones, owing to their unique structure, are more brittle than mammalian bones. Consequently, the thin avian cortical bone can be easily damaged during screw placement. In the present study, these birds were excluded and subsequently treated using a 1.2 mm K-wires along with nylon No. 2-0 for cerclage wiring.

Von Werthern and Bernasconi (2000) stated that bone thickness should be at least twice the thread pitch of the screw to create adequate compression. They suggested that the disproportion between thread pitch and cortical thickness might contribute to screw loosening. Langley-Hobbs *et al.* (2009) and Gull *et al.* (2012) stated that the absolute minimum requirement is two screws (four cortices) per main fragment, and that a third screw should be added if sufficient space is available. They also recommended that the screws should be at least equal to the measured depth or 2 mm longer than the measured length to ensure adequate engagement of the trans-cortex by the screw threads.

In all cases of the present study, two screws were placed through the bone plate on each side of the fracture fragment, and all screws were inserted bicortically. Gull *et al.* (2012) observed that, besides the high cost of bone plates, one of the major disadvantages of miniplate fixation was the technical difficulty associated with their application. In the present study, the primary challenge encountered in both groups was screw application due to the miniature size of the implants. Therefore, a specially designed screwdriver was required for screw placement. It was also important to avoid applying excessive force during screw insertion; instead, careful and patient rotational advancement of the screws was essential for successful fixation.

In the present study, postoperative limb necrosis was observed by day 5 during the initial stages of the study, which may have been due to excessive tissue trauma during surgery. However, after standardization of the surgical technique, no such complications were encountered. Therefore, delicate drilling of the bone with careful avoidance of damage to the tibial artery is strongly recommended. Mortality was observed in four birds during the postoperative period, which may have been associated with the preoperative and surgical stress or underlying infections.

Gouvea *et al.* (2011) opined that inadequate plate length and improper application of the plate to the bone surface may contribute to implant failure, such as plate bending. In group II, plate bending was observed in three birds by day 7 postoperatively. Similar findings were reported by Gull *et al.* (2012), who suggested that malpositioning of fracture fragments could lead to plate bending. Christen *et al.* (2005) used 1.0 maxillofacial miniplates for the treatment of ulna fractures in pigeons and observed that all the plates bent and twisted, failing to provide adequate strength.

They recommended the use of stronger and longer plates to reduce the risk of fatigue failure.

Weight-bearing was observed in all birds by day 10, and complete functional recovery was achieved by day 21. Birds in both groups exhibited excellent weight-bearing ability by the end of the study period. On clinical examination, weight-bearing was observed comparatively earlier in group I, which may have been due to the relatively greater rigidity of stainless steel compared to titanium miniplates. By the end of the study (postoperative day 60), all birds in both groups were bearing weight normally on the affected limb. Similar observations were reported by Gouvea *et al.* (2011), who advocated the use of titanium microplates for the treatment of tibiotarsus fractures in medium-sized pigeons and observed a healing time of 26-32 days. Pallavi *et al.* (2022) also reported a progressive decrease in lameness scores from day 7 onward, with excellent weight-bearing achieved by day 45.

Immediate postoperative radiographic evaluation confirmed adequate apposition and alignment of the fracture fragments, along with proper placement of the plate. In the present study, a significant increase in callus formation from day 15 to day 45 was observed in all birds of both groups, and primary union of the fracture fragments with minimal callus formation was observed by the 45th postoperative day. However, no significant difference in bone union was observed between the groups (Figs. 2A and 2B).

Kuzma and Hunter (1991) opined that bone plates provide rigid stability, which may result in reduced callus formation. Wan *et al.* (1994) and Venugopal *et al.* (2014) reported that healthy callus formation was noted from the third week onwards following internal fixation in pigeons and an Indian peafowl, respectively, using stainless steel implants and intramedullary pins. Muller and Nafeez (2007) have suggested that avian fractures heal rapidly within three weeks when the fracture site is properly reduced and aligned. Guzman *et al.* (2007) observed that, following three weeks post-surgery, proper implant positioning at the fracture site was associated with appropriate callus formation at six weeks, followed by callus remodeling in the tibiotarsal bone of a bald eagle.

Gouvea *et al.* (2011) used titanium microplates for the treatment of tibiotarsus fractures in 30 pigeons and observed a healing time of 26-32 days. They concluded that titanium microplates are a suitable option for osteosynthesis of the tibiotarsus in medium-sized birds. Pallavi *et al.* (2022) evaluated titanium and stainless-steel locking reconstruction bone plates in backyard poultry for tibiotarsus fracture repair and observed primary bone healing with minimal callus formation in all birds of both groups. They reported that both types of plates were effective for managing tibiotarsus fractures, with excellent weight-bearing achieved by day 45 in both groups, and no significant difference in lameness scores between the groups.

Radiographic evidence of bone healing often lags behind the clinical assessment of fracture stability and suggests that implants can frequently be safely removed before radiographic evidence of complete callus bridging at the fracture site, as observed by Bush *et al.* (1976). Guzman *et al.* (2007) opined that plate removal requires major surgery and entails additional rehabilitation. However, since bone plates are embedded beneath muscle layers, significant thermal conduction is unlikely.

In the present study, clinical and radiological observations were similar in both groups. It is concluded that bone plating can be used as an option for the treatment of tibiotarsus fractures in pigeons, following principles similar to those applied in mammals. However, the surgical procedure required specialized instrumentation and delicate handling of the bone. Both titanium and stainless-steel miniplates were found to be suitable for the repair of tibiotarsus fractures. However, as plate bending was more commonly observed with titanium plates, the use of stainless-steel plates of similar size is recommended.

References

- Bauck, L., Fowler, J.D. and Cribb, P. 1987. Tibial osteotomy in an emu. *Comp. Anim. Pract.* **1**: 26-30.
- Bennert, B.M., Kircher, P.R., Gutbrod, A., Riechert, J. and Hatt, J.M. 2016. Evaluation of two miniplate systems and figure-of-eight bandages for stabilization of experimentally induced ulnar and radial fractures in pigeons (*Columba livia*). *J. Avian Med. Surg.* **30**: 111-121.
- Bennett, R.A. and Kuzma, A.B. 1992. Fracture management in birds. *J. Zoo. Wild. Med.* **23**: 5-38.
- Bush, M., Hughes, J.L., Ensley, P. and James, A.E. 1976. Fracture repair in exotics using internal fixation. *J. Am. Anim. Hosp. Assoc.* **12**: 746-753.
- Christen, C., Fischer, I., von Rechenberg, B., Flückiger, M. and Hatt, J.M. 2005. Evaluation of a maxillofacial miniplate compact 1.0 for stabilization of the ulna in experimentally induced ulnar and radial fractures in pigeons (*Columba livia*). *J. Avian Med. Surg.* **19**: 185-190.
- Davidson, J.R., Mitchell, M.A. and Ramirez, S. 2005. Plate fixation of a coracoid fracture in a bald eagle (*Haliaeetus leucocephalus*). *J. Avian Med. Surg.* **19**: 303-308.
- Gouvea, A.S., Alievi, M.M., Noriega, V., Isis-dos, S.D., Pinto, T.M., De Menezes, C.L.M., Silva, R.B., Da-Silva, L.M., Velasque, A.G., Pinto, L.A.T. and Coelho, A.J.A. 2011. Titanium microplates for treatment of tibio-tarsus fractures in pigeons. *Cienc. Rural* **41**: 476-482
- Gull, J.M., Saveraid, T.C., Szabo, D. and Hatt, J.M. 2012. Evaluation of three miniplate systems for fracture stabilization in pigeons (*Columba livia*). *J. Avian Med. Surg.* **26**: 203-212.
- Guzman, D.S.M., Bubenik, L.J., Lauer, S.K., Vasanjee, S. and Mitchell, M.A. 2007. Repair of a coracoid luxation and a tibiotarsal fracture in a bald eagle (*Haliaeetus leucocephalus*). *J. Avian Med. Surg.* **21**: 188-195.
- Harcourt-Brown, N.H. 1996. Foot and leg problems. *In: BSAVA Manual of Raptors, Pigeons and Waterfowl*, Forbes, N.A. and Harcourt-Brown, N.H. (Eds). British Small Animal Association, Gloucestershire, UK. pp 147-168.
- Helmer, P and Redig, P.T. 2006. Orthopedic disorders. *Clin. Avian Med.* **2**: 761-774.
- Kuzma, A.B. and Hunter, B. 1998. Osteotomy and derotation of the humerus in a turkey vulture using intramedullary polymethylmethacrylate and bone plate fixation. *Can. Vet. J.* **30**: 900-901.
- Langley-Hobbs, S.J., Voss, K., Lapish, J.P. and Montavon, P.M. 2009. Orthopedic implants. *In: Feline Orthopedic Surgery and Musculoskeletal Disease*, Montavon, P.M., Voss, K., Langley-Hobbs, S.J. (Eds). Saunders Elsevier, London, UK. pp 259-282.
- Levitt, L. 1989. Avian orthopedics. *Compend. Contin. Educ. Pract. Vet.* **11**: 899-907.
- Miller, A. 1998. Principles of fracture surgery. *In: BSAVA Manual of Small Animal Fracture Repair and Management*, Coughlan, A.R. and Miller, A. (Eds). Quedgeley, Gloucestershire, UK. pp 65-94.
- Muller, M.G. and Nafeez, J.M. 2007. Use of the Fix Ex Tubulaire Type FESSA system for tibiotarsal fractures in falcons. *Falco* **29**: 25-28.
- Pallavi, Dilipkumar, D., Patil, M., Bhagavantappa, B. and Venkatgiri 2022. Tibiotarsus fracture repair by using titanium and stainless steel locking reconstruction bone plates in backyard poultry. *J. Exp. Zool. India.* **25**: 273-277.
- Venugopal, S.K., Anoop, S., Sarangom, S.B., Philip, S.B., Prakash, S., Joy, B. and Kankonkar, A.P. 2014. Repair and management of fractured wing in an Indian peafowl (*Pavo cristatus*). *Malaysian J. Vet. Res.* **5**: 15-19.
- Von Werthern, C.J. and Bernasconi, C.E. 2000. Application of the maxillofacial mini-plate compact 1.0 in the fracture repair of 12 cats/2 dogs. *Vet. Comp. Orthop. Traumatol.* **13**: 92-96.
- Wan, P.Y., Adair, H.S., Patton, C.S. and Faulk, D.L. 1994. Comparison of bone healing using polydioxanone and stainless-steel intramedullary pins in transverse, mi humeral osteotomies in pigeons (*Columba livia*). *J. Zoo Wildlife. Med.* **25**: 264-269.
- Wright, L., Mans, C., Olsen, G., Doss, G., Amene, E.W., Britsch, G., Christman, J. and Heatley, J. 2018. Retrospective evaluation of tibiotarsal fractures treated with tape splints in birds: 86 cases (2006-2015). *J. Avian Med. Surg.* **32**: 205-209.