

An experimental model to create third degree burn wound in rabbits

Pipelu Wahengbam^{1*}, I. Karuna³, Rekha Pathak², M. Karikalan⁴ and Gaurav Biswas⁵

ICAR-Indian Veterinary Research Institute, Izatnagar- 243 122 (Uttar Pradesh)

¹PhD Scholar, ²Principal Scientist, Division of Surgery; ³Scientist, Division of Biochemistry; ⁴Scientist, Division of Pathology; ⁵PhD Scholar, Division of Animal Nutrition, Indian Veterinary Research Institute, Izatnagar

DOI No.: 10.5958/0973-9726.2026.00018.3

Accepted: Oct. 2025

The present study aimed to determine better method of heating of a burn wound creating apparatus, between direct heating and heating in boiling water, for creating experimental burn wounds. The temperature and contact time were constant for creating third-degree burns in rabbits. New Zealand White rabbits were used as the experimental model. A 500 g brass apparatus with a diameter of 3.5 cm was employed to induce burn injury. Burn depth was evaluated histologically. Third-degree burns were successfully produced in rabbits using the moist heating method. The study demonstrated that third-degree burn wounds can be experimentally created using moist heating.

Keywords: Burn wound model, Experimental study, Rabbit

Various methods have been proposed to create thermal burn wounds of skin including hot surfaces, liquids, steam, flames, or metal hot plates (Bairy *et al.*, 1997; Aksoy *et al.*, 2009). The induction of third-degree burns requires specialized apparatus to deliver and maintain a consistent amount of heat, which can be challenging. Additionally, the use of heated metal may result in variation in the depth of injury due to differences in the pressure applied at the site. To overcome these limitations, a more reliable method that allows easy application and produces uniform, reproducible wound injuries is needed. Therefore, the present study compared two methods of inflicting thermal injury in rabbits to create third-degree wounds.

The study protocol was approved by the Institutional Animal Ethics Committee. Four healthy New Zealand White rabbits of either sex, weighing 2-3 kg, were used in the present study. The animals were procured from the LAR section of IVRI, housed in individual iron cages, and acclimatized to the environment for 7 days prior to the creation of burn wounds. The animals were provided with standard pellet feed and *ad libitum* access to clean water.

The animals were anaesthetized by intramuscular injection of xylazine (6 mg/kg body weight) and ketamine (60 mg/kg) in the thigh muscles (Amarpal *et al.*, 2010). The hair on the dorsum of the rabbits was shaved, and the burn wounding procedure was carried out under general anaesthesia. A custom-made circular brass apparatus, 3.5 cm in diameter and weighing 500 g, was used to inflict the burn wounds

(Fig. 1). Brass was selected due to its superior thermal conductivity compared to other materials. The following methods were used for the creation of burn wounds:

Method 1: The custom insulated brass apparatus was heated directly over a gas flame for 15 min and then pressed firmly against the shaved back. The area was exposed for 60 seconds. No additional pressure was applied manually, other than the device's own weight.

Method 2: The custom insulated brass apparatus was heated in boiling water (100°C) for 15 min and then pressed firmly against the shaved back for 60 seconds. No external pressure was applied, other than the device's own weight.

The burn area was covered with sterile gauze and kept clean. After 12 hr, skin biopsy samples were collected and preserved in 10% neutral buffered formalin solution. The tissues were processed and stained using routine hematoxylin and eosin (H&E) staining. The presence of third-degree burn wounds was confirmed histologically. Following biopsy collection, the animals were housed in individual cages and were administered the anti-inflammatory drug meloxicam (0.6 mg/kg) and the antibiotic enrofloxacin (5 mg/kg) for 5 days. Wound dressing was performed using 1% silver sulfadiazine cream, followed by the application of a cotton gauze bandage over the wound.

The heated brass apparatus produced circular burn wounds on the dorsum of the rabbits using both methods (Fig. 2). The total burn area produced was 962 mm². The burns led to alterations in skin integrity, ranging from superficial damage to more severe injury involving multiple layers of the skin. Following burn infliction, the skin in method 2 exhibited whitish discoloration, whereas in method 1 the skin surface remained dry with dark brown discoloration, indicative of coagulated tissue. The burn wounds produced by method 2 were more organized and soft to the touch, likely due to oedema at the site, whereas a hard crust developed in burns induced by method 1.

The histopathological findings in method 2 showed pronounced tissue oedema, with large empty spaces formed due to collagen degeneration, coagulative necrosis, and extensive loss of the epidermis (Fig. 3). There was marked dermal disorganization involving the full thickness of the skin, along with destruction of

*Corresponding author; E-mail: pipeluwahengbam@gmail.com

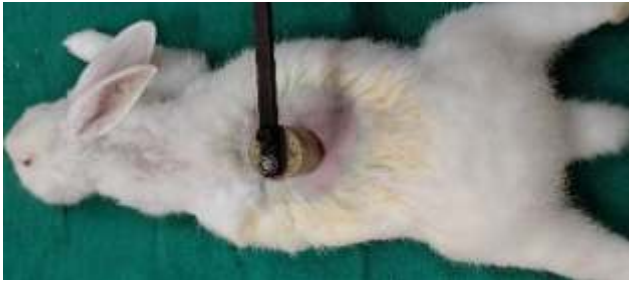

Fig. 1: Infliction of burn wound on the dorsum of the rabbit using a circular brass apparatus.

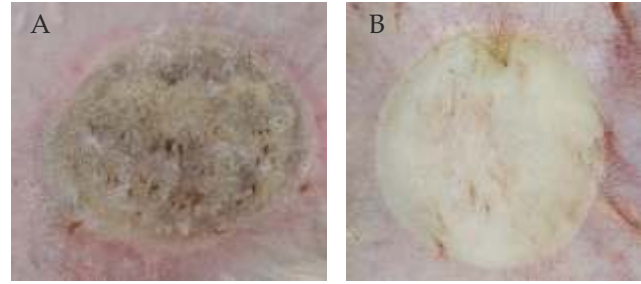


Fig. 2: Infliction of burn wound on the dorsum of the rabbit using a circular brass apparatus: A-dry heat, B-moist heat.

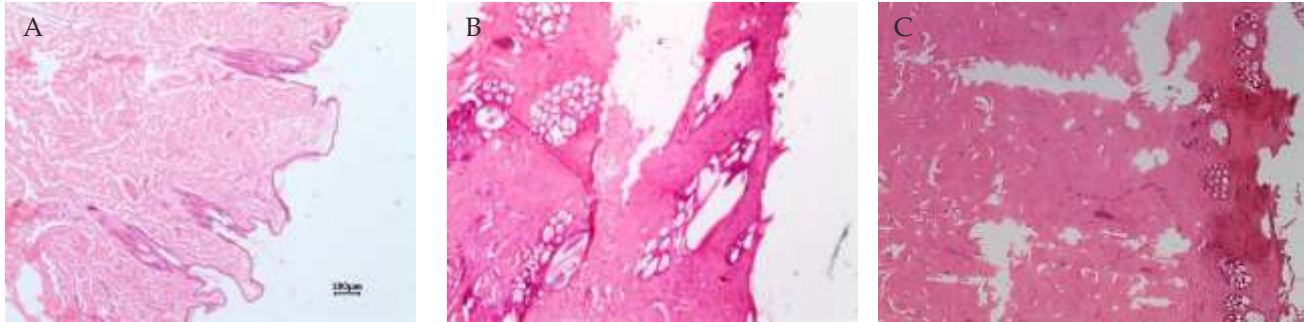


Fig. 3: Photomicrograph of normal skin (A), burn wound by Dry Heat (B), and burn wound by moist heat (C); H&E staining; scale -100 μ m (4X). Loss of normal architecture with homogenization of the collagen bundles (arrow epidermis, + dermis, * empty space).

skin appendages. The collagen fibers were difficult to distinguish individually due to hyaline-like degeneration. Complete destruction of the papillary layer of the skin, along with muscular damage, was observed (Fig. 3C). Furthermore, third-degree burns were confirmed, as all layers of the skin and underlying tissues were affected in wounds inflicted by method 2.

In method 1, there was complete damage to the epidermal layer, and the papillary layer of the skin was disrupted; however, some structures were still preserved. Fewer empty spaces were observed compared to method 2. Collagen fibres appeared in bundles only in the superficial region, while more organized fibers were present in the deeper layers. No muscular damage was observed. Third-degree burns were not achieved using this method of burn induction.

This apparatus produced reproducible third-degree burn wounds, which were confirmed histopathologically. In contrast, Sobec *et al.* (2014) reported second-degree burns in five male New Zealand White rabbits using a 350 g copper device with a contact time of 4 seconds at 43°C. Similarly, Aksoy *et al.* (2009) produced third-degree full-thickness burn wounds using a 500 g brass device heated in boiling water for 15 min and applied for 45 seconds.

The application of moist heat likely resulted in excessive heat transfer, leading to extensive protein denaturation, degradation, and coagulation, ultimately causing tissue necrosis (Rowan *et al.*, 2015). The surrounding tissue exhibited swelling, likely due to increased vascular permeability and fluid retention.

In contrast, burn wounds created using method 1 (direct flame heating) appeared dry and showed shrinkage of the affected area, possibly due to rapid and intense heat transfer. This method may have caused damage primarily to the superficial layers, including sweat and oil glands, without sufficient penetration into the deeper dermal layers.

In conclusion, third-degree burn wounds can be experimentally and reproducibly created in rabbits using moist heating of a custom-designed brass apparatus. This method produces more uniform and well-organized burn wounds.

References

- Aksoy, B., Aksoy, H.M., Civaş, E., Üstün, H. and Atakan, N. 2009. A new experimental delayed wound healing model in rabbits. *Eur. J. Dermatol.* **19**:565-569.
- Amarpal, Kinjavdekar, P., Aithal, H.P., Pawde, A., Singh, J. and Udehiya, R. 2010. Evaluation of xylazine, acepromazine and medetomidine with ketamine for general anaesthesia in rabbits. *Scand. J. Lab. Anim. Sci.* **37**:223-229.
- Bairy, K.L., Somayaji, S.N. and Rao, C.M. 1997. An experimental model to produce partial thickness burn wound. *Indian J. Exp. Biol.* **35**:70-72.
- Sobec, R.L., Dobreanu, C.N., Magdas, C.N., Nagy, A., Dinte, E., Fodor, M.M., Somcutean, A., Tichil, I., Nastai, M. and Fodor, L. 2014. Improved experimental burn model on rabbits. *Med-Surg J.* **118**:1047-1053.