

## Surgical management of congenital umbilical hernia in a Persian kitten

A.R. Ninu<sup>1\*</sup> and N. Krishnaveni<sup>2</sup>

Tamil Nadu Veterinary and Animal Sciences University, Chennai- 600 051 (Tamil Nadu)

<sup>1</sup>Assistant Professor and Head, <sup>2</sup>Assistant Professor, Department of Veterinary Surgery and Radiology, Veterinary College and Research Institute, Tirunelveli – 627 358

DOI No.: 10.5958/0973-9726.2026.00025.2

Accepted: Dec. 2025

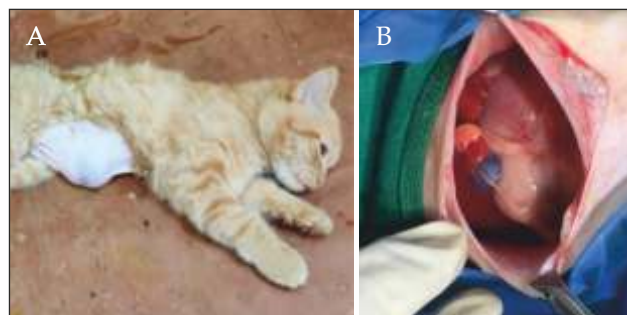
The occurrence of umbilical hernia in kittens is comparatively less common than in other domestic animals. Surgical correction remains the treatment of choice and is performed either by herniorrhaphy or hernioplasty, depending on the size of the hernial ring.

A six-month-old male Persian kitten weighing 1 kg was presented with a history of ventral abdominal swelling present since birth (Fig. 1A). The kitten exhibited normal appetite and voiding habits. Haematological parameters were within normal limits. Clinical examination revealed reducible hernial contents along with a palpable hernial ring. Radiographic examination showed soft tissue opacity in the region of abdominal distension. Ultrasonographic evaluation of the swelling identified rugal folds of the stomach with hyperechoic ingesta, a hypoechoic fine-textured spleen, and a hypoechoic coarse-textured liver within the hernial sac.

Under premedication with xylazine (1 mg/kg body weight, i.m.), anaesthesia was induced using a combination of diazepam (0.25 mg/kg) and ketamine (10 mg/kg) administered intravenously, and maintained with isoflurane (1-2%). The kitten was positioned in dorsal recumbency. Following aseptic preparation of the surgical site, a skin incision was made over the swelling. Intraoperative examination revealed the spleen and liver lobes as the hernial contents (Fig. 1B). The hernial ring measured approximately 9 cm in diameter, with no evidence of adhesions.

The edges of the hernial ring were debrided, and herniorrhaphy was performed using 2-0 polyamide in an overlapping pattern. Hernioplasty was not required, as adequate apposition of the musculature was achieved without tension. The repair was further reinforced using chromic catgut No. 3-0 in a simple interrupted pattern. Skin closure was performed using 2-0 polyamide in a cross mattress pattern.

Postoperative management included ceftriaxone (20 mg/kg body weight, i.m., twice daily for five days) and meloxicam (0.2 mg/kg, s.c., single dose followed by 0.05 mg/kg body weight orally once daily for two days). Skin sutures were removed on the 10th postoperative day. The kitten recovered uneventfully without any postoperative complications.



**Fig. 1:** (A) The kitten with swelling in the umbilical region; (B) The hernia contents: stomach, spleen and liver.

Congenital umbilical hernia is infrequently reported in cats. Ultrasonographic findings such as a hypoechoic fine-textured spleen and hypoechoic coarse-textured liver are considered characteristic in feline patients (Gomaa *et al.*, 2013). The timing of surgical correction generally depends on the size of the hernial ring and the nature of the herniated contents (Pratschke, 2014). In the present case, surgery was undertaken without delay because of the large hernial ring. Although the optimal age for umbilical hernia repair in kittens has not been clearly established in the literature, successful correction was achieved at six months of age without the need for hernioplasty.

### Acknowledgement

The authors are grateful to the Dean, Veterinary College and Research Institute, Tirunelveli, and Director of Clinics, TANUVAS, and the Professor and Head, VCC, VCRI, Tirunelveli, for their valuable assistance and support.

### References

- Gomaa, M., Samy, M.T., Omar, M.S., Mekki, N.H. and Kramer, M. 2013. Ultrasonographic investigation of the abdominal cavity including lymph nodes surgical affections in dogs and cats. *Egypt. J. Basic Appl. Physiol.* **12**: 177-201.
- Pratschke, K.M. 2014. Abdominal wall hernias and ruptures. *In: Feline Soft Tissue and General Surgery*, Langley-Hobbs, S.J., Demetriou, J.L. and Ladlow, J.F. (Eds). Saunders Elsevier, Edinburg. pp 269-280.

\*Corresponding author; E-mail: ar.ninu@gmail.com