

Goitre in a Goat Kid: A Case Study

Jagvir Singh^{1*} and Aabha Kaushal²

Department of Veterinary Medicine CSKHPKV Palampur

(Received : November, 2023 227/23 Accepted : February, 2024)

Abstract

This case report documents a one-month-old goat kid with goitre, presented with visible neck swelling, weakness, and a coarse hair coat. Diagnostic ultrasound revealed an enlarged, heterogenous, and hypoechogenic thyroid gland. Treatment involved oral levothyroxine sodium to kid, tincture iodine application and dietary iodized salt for doe. The successful outcome highlights the importance of prompt identification and intervention in cases of goitre, particularly in regions prone to iodine deficiency, emphasizing the need for preventive measures to ensure overall goat health.

Key words – Goitre, Goat, Ultrasound of thyroid

The thyroid is an essential endocrine gland that controls metabolism (Barrea *et al.*, 2021). Almost every cell in the body depends on the thyroid hormones thyroxine (T4) and triiodothyronine (T3) for growth, metabolism, and function (Bhardwaj, 2018). Goitre, is a non-inflammatory, non-neoplastic growth of the thyroid gland, can develop in any domestic bird, mammal, or other sub mammalian vertebrate (Hassan *et al.*, 2013). Goitre, a condition characterized by the abnormal enlargement of the thyroid gland, is a concern that can affect goat kids. This condition often manifests as a visible swelling in the neck area, indicative of an underlying thyroid dysfunction. Goitre in goat kids is particularly noteworthy due to its potential impact on overall health and growth. The thyroid gland plays a crucial role in regulat-

ing metabolism and hormonal balance, and any abnormalities in its function can have profound consequences on the goat's well-being. While goitre can be attributed to various factors, such as iodine deficiency or genetic predisposition, prompt identification and intervention are essential for effective management. The present case report aim to represent an unusual case of highly enlarged thyroid gland in a goat kid.

Case History and Observations

A one-month-old kid was presented with a history of bilateral swelling on cranioventral aspect of neck region. According to the owner, the size of the swelling increased with each day. The kid displayed signs of weakness, dullness, and a coarse hair coat, accompanied by noticeable hair loss (alopecia). During physical examination, there was no pain on the swelling. Rectal temperature, respiratory rate and heart rate were within normal range. The size of thyroid gland found to be 6.4 x 4.5 x 1.8 cm (Length x width x height).

The ultrasound examination was performed and revealed enlarged, heterogenous and hypoechogenic thyroid gland suggestive of goitre.

Treatment and Discussion

Levothyroxine sodium was given orally to the kid at a dose rate of 0.2 mg per kg body weight daily for the first month of treatment. The owner was also instructed to paint the goat's teats once a day for two weeks with an iodine tincture and to include iodized salt in the diet. The treatment continued for two months, there was a visible decrease in the size of the glands, and kid started to eat normal feed. Iodine deficiency is endemic

*Corresponding author: Email : jagvir.619@gmail.com

¹Ph.D. scholar, Department of Veterinary Medicine CSKHPKV Palampur

²Veterinary Surgeon, Veterinary Polyclinic, Bilaspur H.P.

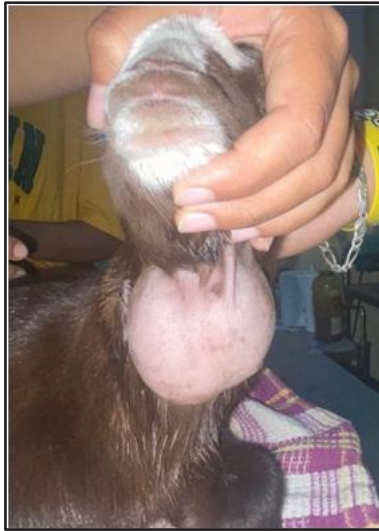


Fig.1 Clinical aspect of goitre

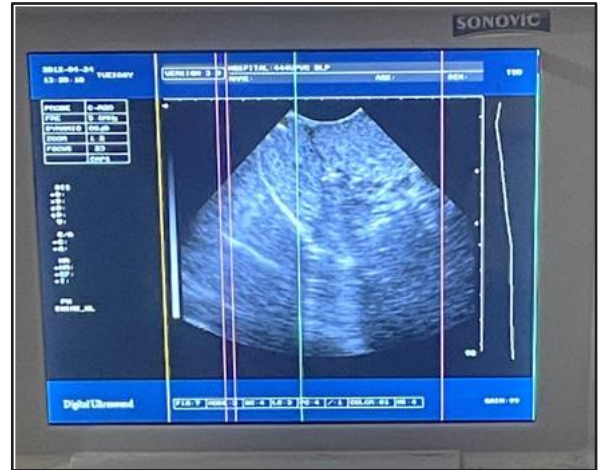

Fig. 2 Hypoechogenicity of thyroid gland (arrows)

in mountainous and sub-mountainous regions of India iodine deficiency during pregnancy may be the cause in this instance and has particularly harmful effects like retardation of foetal development, retarded growth and birth of weak or dead newborns with goitre (Vijlder, 2003). Since the body is unable to synthesise iodine, the main source of iodine the diet (Kotwal *et al.*, 2007). The severity of a diet-related iodine deficiency may have contributed to this case's outcome. The focus was on improving the kid's condition and preventing further loss in subsequent gestations by giving the goat extra iodine supplements.

Summary

Levothyroxine Sodium and Iodine supplementation proved to be efficient for treating a case of congenital goitre in a kid. While reviewing, deficit literature was found on the etiology, prevalence and prophylaxis of congenital goitre, therefore, more studies need to be undertaken on aforementioned factors.

References

- Barrea, L., Gallo, M., Ruggeri, R. M., Giacinto, P. D., Sesti, F., Prinzi, N., Adinolfi, V., Barucca, V., Renzelli, V., and Muscogiuri, G. (2021). Nutritional status and follicular-derived thyroid cancer: An update. *Crit Rev Food Sci Nutr*, **61**(1) : 25–59.
- Bhardwaj, R.K. (2018). Iodine deficiency in goats. *Goat Science Intech*, 727-28.
- Hassan, N., Randhawa, C., and Hussian, S. (2013). Treatment of congenital bilateral goitre in a kid-a case report. *Indian J Sci Tech*, **1**(3) : 19–20
- Kotwal A, Priya R and Qadeer I (2007). Goiter and other iodine deficiency disorders: a systematic review of epidemiological studies to deconstruct the complex web. *Arch. Med. Res.*, **38** :1-14.
- Vijlder D (2003). Primary congenital hypothyroidism: defect in iodine pathways. *Eur. J. Endocrinol.*, **149**(4): 247-256.