

Concurrent Infection of Anaplasmosis and Babesiosis in a Cow - A Case Report

Indu Yadav¹, M. K. Vijayasarithi^{1*} and S. Anandu¹

Division of Parasitology, Indian Veterinary Research Institute, Izzatnagar, Uttar Pradesh – 243 122

(Received : January, 2024 15/24 Accepted : March, 2024)

Abstract

A two calved cross-bred Jersey cow (5 years) was presented at Referral Veterinary Clinical Complex, Indian Veterinary Research Institute, Izzatnagar during the month of August 2023 with history of high fever, coffee coloured urination, anorexia, and low milk yield. Clinical examination revealed pyrexia (105.8), haemoglobinuria, enlarged prescapular lymph node, pale vaginal and conjunctival mucous membranes, and presence of ticks over the body. Blood smear was screened for parasitological examination using Giemsa's stain which showed positive for *Babesia bigemina* and *Anaplasma marginale* mixed haemoprotozoan infection. The cow was treated with diminazine aceturate @ 3.5 mg/kg I/M and oxytetracycline @ 20mg/kg body weight, along with supportive therapy against babesiosis and anaplasmosis respectively showed progressive recovery after 5 days of treatment. Incidence of concurrent infection of Babesiosis and Anaplasmosis was documented in bovine from Bareilly district of Uttar Pradesh.

Key words: *Anaplasma marginale*, *Babesia bigemina*, Cow, India, Mixed haemoprotozoan infection

Haemoprotozoan infections in cattle, particularly tick-borne parasites like *Babesia* spp, *Theileria* spp and *Anaplasma* spp cause significant losses in the livestock industry (Shahnawaz, *et al.* 2011). The most important tick-borne haemoparasites in bovines in India are *Babesia* spp, *Theileria* spp, and *Anaplasma* spp (Zahid *et al.* 2005). In bovines, symptoms

include pyrexia, anemia, emaciation, reduced productivity, and reproductive issues. Global economic losses from tick-borne diseases amount to US\$18.7 billion annually, with India contributing US\$498.7 million (Ghosh and Nagar, 2014). Tropical Theileriosis alone incurs US\$800 million in annual losses (Devendra, 1995), while Babesiosis and Anaplasmosis result in approximately US\$57 million in India (Anwar, 2018). Babesiosis, caused by *B. bigemina* and *B. bovis*, transmitted by Ixodid ticks, leads to substantial morbidity and mortality globally (OIE, 2005).

Anaplasmosis, caused by *A. marginale*, primarily transmitted by *Rhipicephalus microplus*, is marked by haemolytic anaemia, fever, jaundice, reduced milk production, abortions, and, at times, sudden death. The disease, named “gall sickness” by Sir Arnold Theiler in 1910, poses a threat to cattle health and the dairy sector (Theiler, 1910, Kocan *et al.* 2010).

This article was described about the diagnosis of mixed haemoprotozoan infection in bovine by conventional method and control measures to be adopted to minimize the economic losses.

Materials and Methods

A two calved cross-bred Jersey cow (5 years) was presented at Referral Veterinary Clinical Complex, Indian Veterinary Research Institute, Izzatnagar during the month of August 2023 with history of high fever, hemoglobinuria, anorexia, and low milk yield. Clinical examination revealed pyrexia (105.8), enlarged prescapular lymph node, pale vaginal and conjunctival mucous membranes, and presence of ticks over

*Corresponding author : Email : sarathivet@gmail.com

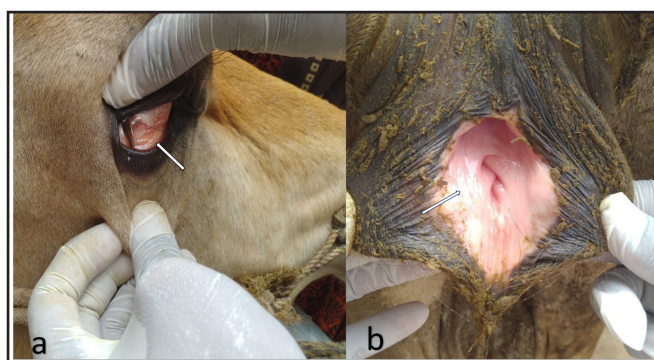


Fig. 1 (a) : Pale conjunctival mucous membranes **(b)**: Pale-vaginal mucous membranes (white arrow)

the body (Fig.1). The smear was fixed with methanol, stained using the standard Giemsa's staining method, and screened under oil immersion of a compound binocular light microscope.

Results and Discussion

Examination of the blood smear using a binocular compound light microscope for blood parasites showed the presence of numerous large pear-shaped, paired organisms positioned centrally at an acute angle within erythrocytes. Additionally, small round to spherical organisms were observed at the periphery of the erythrocytes (Fig. 2). The identification of these organisms as *Babesia bigemina* and *Anaplasma marginale* was based on their morphological features, as described by Soulsby (1982).

Mohanapriya *et al.* (2017) reported a simultaneous infection of *Babesia bigemina* and *Anaplasma marginale* in a 5-year-old Jersey cow in Tirunelveli, Tamil Nadu. They have also followed the diminazine aceturate @ 3.5 mg/kg I/M and oxytetracycline @ 20mg/kg body weight, along with supportive therapy against babesiosis and anaplasmosis respectively, as treatment protocol in a cow. Similarly, Jayalakshmi *et al.* (2019) were also recorded an increased incidence of concurrent infections involving Anaplasmosis, Babesiosis, and Theileriosis, possibly attributed to the engagement of the vector (tick) *Rhipicephalus* spp. in transmitting haemoprotozoan diseases given its prevalence as the most common tick species in cattle in the Cauvery delta region. The hot and humid climate, conducive to the growth, multiplication,

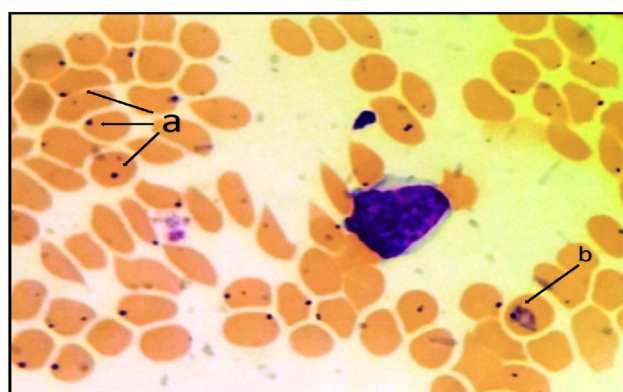


Fig.2 (a): Small round to spherical shaped piroplasms located at the periphery of RBC-*Anaplasma marginale*(1000X) **(b)** Pear shaped piroplasm fused at an acute angle inside the RBC – *Babesia bigemina* (1000X)

and survival of arthropods, plays a pivotal role as a vector for various blood-borne protozoan diseases (Krishnamurthy *et al.* 2016). Velusamy *et al.* (2014) demonstrated a notably higher prevalence of haemoprotozoan diseases in Holstein Friesian (HF) and Jersey cross breeds compared to indigenous breeds. Their study further elucidated that the occurrence of these haemoprotozoan diseases was more pronounced among animals aged 2-7 years in crossbreeds and below 2 years in indigenous animals, with no significant seasonal influence on the prevalence of babesiosis and anaplasmosis. Chandran *et al.* (2019) documented the effectiveness of treating four cows with diminazine aceturate at a dosage of 2.5 mg/kg body weight and oxytetracycline @ 20mg/kg body weight, along with supportive therapy against babesiosis and anaplasmosis respectively. Unfortunately, a cow presented at a delayed stage with severe anemia and a delay in the initiation of therapy resulted in death. Therefore, it is crucial to ensure the early diagnosis and prompt treatment of haemoprotozoan diseases for the protection of livestock. Due to the fact that anaplasmosis and babesiosis are vector-borne diseases, it is imperative to control ticks. These ticks have developed resistance to various chemical acaricides, necessitating the adoption of alternative control strategies. One such approach involves the use of semiochemicals in combination with acaricides to attract and effectively eliminate ticks (Latha, 2012).

Conclusion

Prevalence of vectors such as ticks, flies, and mosquitoes are on the rise due to changing patterns in rainfall and temperature. Consequently, incidences of vector-borne diseases in animals are also increasing, resulting in significant economic losses for the country. To avert vector-borne parasitic diseases in animals, it becomes imperative to adhere to recent strategies for infection control, including vaccination against ticks. Furthermore, the adoption of early disease diagnostic techniques is crucial for treating these ailments at an acute stage, thereby preventing further losses.

Acknowledgement

We acknowledged the Head, Division of Parasitology, IVRI, Izatnagar and the Director, IVRI, Izatnagar for all the facilities for disease diagnosis.

Conflict of Interest: None

References

- Chandran, D., Padmaja, P.B and Vishnurahav, R.B (2019). Haemato-biochemical changes and therapeutic management of Babesiosis in cattle. *J. Vet. Anim. Sci.* 2019 **50** (1): 68 - 70
- Devendra, C (1995). In Global Agenda for Livestock Research. EDS, ILRI, Nairobi, pp 41–48.
- Ghosh, S and Nagar, G (2014). Problem of ticks and tick-borne diseases in India with special emphasis on progress in tick control research: a review. *J. Vector. Borne. Dis* **5**(1), 259–270.
- Jayalakshmi, K., Sasikala, M., Veeraselvam, M., Venkatesan, M., Yogeshpriya, S., Ramkumar, P.K., Selvaraj, P and Vijayasarithi, M.K (2019). Prevalence of haemoprotozoan diseases in cattle of Cauvery delta region of Tamil Nadu. *J. Parasit. Dis* **43**, 308-312.
- Kocan, K. M., de la Fuente, J., Blouin, E. F., Coetzee, J. F and Ewing, S. A (2010). The natural history of *Anaplasma marginale*. *Vet. Parasitol* **167**(2–4), 95–107.
- Latha, B.R (2012). Semiochemical - A novel thought for tick control. *J. Vet. Anim. Sci* **43**, pp.1-10.
- Mohanapriya, T., Pazhanivel, N., Enbavelan, P.A and Kumar, V (2017). Concurrent *Babesia bigemina* and *Anaplasma marginale* infection in a Jersey cow. *Indian J. Vet. Sci. Biotechnol* **12**(3), 143-145.
- OIE (2005). Manual of Standard Tests and Vaccines, Office International des Epizooties, World Organization for Animal Health, Chap. 2.3.8. (www.oie.int)
- Richey, E. J and Palmer, G. H (1990). Bovine anaplasmosis. *Compendium on Continuing Education for the Practising Veterinarian* **12**, 1661–1668.
- Shahnawaz, S., Ali, M., Aslam, M.A., Fatima, R., Chaudhry, Z.I., Hassan, M.U., Ali, M and Iqbal, F (2011). A study on the prevalence of a tick-transmitted pathogen, *Theileria annulata*, the hematological profile of cattle from Southern Punjab (Pakistan). *Parasitol. Res* **109**, 1155–1160.
- Soulsby, E.J.L (1982). Helminths, Arthropods and Protozoa of Domesticated Animals. Bailliere-Tindall, London, UK, 7th Ed.
- Theiler, A (1910). Gall-sickness of South Africa (anaplasmosis of cattle). *J. Comp. Pathol. Ther* **23**, 98–115.
- Zahid, I. A., Latif, M and Baloch, K. B (2005). Incidence and treatment of theileriasis and babesiasis. *Pak. Vet. J* **25**, 137–140.