

Therapeutic Efficacy of Antibiotics in Chronic Canine Otitis Externa

Nainika¹, Pardeep Sharma^{1*}, Rajendra D Patil², Prasenjit Dhar³ and Amit Kumar⁴

Dr. GC Negi College of Veterinary and Animal Sciences, CSK Himachal Pradesh Krishi Vishwavidyalaya Palampur, Himachal Pradesh-176062, India

(Received : January, 2024 22/24 Accepted : March, 2024)

Abstract

Canine otitis externa is inflammation of external ear canal, causing discomfort to the patients. In presented study dogs displaying symptoms of otitis externa for a duration exceeding two months were studied. Twenty-three dogs were included based on the duration of illness. Cytological and microbiological investigations were conducted in all the cases. Animals were categorized into two groups for treatment. Group I (n=11) was given oral Marbofloxacin, while Group II (n=12) received Cefpodoxime. The therapeutic efficacy was assessed on days 7th and 14th post-treatment. Notably, Group I demonstrated rapid and effective recovery within 14 days compared to Group II.

Key words: cefpodoxime, chronic otitis externa, marbofloxacin

Otitis externa is the inflammation of the external ear canal, extending from the auricle to the tympanic membrane. Diagnosing it accurately can be challenging due to its various causes, potentially leading to it not being recognized properly and turning into a long-lasting condition. Precisely identifying the root cause necessitates accurate physical inquiry and laboratory evaluation of aural secretions. The cytological examination offers insights into microorganism types and concentrations, while microbiological study aids in pinpointing the pathogen involved (Shaw, 2016).

Bourélyet *et al.* (2019) documented that *Staphylococcus aureus*, *Pseudomonas aeruginosa*, *Proteus* spp., and *Candida* spp. are the prevalent microorganisms encountered in severe and prolonged instances of canine external otitis. However, in cases specifically involving *Pseudomonas* infections, effective outcomes have been demonstrated with fluoroquinolones, gentamicin, and polymyxin B (Paterson *et al.*, 2018; Morris *et al.*, 2004). Jerzsele and Pasztine-Gere (2015) demonstrated the efficacy of a Marbofloxacin and Gentamicin combination in managing these challenging chronic and re-occurring infections.

There is a limited understanding of specific etiological factors contributing to the chronicity of canine otitis externa, hindering targeted and effective treatment strategies. Additionally, there is a need for more comprehensive research on the long-term outcomes and recurrence patterns to enhance the management of this condition.

Materials and Methods

In the study, 23 canine patients with chronic otitis externa at the Department of Veterinary Medicine, DGCN COVAS, Palampur, were studied from June 2022 to July 2023. Clinical manifestations were recorded in affected cases. Diagnostic procedures included ear swab cytology and culture with sensitivity testing. Cytology involved collecting ear exudate, staining with Himedia Giemsa stain, and examining under oil immersion lens. A semiquantitative analysis of cytological smears was done by counting average number of organisms per field (OPF) as proposed by Ginel *et al.* (2002). Culture

*Corresponding author : Email : docpradeepsharma@gmail.com

¹Department of Veterinary Medicine

²Department of Veterinary Pathology

³Department of Veterinary Microbiology

⁴Department of Veterinary Surgery & Radiology

and sensitivity were conducted by culturing ear discharge on Brain-Heart Infusion Agar and testing antibiotic susceptibility on Muller Hinton Agar. Detailed records were maintained for cytological, microbiological, and treatment outcomes in all cases.

Results and Discussions

The most common clinical signs observed were yellow-colored discharge (100%) from the ear, itching (100%), head shaking (78.26%), unpleasant odor (60.86%), pain on ear palpation (56.52%), and erythematous ear flap(82.60%). Additionally, there was head tilt (30.43%), swollen ear pinnae (52.17%), and increased skin pigmentation(8.69%). Haemorrhages (16.98%) in the ear canal were also observed in some cases.

Cytological analysis revealed rod-shaped bacteria in all cases. Combined infections occurred in 34.78% of cases out of which 13.04% had both rods and yeast, while 21.73% had rods and cocci. Similar findings were reported by Leonard *et al.* (2022) and Lorek *et al.* (2020) in chronic ear studies. Zur *et al.*(2011) noted that rod-shaped bacterial infections are more severe than cocci or yeast infections, aligning with our study.

Microbiological examination revealed a higher occurrence of *Pseudomonas* spp. (52.17%), followed by *Klebsiella* spp. (26.00%), *Proteus* spp. (17.39%), and *E. coli* (4.34%). Additionally, mixed infections included *Malassezia* spp. in three cases and *Staphylococcus* spp. in five cases. Similarly, Leonard et al. *loc cit.* noted an increased presence of *Pseudomonas* spp. in chronic otitis externa cases. The antibiotic analysis revealed varying levels of effective-

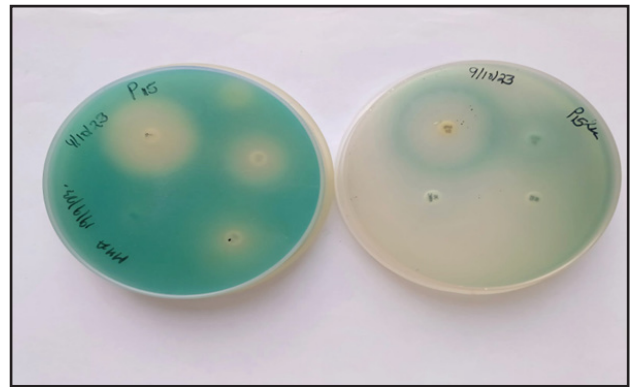


Fig 1. Different zone of inhibition in Antibioqram Testing

ness. Marbofloxacin demonstrated the highest susceptibility at 85.71%, followed by Gentamicin (80.95%), Cefpodoxime(76.19%), Enrofloxacin (76.19%), Ofloxacin (61.90%), Clindamycin (57.14%), Cephalexin and Neomycin (52.38%), Amikacin and Cefixime (38.09%), Amoxiclav (28.57%), and Amoxicillin (14.28%). Different zones of inhibition are shown in Fig 1 given below. These results align with Martin Barrasa *et al.* (2000), emphasizing the effectiveness of fluoroquinolones, particularly Marbofloxacin. In contrast, Bugden (2013) ranked Gentamicin as most sensitive, followed by Enrofloxacin.

Oral and topical antibiotics were selected based on culture and sensitivity testing, with animals divided into two groups according to the treatment outlined in Table I. Gentamycin was administered briefly to reduce potential aminoglycoside side effects, while prolonged use of ofloxacin necessary to ensure complete eradication of the bacterial infection. Also, in both the group’s ear cleaning was done with Chlorhexidine Gluconate (0.15%), Propylene Glycol (10%), TRIS EDTA once daily for 7 days followed by

Table I. Therapeutic Protocol for Chronic Otitis Externa

	Group I(n=11)	Group II(n=12)
Antibiotic	Marbofloxacin @ 5 mg/ Kg B. wt. od for 14 days	Cefpodoxime @ 10 mg/ Kg B. wt. od for 14 days
Ear drops	Gentamicinsulphate, Miconazole nitrate, Hydrocortisone aceponate 1ml in the affected ear once daily for 5 days	Ofloxacin (0.3%), Clotrimazole (1.0%), Betamethasone Dipropionate (0.025%), Lignocaine HCl (2.0%) 0.5-1ml in the affected ear once daily for 7-14 days

Table II. Cytological examination post-treatment

	Day 0	Day 7	Day 14
Group I (n=11)	39.63±2.45 ^a	1.45±0.62 ^{bc}	0 ^c
Group II (n=12)	37.33±3.09 ^a	7.00±0.92 ^{bc}	1.41±0.60 ^c

Different superscripts represent significant difference in a row

once every 15 days and prednisolone @1mg/Kg B. wt. at tapering dose for 14-21 days was given to reduce inflammation. Following the therapeutic intervention, the animals underwent re-evaluation through cytological examination. Data on the cytological investigation pre and post-treatment are presented in Table II given below and cytological analysis post-treatment is presented in Fig 2.

By Day 7, the cytological bacterial count of Group I decreased to 1.45±0.62 OPF, and Group II to 7.00±0.92 OPF. On Day 14, Group I reached 0 OPF, indicating significant improvement, while Group II reduced further to 1.41±0.60 OPF. both the groups showed a significant reduction in bacterial count on 14th

day post-treatment, while Group I showed a quicker and more pronounced response than Group II. The variation in effectiveness can be attributed to the divergent modes of action: Cefpodoxime’s dependence on time for its activity and Marbofloxacin’s reliance on concentration for its activity (Nuttal, 2016).

Summary

Cytological assessment is pivotal for discerning the etiological microorganisms in otitis externa. In chronic cases, *Pseudomonas spp.* predominated (52.17%) as the causative agent. Sensitivity testing revealed Marbofloxacin’s superior efficacy (85.17%), whereas Amoxicillin displayed the lowest efficacy (14.28%). In the

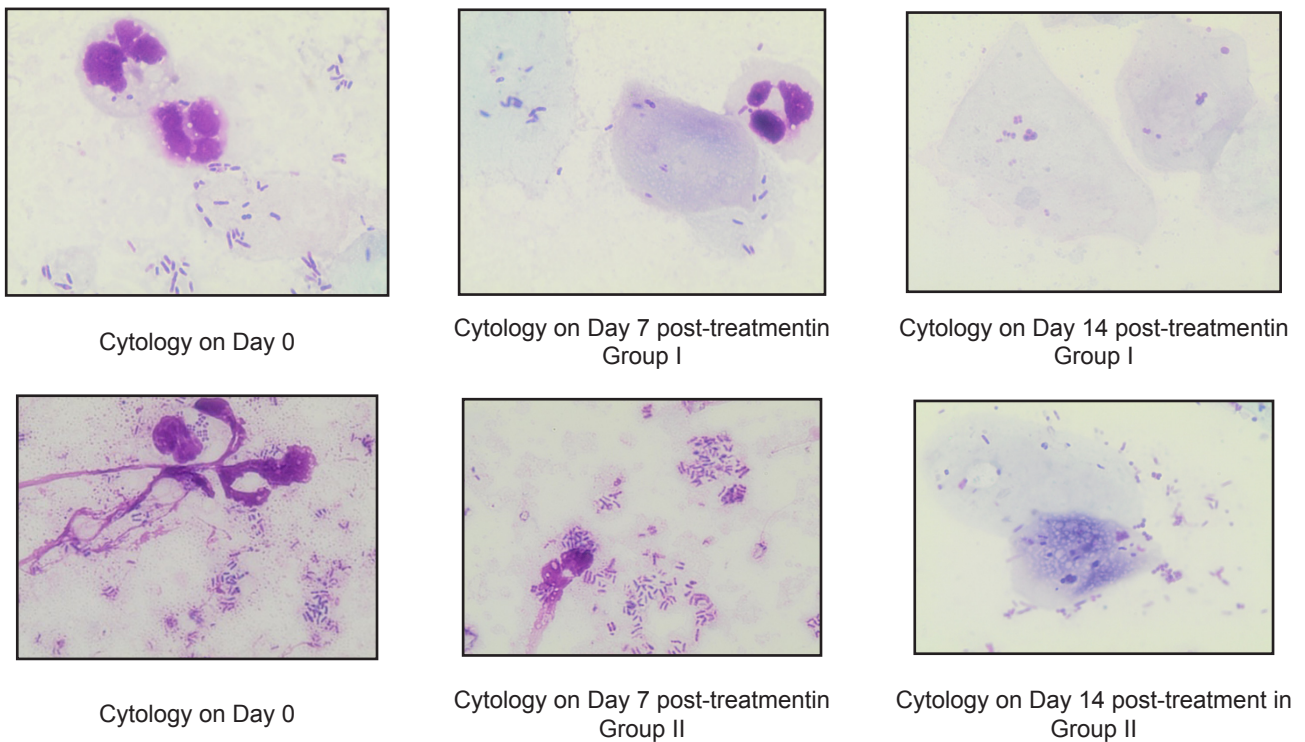


Fig 2. Cytological analysis post-treatment in both the groups

management of chronic otitis externa, a Marbofloxacin and Gentamicin combination yielded enhanced therapeutic outcomes.

References

- Bourély, C., Cazeau, G., Jarrige, N., Leblond, A., Madec, J. Y., Haenni, M. and Gay, E. (2019) Antimicrobial resistance patterns of bacteria isolated from dogs with otitis. *Epidemiology & Infection*: **147** : e121.
- Bugden, D. L. (2013) Identification and antibiotic susceptibility of bacterial isolates from dogs with otitis externa in Australia. *Aust. Vet. J.* **91(1-2)** : 43-46.
- Ginel, P.J., Lucena, R., Rodriguez, J.C. and Ortega, J. (2002). A semiquantitative cytological evaluation of normal and pathological samples from the external ear canal of dogs and cats. *Vet. Dermatol.* **13(3)**:151-156.
- Jerzsele, Á. and Pásztiné-Gere, E. (2015) Evaluating synergy between marbofloxacin and gentamicin in *Pseudomonas aeruginosa* strains isolated from dogs with otitis externa. *Acta. microbio. Immunol. Hung.* **62(1)**:45-55.
- Leonard, C., Thiry, D., Taminiau, B., Daube, G. and Fontaine, J. (2022) External ear canal evaluation in dogs with chronic suppurative otitis externa: Comparison of direct cytology, bacterial culture and 16S amplicon profiling. *Vet. Sci.* **18;9(7)**:366.
- Lozek, A., Dennis, R., van Dijk, J. and Bannoehr, J. (2020) Occult otitis media in dogs with chronic otitis externa—magnetic resonance imaging and association with otoscopic and cytological findings. *Vet. dermatol.* **31(2)**:146-e28.
- Martin Barrasa, J. L., Lupiola Gomez, P., Gonzalez Lama, Z. and Tejedor Junco, M. T. (2000) Antibacterial susceptibility patterns of *Pseudomonas* strains isolated from chronic canine otitis externa. *Vet. Med.* **47(3)**:191-6.
- Morris, D. O. (2004) Medical therapy of otitis externa and otitis media. *Vet. Clin. North Am. Small Anim.* **34**:541–555.
- Nuttall, T. (2016) Successful management of otitis externa, *In Practice.* **38**:17–21.
- Paterson, S. and Matyskiewicz, W. (2018) A study to evaluate the primary causes associated with *pseudomonas* otitis in 60 dogs. *J. Small Anim. Pract.* **59**:238–242.
- Shaw, S. (2016) Pathogens in otitis externa: diagnostic techniques to identify secondary causes of ear disease. *In Pract.* **38**:12-6.
- Zur, G., Lifshitz, B. and Bdolah Abram, T. (2011) The association between the signalment, common causes of canine otitis externa and pathogens. *J. Small Anim. Pract.* **52(5)**:254-8.