

## Histopathology and Immunohistochemistry of an Atypical Case of Cutaneous Fibroma in a Crossbreed Cow - A Case Report

Siva, S., R. Sarangabani, Pazhanivel, N\*., and Ganne Venkata Sudhakar Rao

Department of Veterinary Pathology, Madras Veterinary College, Chennai - 600 007

(Received : June, 2023 109/23 Accepted : March, 2024)

### Abstract

Fibroma is an uncommon benign neoplasm of mesenchymal origin in animals. It arises from any site containing connective tissue including dermal and subcutaneous fibroblast. A Five year old female crossbred Jersey cow was presented to the Veterinary Dispensary. The animal had a pedunculated soft mass in its pole region. The mass was removed successfully and sent for histopathological examination in 10% neutral buffered formalin. Microscopical examination revealed a haphazard arrangement of neoplastic spindle-shaped fibrocytes, elongated to oval-shaped nuclei with indistinct eosinophilic cytoplasm, and stray mitotic figures were seen. Special staining with picosirius red revealed positive red-coloured neoplastic fibrocytes. Immunohistochemistry examination with a vimentin marker showed a positive brown-coloured cytoplasmic reaction. Based on the gross, histopathological, special staining, and immunohistochemistry, the tumor mass was confirmed as a cutaneous fibroma.

**Key words** : Crossbred cow, fibroma, pathology, special staining, immunohistochemistry.

Fibroma is an uncommon benign neoplasm of mesenchymal origin in animals. It arises from any site containing connective tissue including dermal and subcutaneous fibroblast. The fibroma may be hard or soft depending upon the amount of collagen present. Unlike its incidence in canines and equines, fibroma is

regarded as an unusual finding in cattle. The cutaneous fibroma may cause hindrance in the routine activity of animals depending upon its location on various body parts and also decreases the artistic and aesthetic value of the animals.

The differential diagnosis of cutaneous fibroma includes melanoma and sarcoma, which also having spindle-type cells. The present report describes the gross, histopathological, special staining, and immunohistochemical findings of an atypical case of cutaneous fibroma in a crossbreed cow.

### Case History and Observations

A Five-year-old female crossbred Jersey cow was presented to the Veterinary Dispensary. The animal had a pedunculated soft mass on its pole region measuring about 10 cm in length. The affected part was alopecic and dark in color caused by the repeated external injury to the region. The animal was operated on successfully and excised tissue was fixed in 10% neutral buffered formalin.

The formalinized tissue sample was sent to the Department of Veterinary Pathology, Madras Veterinary College, Chennai for histopathological examination which was processed as per the standard procedure (Bancroft and Gamble, 2008). Tissue sections were further embedded in paraffin wax and 5-micron sections were obtained using tissue microtome and stained with H&E, special staining, and IHC.

### Treatment and Discussion

Gross pathological examination of the surgically


\*Corresponding author : Email : drnpvel@gmail.com

excised mass revealed a well-pedunculated soft to firm gray-white-colored mass about 10cm in length (Fig. 1). Cut section of the mass revealed congestion, firm, and also appeared as grey in color.

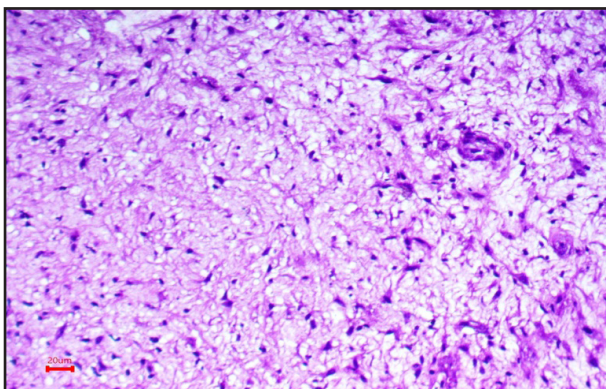
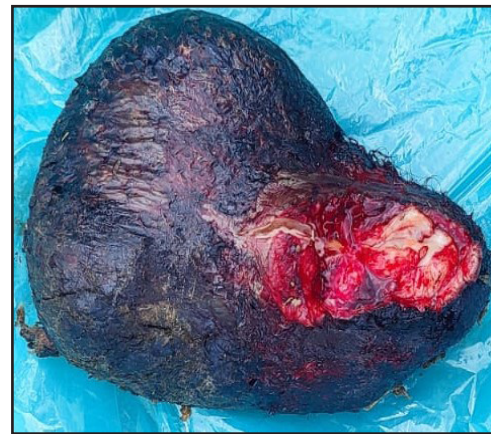On microscopical examination of the mass revealed that the neoplastic area was seen in the dermal region of the skin, which consist of interlacing bundles of neoplastic proliferating fibrocytes and collagen fibers arranged in a haphazard pattern (Fig. 2). The neoplastic cells were spindle-shaped with pale ovoid to elongated nuclei with indistinct cytoplasm. The nuclei contained single to multiple nucleoli and mitotic figures were scanty. It also revealed variable degrees of vascularization with normal stratified epithelial covering. Picrosirius red special stained tissue revealed the presence of red-colored neoplastic fibrocytes.

These should be differentiated with melanoma and sarcoma and excluded because no muscle cells or melanin were identified on histochemical staining. Based on the gross appearance of the mass, fibropapilloma was also considered in the differential diagnosis. According to a previous report a fibropapilloma should show features of acanthosis, hyperkeratosis, the down-growth of rete-ridges, and the dermal proliferation of plump fibroblasts microscopically. However, we could not detect any proliferative disorder of the epidermis in the mass (Daset *et al.*, 2020).

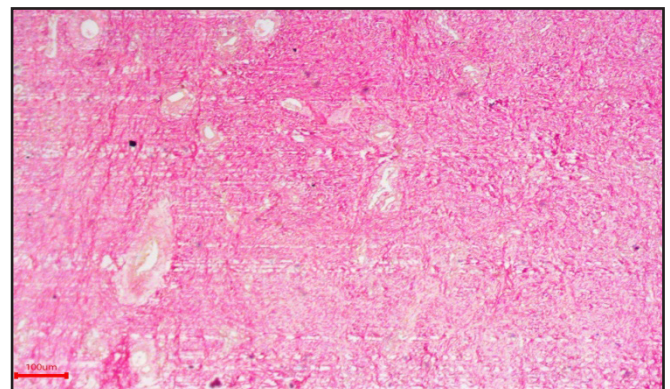
Benign mesenchymal tumors can often be diagnosed based on their histological appearance (Goldschmidt and Hendrick 2000). Based on the gross, histology and special staining, and IHC the present case was confirmed as cutaneous fibroma on the pole region. There are a few reports concerning fibroma in cattle. A solitary



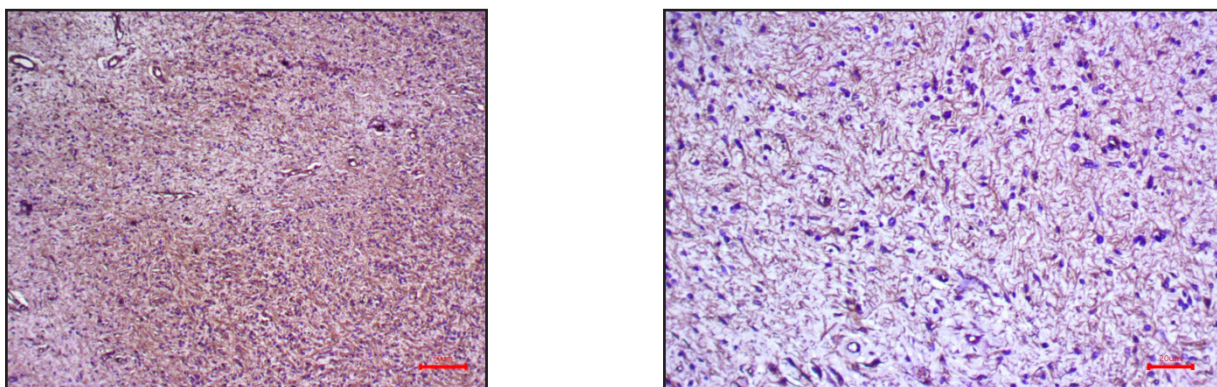
**Fig. 1** Crossbred cow-Fibroma-Well pedunculated soft to firm gray(dark) colored mass



**Fig. 2** Crossbred cow-Fibroma-Interlacing bundles of neoplastic proliferating fibrocytes and collagen fibers were arranged in haphazard pattern Scale Bar H&E 50µm



**Fig.3** Crossbred cow-Fibroma- Red colored neoplastic fibrocytes-Picrosirius red- Scale bar 50µm



**Fig.4** Crossbred cow-Fibroma-Strong positive brown coloured cytoplasmic reaction-Vimentin 50µm.

case of fibroma in the teat has been reported in a heifer (Ford *et al.*, 1989). There is also a report of multiple perianal fibromas in a cross-bred cow (Gahlod *et al.*, 1998). A report of cutaneous fibroma in the skin of the right hindlimb of one-year-old male Korean Indigenous cattle (Jang *et al.*, 2008). A report of dermal fibroma of the left paralumbar region in a heifer (Pazhanivel *et al.*, 2021) while the previous author recorded the tumors in various age groups from nine months to seven years in female cattle (Vijayakumar *et al.*, 2020). Fibroma in some species is caused by papillomaviruses. A few papillomaviruses (deer fibroma virus and bovine papilloma virus) produce tumors of fibrous connective tissue rather than papillomas (Jones *et al.*, 1997). Papillomavirus was consistently detected using rabbit antiserum against papillomavirus group-specific antigens in all mule deer fibromas and bovine fibro papillomas (Sundberg *et al.*, 1985). According to the literature, subcutaneous fibroma is a rare tumor in ruminants, So the authors believe this case presents a very uncommon type of this tumor in a crossbred cow.

### Summary

Though the origin of cutaneous fibroma is not clear, but this case is notable for the unusually large size of the tumor in the pole region. The macro- and microscopic characteristics of the cutaneous fibroma in this case corroborate with other cases reported in the literature. It's important to distinguish it from other types of tumors like fibrosarcoma and myxosarcoma, which can be malignant through the use of special staining and immunohistochemistry techniques.

### References

- Bancroft JD and Gamble, M (2008). Theory and practices of histological techniques. 6th Edn. Churchill Livingstone, Elsevier, China. pp.126- 127.
- Das T, Das N, Sahoo M, Dinesh M, Vineetha S, Sethi M, John JK, Beena V, Thakur P, Tomar N and Kumar GS (2020). Pathology and immunohistochemistry of an unusual case of cutaneous fibroma in a crossbred cow-a case report. *Indian J. Vet. Pathol.*, **44**(4) : 252-254.
- Ford TS, Ross MW, Acland HM, and Madison JB (1989). Primary teat neoplasia in two yearling heifers. *J Am Vet Med Assoc.* **195**: 238– 239.
- Gahlod BM, Marudwar SS, Patil SN, Dhakate MS and Kurkure NV (1998). A case of multiple perianal fibroma in a cross-bred cow. *Indian Vet J* **75** : 1134–1135.
- Goldschmidt MH and Hendrick MK (2000). Tumors in domestic animals, 4th edn. Iowa State Press, Iowa, pp 84–85.
- Goldschmidt MH and Hendrick MJ (2002). Tumors of the skin and soft tissues. In: Tumors in Domestic Animals, 4th ed. (Meuten, D.J. Ed.). Iowa State Press, Iowa. pp.84-91.
- Jang SJ, Kim HK, Shin TK, Cho GJ and Kwon OD (2008). A case of cutaneous fibroma in a Korean indigenous cattle. *J Vet Clin* **25**(3) : 200-201.
- Jones TC, Hunt RD, and King NW (1997). Veterinary Pathology, 3rd edn. William and Wilkins, Pennsylvania, pp. 864.
- Pazhanivel, N., Sarangabani, R., Saahithya, R., Dasari Priyanka Swami and Ganne Venkata Sudhakar Rao (2021). Cutaneous Fibroma in a Jersey Cross Breed Heifer. *Int J Curr Microbiol App Sci* **10**(03) : 1476-1479.
- Sundberg JP, Williams ES, Hill D, Lancaster WD, and Nielsen SW (1985). Detection of papillomaviruses in cutaneous fibromas of whitetailed and mule deer. *Am J Vet Res* **46** :1 145–1149.
- Vijayakumar, S., Lakkawar, AW., Kumar, R., Alphonse, RMD and Nair, MG (2020). Pathomorphological studies on mesenchymal and melanocytic neoplasm in cattle. *VMPH.* **1**(3) : 102- 107.