

## Therapeutic Management of Theileriosis in *Holstein Friesian* Cows

Gagandeep Singh<sup>1</sup>, Deepak Sumbria<sup>2\*</sup>, Nischal Dutta<sup>3</sup>, Rabjot Kour<sup>4</sup>,  
Anand Prakash<sup>5</sup>, Kapil Gupta<sup>6</sup> and Vikrant Sudan<sup>7</sup>

Department of Veterinary Parasitology, College of Veterinary Science, Rampura Phul, GADVASU.

(Received: February 2024

23/24 Accepted: July 2024)

### Abstract

One of the most important tick borne haemoprotozoan disease in livestock is Theileriosis. This disease causes heavy morbidity and mortality in cattle and result in financial loss to the dairy farmer. *Theileriaannulata* is one of the main protozoan parasites responsible for Theileriosis in India. Current manuscript report two cases of Theileriosis in RampuraPhul along with its haematological finding and therapeutic management. Conventional method of parasite screening revealed comma shape of parasite in red blood cell and Koch's blue body in lymphocyte. The infected animal was treated with Butalex @2.5 mg/kg BW plus supportive treatment and eventually animal recovered from infection

**Keywords:** *Theileriosis, Holstein Friesian, tickborne parasite, neutrophilia, Butalex*

Arthropods transmit many microbial and parasitic diseases and out of them Theileriosis is of important concern. In India, the losses due

to arthropod and arthropod borne diseases in livestock have been projected to be around 2000 crores/year (Minjaw and McLeod,2003). This disease is present in tropical and sub-tropical parts of world and hampers the health, management and productivity of domesticated cattle. Theileriosis is tickborne disease (*Amblyomma, Haemaphysalis, Hyalomma* and *Rhipicephalus*) and depending on the species of animal it is caused by various species of parasite such as *Theileriaparva, T. mutans, T. bovis, T. annulata, T. hirci, T. ovis* etc. In India cattle mainly exotic cattle are infected by *T. Annulate* and it is mainly transmitted *Hyalommaanatolicum*. Infected animal shows various symptom such as enlarge lymph node, high fever (104.2-104.8°F), lachrymal and nasal secretion, petechial haemorrhages on conjunctiva, rough hair coat, initial constipation followed by diarrhoea, emaciation, dullness, weakness, laboured respiration and if not treated it can lead to death of animal (Soulsby,2005, Bhatia *et al.*,2016).

Diagnosis of Theileriosis can be done by conventional (thin blood smear examination for the detection of piroplasm form in RBC and Koch's blue body in lymphocyte), serological and molecular method. Very few studies have shown the prevalence of Theileriosis in Bhatinda area of Punjab. This report shows the occurrence of 2 cases of Theileriosis in exotic breed of cattle the RampuraPhul area in Bathinda district.

### Materials and methods

#### Study areas

In India, Punjab province covers 50,362 km<sup>2</sup> and is located in north western location. Its geographic location is between 29°30'N-32° 32'N latitude and 73°55'E-76°50'E longitudes (<http://>

\*Corresponding author : Email : [deepak\\_sumbria@yahoo.com](mailto:deepak_sumbria@yahoo.com)

<sup>1</sup>Assistant Professor, Veterinary Medicine, Department of Veterinary Clinical Complex, College of Veterinary Science, Rampura Phul, GADVASU. Email : [gagandeepbright@gmail.com](mailto:gagandeepbright@gmail.com)

<sup>2,4</sup>Assistant Professor, Department of Veterinary Parasitology, College of Veterinary Science, Rampura Phul, GADVASU.

Email : [deepak\\_sumbria@yahoo.com](mailto:deepak_sumbria@yahoo.com), [rabjot.vets@gmail.com](mailto:rabjot.vets@gmail.com)

<sup>3</sup>Assistant Professor, Department of Veterinary Pathology, College of Veterinary Science, RampuraPhul, GADVASU.

Email : [nishchal091@gmail.com](mailto:nishchal091@gmail.com)

<sup>5</sup>Assistant Professor, Department of Livestock Farm Complex, College of Veterinary Science, RampuraPhul, GADVASU.

Email : [anandprakash0412@gmail.com](mailto:anandprakash0412@gmail.com)

<sup>6</sup>Assistant Professor, Department of Veterinary Medicine, College of Veterinary Science, RampuraPhul, GADVASU.

Email : [dr.kapil09@gmail.com](mailto:dr.kapil09@gmail.com)

<sup>7</sup>Associate Professor, Department of Veterinary Parasitology, College of Veterinary Science, RampuraPhul, GADVASU.

Email : [viks.sudan@gmail.com](mailto:viks.sudan@gmail.com)

[www.bharatonline.com/punjab/travel-tips/location.html](http://www.bharatonline.com/punjab/travel-tips/location.html) accessed on 19-02-2022). Three major seasons in Punjab are summer (mid-April to end of June: Avg rain = 51.6 mm; Avg temp = 34 °C), monsoon (July-September Avg temp=20 °C; Avg rain=395.2mm) and winter (October-March: Avg rain = 119.1 mm; Avg temp = 13 °C). The state is divided into 5 agro-climatic zones. Infected animal has arrived from local village at clinical livestock complex from college of Veterinary Science, RampuraPhul which is located in Bathinda district.

### History of animals

Two *Holstein friesian* cows of 3 year of age had arrived from Mehraj Village at clinical livestock complex of College of Veterinary Science, RampuraPhul. Both animals had history of anorexia, off fed, dullness. On routine clinical examination it was noted that both animal was having high temperature (>104°F), marked paleness of vaginal membrane and eyelid was also noted (Fig 1). Local lymph node was also swollen. The owner told that on his farm the tick infestation is very often.

### Sample collection

Blood samples (2 ml) were collected directly from jugular vein in EDTA coated vacutainers and sent to the pathological and parasitological laboratory for performing haematological and parasitological examination.

### Blood film examination

2 thin blood films of each blood sample were prepared, dried and then fixed in absolute methyl alcohol for 1-2 min. The smear was immersed into diluted Giemsa stain for 30–45

min, and then washed with distilled water to remove excess of stain. After that the slides were left to dry and then examined under oil immersion lens (Coles, 1986).

### Haematological analysis

Various haematological parameters of the whole blood such as haemoglobin level (Hb), total leukocyte count (TLC), total erythrocyte count (TEC), packed cell volume (PCV), and platelet were studied on fully automated analyser, Haematology System. Differential leucocyte count was also performed manually as per standard procedure.

### Treatment

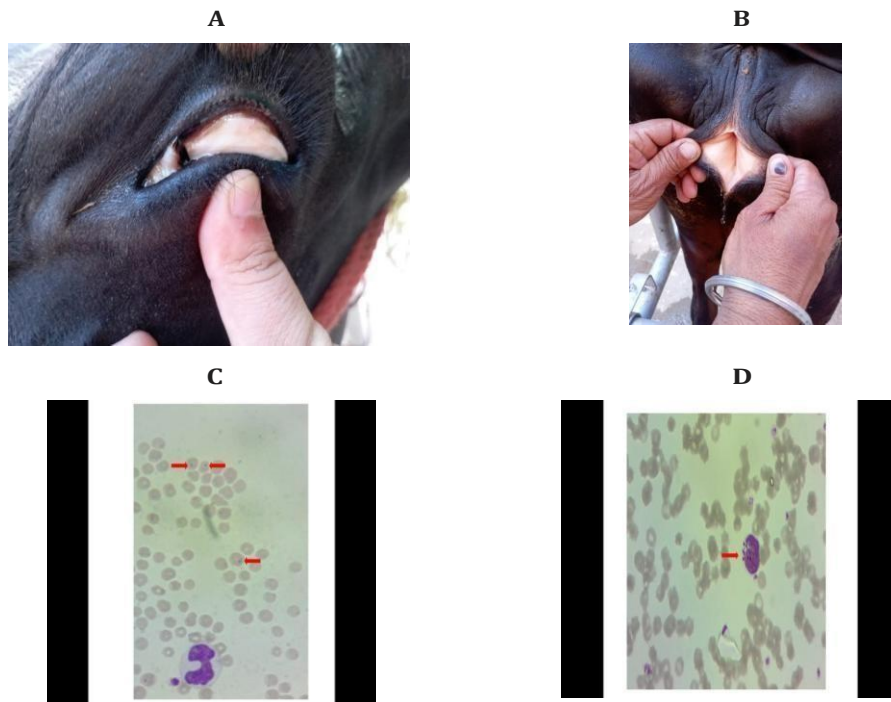
The animals were treated with a single dose of Buparvaquone 5% @ 2.5 mg/kg Bwt I/M at two different sites in neck muscles, oxytetracycline long acting@ 20 mg/kg Bwt I/M was also injected at 48 hours intervals for two times. Supportive therapy such as fluid therapy (Dextrose 5%, Normal Saline Solution) 5 liters I/V daily for 3 days, antipyretic @ 2 mg/kg Bwt I/M for 3 days, haematinic @ 50 ml daily orally for 10 days, rumenotonic 2 bolus twice a day orally for 5 days. Liquid Brotone@ 50 ml daily orally for 10 days was also provided to the animal.

### Results and Discussion

One of the most important tick borne parasite is *Theileria* and it cause devastating disease in cattle i.e. Theileriosis. Clinical examination of animal showed anaemic condition, enlarge lymph node, high temperature, all these are typical sign of Theileriosis similar results were also observed in other case reports (Islam *et al* 2017). On thin blood smear examination both samples depicted comma form of *Theile-*

**Table I.** Haematological analysis of animals

Sl no	Parameters	Animal 1	Animal 2
1	Haemoglobin (g%)	6	6.7
2	Total leukocyte count (cu mm)	5.6	5
3	Total erythrocyte count (cu mm)	3.19	4.22
4	Packed cell volume (%)	16.8	18.6
5	Platelet	190000	812000
6	Neutrophils	60	40
7	Lymphocyte	24	50
8	Eosinophil	-	10
9	Monocytes	16	-



**Fig 1A-D:** (A) Pale mucus membrane of eye (B) Pale vaginal mucus membrane (C) piriform of theileria in RBC (D) Koch's blue body in lymphocyte.

riaspp (Fig 2), such form is also noted in other researcher also (Tuli *et al*,2015). Haematological examination of one animal revealed anaemia with no regenerative relative neutrophilia with bizarre nuclei and monocytosis while other animal showed only borderline relative neutrophilia (Table I); these results were in concordant with other studies (Tuli *et al*,2015; Narang *et al*,2019). After treatment temperature reduced to 101.8°F in both the animals. Hb and PCV levels improved after 3 weeks. Appetite was also back to the normal of these animals and their overall health was improved. Treatment with Butalex was also shown very effective in other studies (Soulsby 2005.). As per our knowledge this was the first case report of bovine theileriosis from RampuraPhul area in Bathinda (Pb).

#### Acknowledgement

Authors are thankful to the Dean, COVS, RampuraPhul for providing us the facility to conduct the work

#### Reference

- Bhatia BB, Pathak KML and Juyal PD. (2016). Textbook of Veterinary Parasitology. Kalyani publication.
- Coles EH, (1986). W.B. Saunders (Ed.), Veterinary Clinical Pathology, 4th ed., 1986 Co, Philadelphia.
- Islam ST, Dar RR, Sheikh AA, Dogra P, Gupta R, Patel R, Ganaie MY and Wani JM. (2017). Theileriosis in a Calf: A Case Study. *Int.J.Curr.Microbiol.App.Sci* **6**(10) : 1400-1404.
- Minjaw B and McLeod A. (2003). Tick-borne diseases and poverty: the impact of ticks and tick-borne disease on the livelihoods of small-scale and marginal livestock owners in India and eastern and southern Africa. Research report, Department for International Development Animal Health Programme. pp 116. Centre of Tropical Veterinary Medicine, University of Edinburgh, Scotland.
- Narang A, Singh Randhawa S, Kumar Sood N, Chhabra S, Singla LD and Kaur P. (2019). Atypical theileriosis with cutaneous involvement in a cow in India: a case report. *Rev Sci Tech*. **38**(3) : 703-709.
- Soulsby ELJ. (2005). Helminths, Arthropods and Protozoa of Domestic Animal, 7th edition, Elsevier.
- Tuli A, Singla LD, Sharma A, Bal MS, Filia G and Kaur P. (2015). Molecular epidemiology, risk factors and haematochemical alterations induced by *Theileria annulata* in bovines of Punjab (India). *Acta Parasitol* **60**(3) : 378-90.