

Gross Anatomy, Morphometric and Micrometrical Studies of the Caecal Tonsil *Siravidai* Chicken of Tamil Nadu

Sridevi, P. *, Sabiha Hayath Basha, S.Usha Kumary, N.Pazhanivel and P. Veeramani,
J.Violet Beulah and Geetha Ramesh

Department of Veterinary Anatomy, Madras Veterinary College, Chennai-600 007.

(Received: July 2024 146/24 Accepted: July 2024)

Abstract

The study aimed to investigate the gross morphological and micrometricage-related changes in the caecal tonsil of *Siravidai*, a native chicken breed from Tamil Nadu. The tissue samples from six birds of each age were collected from day-old, 4th week, 8th week, 12th week, 18th week, 24th week and 52nd weeks respectively. Both male and female *Siravidai* chickens were included in the study. Age-related morphological changes present in the caecal tonsil were observed and recorded. The topography of the caecal tonsil across all age groups was found similar, with slight variations in morphology. In the day-old and 4th week, the caecal tonsils were relatively underdeveloped, as tiny projections but from 12th week onwards, they had become more clearly visible and more distinct and defined peanut size as the birds matured. This maturation was marked by an increase in the number and size of lymphoid follicles, enhancing the bird's ability to mount an effective immune response. Statistical analysis of both morphometry and micrometrical data showed that caecal tonsil reached to their maximum size by 18th week of age and gradually decreased during 24th and 52nd week of age, which may be correlated with the depletion of the lymphoid tissue as age advanced. The caecal tonsil reached its peak activity by the 18th week of age in *Siravidai* Chicken breed.

Keywords: *Gross Anatomy, Morphometry, Micrometry, Caecal tonsils, Siravidai chicken*

Indigenous chicken are well known for their adaptive superiority in terms of their resistance to endemic diseases and other extreme environmental conditions (Nwakpu *et al.*, 1999). The indigenous *Siravidai* chicken is one such chicken ecotype reared as backyard poultry in Ariyalur district of Tamil Nadu state of India (Richard *et al.*, 2023). The caecum plays an important role in the digestion of small food particles, absorption of nutrients and production of immunoglobulin and antibodies (Clench, 1999) in birds. Presence of the caecal tonsils was functionally important since they are the most prominent lymphoid structure besides the Bursa of Fabricius in the alimentary tract of fowl (Payne, 1971). Caecal tonsils represent one of the major components of the Gut Associated Lymphoid Tissue (GALT) (Del Moral *et al.*, 1998); it has an important role in antigen sampling (Sorvari and Sorvari, 1977) and is also involved in antigen-specific humoral response (Jankovic and Mitrovic, 1967).

In *Siravidai* chicken, there is no information on the gross morphology, morphometrical and micrometrical studies of the caecal tonsil, especially in relation to age-related changes. The goal of the current study is to uncover the caecal tonsil of *Siravidai* chicken under different age groups. Understanding the morphology of the caecal tonsil can provide valuable insights into the health and immune status of the bird, as its appearance changes with age, reflecting the development and function of the immune system. This paper is the first of its kind exploring the gross anatomy, morphometry and

*Corresponding author: Email: devisri1890@gmail.com

micrometry of the caecal tonsil across different age groups in *Siravidai* chicken breed of Tamil Nadu.

Materials and Methods

Experimental birds and sample collection

The experimental birds for this study were collected from *Siravidai* flock raised in a healthy environment at the Poultry Research Station (PRS), Madhavaram milk colony, TANUVAS, Chennai-51 as per the standard managerial practices after obtaining Ethical Committee approval No. 11/SA/IAEC/2023. Apparently, healthy *Siravidai* chickens were transferred from PRS to the Department of Veterinary Anatomy, Madras Veterinary College, Chennai-07 for downstream processing under laboratory conditions. Birds were sacrificed as per the guidelines of the committee for control and supervision of experiment on animals (CCSEA). The abdominal cavity of the birds was cut opened through a ventral coelomic incision and the gastrointestinal tract was exposed. The gross anatomical feature of the gastrointestinal tract was examined on fresh and unfixed specimens immediately after exsanguination.

Gross Anatomy-morphometric study

Six birds each belonging to different age groups; day-old, 4th week, 8th week, 12th week, 18th week, 24th and 52nd week were utilized for the study. The proximal part of the caecum was collected and dissected to visualize the caecal tonsil. The caecal tonsils from different age groups were collected and tissue specimens were washed in normal saline. Gross morphometric measurements such as length and width (mm) of the caecal tonsils were recorded using Vernier calliper. The colour of caecal tonsils was observed and recorded through a digital camera.

Micrometry study

After the macro anatomical studies, samples were thoroughly rinsed in normal saline, and then fixed using 10 per cent neutral buffered formalin (NBF) solution for further processing. The fixed tissue samples were processed by paraffin embedding and thin sections of 4 to 5µm were subjected to the standard Haematoxylin

and Eosin (H&E) staining protocol to facilitate histological examination. To record the micrometry, length and width of the lymphoid nodules in the caecal tonsil was measured using Leica application suite (LAS V4.4) in Leica microscope (CH9345 Heerbrugg).

Statistical analysis

One-way ANOVA test was performed to analyze the morphometric and micrometry data collected in this study. Post hoc Duncan's multiple range test was performed following significant ANOVA test to indicate significant means across the age groups. The morphometrical and micrometrical parameters under study were represented as mean±standard error.

Results and Discussion

Gross morphology

Under this study, in all age groups of *Siravidai* chickens, caecal tonsils were situated at the *proximal end of each of the caecal pouches* near the ileo-caeco-colic junction as reported in bantam fowl by Looper and Looper (1929) and in chicken by Payne (1971); Olah and Glick, (1979); and in Japanese quail by Usha Kumary *et al.*, (2002). However, the location of the caecal tonsils differs in birds. McLelland (1990) reported that two caecal tonsils were located in the medial wall of each caecum near its junction with the colorectum in canary and pigeon. Firth (1977) and Del-Cacho *et al.*, (1993) in chicken reported the presence of the caecal tonsil at the caudal ends of the caeca. The terminal part of the small intestine and caeca open directly at the junction between the ileum and rectum in chickens, turkeys, pigeons, quail and ducks (Saleh *et al.*, 2023). Various authors had documented both the presence and absence of the caecal tonsil. In birds, the presence of caecal tonsil were reported in pigeon, ducks, geese, galliforms, ostriches, and owls (Pereira, 2006; Arent *et al.*, 2010). In contrast, caecum was absent in budgerigars (McLelland 1990), parrots, falconiformes and woodpeckers (Pereira, 2006; Arent *et al.*, 2010).

The caecal tonsils in the *Siravidai* chicken were covered by the peritoneum and had a very smooth surface in all age groups. The proximal part had a thickened wall and a

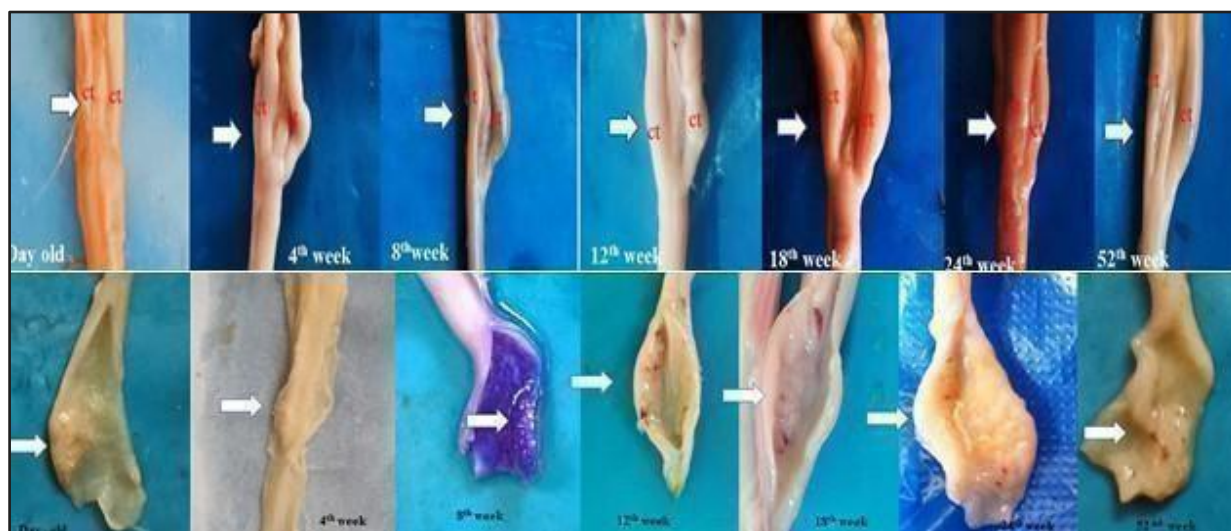


Fig 1. Gross photograph of the caecal tonsil in different age groups of *Siravidai* chicken

relatively narrow lumen in younger birds and the lumen widened as age increased. However, the caecal lumen varied from a very narrow lumen in pigeons and quail to a wide-diameter lumen in turkeys, ducks, and chickens (Saleh *et al.*, 2023).

Colour

The colour of the caecal tonsils was found varying across the age groups in this study. They appeared pale yellowish white and translucent in day old, then turned into pale-pink in colour from 4th to 12th week of age and became dark pinkish at 18th to 24th week of age (Fig. 1). The caecal tonsils became more opaque and light pink as age advanced and by 52nd week,

it appeared whitish-yellow in colour. Colour variation in caecal tonsils have been reported in different poultry species. Hussein and Reshag (2019) observed that the caecal tonsils were white to pink in 2nd and 7th month of age in Turkey and during postnatal stages, caecal tonsils were yellowish-white in Sonali chicken (Ayman *et al.*, 2021). On the contrary, in Desi chicken, the colour of caecal tonsils was observed to be greenish-yellow at the postnatal stages (Khalil, 2001).

In day-old and 4th week of age, the caecal tonsils appeared as tiny projections through the luminal wall, which were barely distinguishable from the surrounding intestinal tissue. By 8th week, it began to grow slightly larger and

Table I. Gross morphometric measurements of the width and length of the caecal tonsil in different age groups of the *Siravidai* chicken (Mean±SEM, n=6)

Age group	Width (mm)	Length (mm)
0 Day old	1.38 ± 0.024 ^a	2.52 ± 0.02 ^a
4 Week	3.26 ± 0.016 ^b	4.46 ± 0.021 ^b
8 Week	4.71 ± 0.023 ^c	5.66 ± 0.024 ^c
12 Week	5.52 ± 0.022 ^d	7.65 ± 0.055 ^d
18 Week	6.62 ± 0.036 ^e	10.72 ± 0.046 ^e
24 Week	5.32 ± 0.03 ^f	9.72 ± 0.046 ^f
52 Week	4.4 ± 0.056 ^g	8.83 ± 0.02 ^g
F -value	2.37**	2.37**

** Highly Significant difference among the groups (P≤0.01)

a-g Means within a column bearing different superscripts differ significantly

appeared as pinhead projection. By 12th week of the age, the projection increased to a peanut size which remained consistent by the 18th week of age. In 24th and 52nd weeks of age, the peanut size spots slightly decreased. Similar finding was recorded by Pramod kumar (1992) in white leghorn chicken. However, the caecal tonsil appeared as hemispheric or spherical dome-like protrusions in quail (Ragaa et al.,2017). In the present study, the caecal tonsil appeared as thick elevations outwardly on the surface of the caecal wall and became more pronounced from the 12th week to 18th week of age. Macroscopically, the caecal tonsil was seen as a tubular enlargement in the proximal region of each of the ceca was also documented in broiler chickens (Akter et al., 2006; Majeed et al.,2009) and other poultry species (Calhoun, 1932; Glick et al., 1978). Similar findings were also accounted in Turkey by Hussein and Reshag (2019).

Gross Morphometry

In this study, length of the caecal tonsil in *Siruidai* chicken was 2.52±0.332 mm at day old age group and it reached to a maximum of 10.72 ± 0.046mm by 18thweek of age with mean length gradually declining in later stages to 8.83 ± 0.02 mm by 52ndweek of age (Fig. 2). The width of the caecal tonsils was found similar to the pattern of caecal tonsil length, which reached to a maximum at 18th week of age (Table I). Increase in mean length and width of caecal tonsil recorded in this study, was also observed in desi chicken (Khalil, 2001) and Sonali chicken (Ayman et al., 2021). However, in duck, the proximal caecal tonsil measured 3-4 mm in size (Kitamura et al.,1976) and in Gallus, generally depending upon the

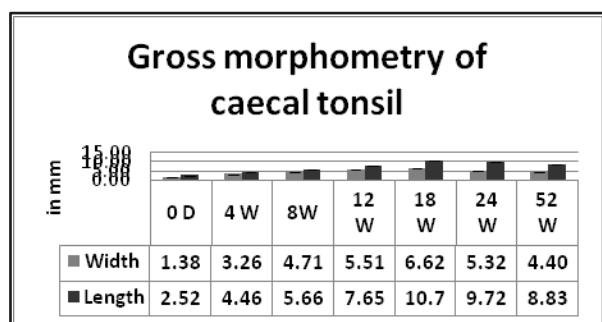


Fig 2. Morphometric measurements of the width and length of the caecal tonsil in different age groups of *Sriuidai* chicken

age of the bird the caecal tonsil ranged from 4-10 mm in size (Glick et al., 1978). During 24th and 52nd week, the decreased length and width of the caecal tonsil may be correlated with the depletion of the lymphoid tissue associated with the aging of birds.

Micrometry

In this study, diffuse lymphatic tissue was observed in day old chicken. The mean length of lymphatic nodules in caecal tonsil of *Siruidai* chicken was 53.52±0.014 µm on 4th week and it reached maximum to 210.40±0.039µm on 18th week (Fig. 3). The width of the lymphatic nodules in caecal tonsils was 38.68 ± 0.034 µm on 4th week which increased to 150.59±0.121 µm by 18th week of age (Table II) in similar pattern to the caecal tonsil length. Statistical results showed that the size of lymph nodules increased significantly upto 18th week of age and then decreased during 24th and 52nd week of age (P< 0.01). This was also evident from the decrease in the gross size of the caecal tonsil observed under this study. However, in broiler chickens at 28 days, the length and breadth of the lymphatic nodules in the ceecal tonsil were 255.20±20.46 µm and 186.08±24.90 µm, respectively (Akter et al., 2006). In Sonali chicken, the length of lymphatic nodule in caecal tonsil were 256.50±22.133 µm, 331.40±28.363 µm and 509.38±33.015 µm on 28th, 42nd and 56th day, respectively and the breadth of lymphatic nodule of caecal tonsil were 183.42±27.460 µm (28th day), 242.44±34.840 µm (42nd day) and 295.58±46.175 µm (56th day) (Ayman et al., 2021)..

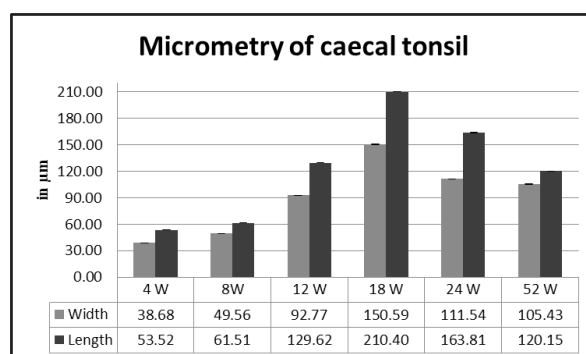


Fig 3. Micrometry of lymphoid nodule of the caecal tonsil in different age groups of *Siruidai* chicken

Table II. Micrometry of lymphoid nodule of the width and length of the caecal tonsil in different age groups of *Siravidai* chicken (Mean ± SEM, n=6)

Age group	Width (µm)	Length (µm)
4 Week	38.68 ± 0.034 ^a	53.52 ± 0.014 ^a
8 Week	49.56 ± 0.032 ^b	61.51 ± 0.022 ^b
12 Week	92.77 ± 0.045 ^c	129.62 ± 0.027 ^c
18 Week	150.59 ± 0.121 ^d	210.40 ± 0.039 ^d
24 Week	111.54 ± 0.038 ^e	163.81 ± 0.35 ^e
52 Week	105.43 ± 0.055 ^f	120.15 ± 0.033 ^f
F -value	2.53**	2.53**

** Highly Significant difference among the groups (P ≤ 0.01)

a-g Means within a column bearing different superscripts differ significantly

Conclusion

This study presents the gross anatomy, morphometry and micrometry of the caecal tonsil across various post hatch age groups in the *Siravidai* chicken, being first report in this breed. Significant changes were observed in the development of the tonsil in the caecum of the *Siravidai* chicken which may provide insights into avian health and disease prevention, highlighting their importance of maintaining a healthy gut environment for optimal immune function in birds.

References

- Akter SH, Khan MZI, Jahan MR, Karim MR, and Islam MR. (2006). Histomorphological study of the lymphoid tissues of broiler chickens. *Bangl. J. Vet. Med.*; **4(2)**: 87-92.
- Arent, L.R. Anatomia e Fisiologia das Aves. (2010). In: Colville, T.; Bassert, J.M. Anatomia e Fisiologia Clínica para Medicina Veterinária. 2 ed. Ed. Elsevier Saunders, Rio de Janeiro, pp.414-454
- Ayman, U., Jahid, M.A., Alam, M.R., and Das, S.K., (2021). Morphohistology and biometric characteristics of cecal tonsils of Sonali chicken at post-hatching ages. *Iraqi J. Vet. Med.* **45 (2)**, 1–6.
- Calhoun ML. (1932). Microscopic anatomy of the digestive tract of *Gallus domesticus*. *Iowa State journal of science.* **7**:122.
- Clench M H. (1999). Control: neural and hormonal. The avian caecum; update and motility review. *Journal of Experimental Zoology.* **283 (4)**: 44–47
- Del Cacho E, Gallego M, Sanz A, and Zapata A. (1993). Characterization of distal lymphoid nodules in the chicken caecum. *The Anatomical record.* **237**:512-517.
- Del Moral, M. G., Fonfría, J., Varas, A., Jiménez, E., Moreno, J., and Zapata, A. G. (1998). Appearance and development of lymphoid cells in the chicken (*Gallus gallus*) caecal tonsil. *The Anatomical Record.* **250(2)**: 182–189.
- Firth G.A. (1977). The normal lymphatic system of the domestic fowl. *Vet. Bull.* **47**: 167-178.
- Glick B, Holbrook KA, Olah I, Perkins WD, and Stinson R. (1978). A scanning electron microscope study of the caecal tonsil: the identification of a bacterial attachment to the villi of the caecal tonsil and the possible presence of lymphatics in the caecal tonsil. *Poultry science.* **57**:1408-1416.
- Hussein. A and Reshag F. (2019). Immunohistochemical and Histomorphological Study of Postnatal Development of the cecal tonsils in Turkey (*Meleagris Gallopavo*). *The Iraqi Journal of Veterinary Medicine.* **43(1)**:85 – 92.
- Jankovic BD, and Mitrovic K. (1967). Antibody-producing cells in the chicken, as observed by fluorescent antibody technique. *Folia biologica.* **13**:406-410.
- Khalil M. (2001) Age related histomorphological changes of lymphoid organs of deshi chicken of Bangladesh [Master]. Mymensingh, Bangladesh, Department of Anatomy and Histology: Bangladesh Agricultural University.
- Kitamura H Sugimura M Hashimoto S and Kudo N. (1976). Distribution of the lymphatic tissue in duck caeca. *Journal of Veterinary Research.* **24(1/2)**: 37–41.
- Looper, YB., and Looper MH., (1929). A histological study of the colic caeca in the bantam fowl. *J. Morph.* **48**:585-609
- Majeed MF, Al- Asadi FS, Al Nassir AN, and Rahi EH. (2009). The morphological and histological study of the caecum in broiler chicken. *Bas. J. Vet. Res.*; **8(1)**:19-25.
- Mclelland, J. (1990). A color Atlas of Avian Anatomy. Wolfe Publishing LTD. pp. 157-158.

- Nwakpu. P. E, B. I. Odo, S. I. Omeje, M. Akpa and C.C. Edoga, (1999). Hatching performance of three strains of layer type chicken and their lines. Proceedings of the 26th Annual Conference, NSAP, 21-25 March, Ilorin.
- Olah I and Glick B. (1979). Structure of the germinal centers in the chicken caecal tonsil: light and electron microscopic and autoradiographic studies. *Poultry science*. **58**:195-210
- Payne L N. (1971). Physiology and biochemistry of the domestic fowl. Bell D J and Freeman B M, Academic Press, London. Vol.2. (Eds)
- Pereira, R.J.G. (2006). Falconiformes e Strigiformes (**Águia**, Gavião, Falcão, Abutre, Coruja). In: Tratado de Animais-Selvagens Medicina Veterinária Cubas Z. S.; Silva J. C. R.; Catão-Dias J. L.. Editora Roca, São Paulo, pp.252-267
- Pramod Kumar, D. (1992) Microanatomical studies on the caecal tonsil in whit leghorn (wlh) birds. Master's dissertation, Andhra Pradesh. Agricultural University Rajendranagar. Hyderabad-600030.
- Ragga, M.E.D., Abdel, R.H.F., Samia, M.A.E.W. and Shima, A.E. (2017). Macroscopical and scanning electronmicroscopical studies on the rectal three birds. Middle East *Journal of Applied Sciences*, **7**(2): 250-261
- Richard, C., B. Vasanthi, Silambarasan and Paramasivan. (2023). Siruvidai chicken: A lesser known indigenous ecotype of Tamil Nadu. A conference paper on 38th Indian Poultry Science Association Conference (IPSA-CON) and National Symposium at Srinagar, India.
- Saleh TF., Omar Y., and Altaey Naziha Ahmed S. (2023). *Avian caecal tonsils Anatomy and Histology, A species comparison in five Iraqi domesticated birds. Al-Qadisiyah J. Vet. Med. Sci.*, **2**(21): 19
- Sorvari R and Sorvari TE. (1977). Bursa Fabrici as a peripheral lymphoid organ. Transport of various materials from the anal lips to the bursal lymphoid follicles with reference to its immunological importance. *Immunology.*, **32**:499-505
- Usha Kumary, S., Ramesh G and Vijayraghavan C. (2002). Lymphoid aggregation in the caecum and the colon of Japanese quail. *Indian Journal of Veterinary Anatomy* **14**(1/2): 16-21.

Indian Vet. J., August 2024, 101 (8): 50 - 52

Effect of *Mastiguard* in the Prevention and Treatment of Subclinical Mastitis in Dairy Cows

Suresh Kumar, P.*

Veterinary University Training and Research Centre, TANUVAS, Elambalur – 621 220. Perambalur (Dt), Tamil Nadu, India.

(Received: July 2024 148/24 Accepted: July 2024)

Abstract

A study was conducted to assess the efficacy of TANUVAS MASTIGUARD (Teat protect spray with TANUCHEK SCC kit) in dairy cattle during 2018-19 as On farm Trial (OFT) in the Annamangalam village of Perambalur district. Animals in mid lactation were screened with somatic cell count (SCC) test kit and animals had SCC of more than 2.0 lakh and twenty animals were selected for the study. One group

of 10 animals was kept as control and the other group of 10 animals were sprayed with teat protect (Mastiguard) for 6 weeks. The observations recorded at weekly intervals. At the end of 6th week, reduction in SCC of milk was recorded in animals of treatment group (1.5 lakh cells / ml) whereas the SCC remains same in control group (2.7 lakh cells/ml). The net returns from treatment group increased due to increase in milk production and reduction in cost incurred towards treatment. Hence, use of MASTIGUARD was found to be effective in prevention

*Corresponding author. Email: sureshkumar19742017@gmail.com