

Haemagalactia Associated with Multidrug-Resistant *Streptococcus agalactiae* in a Crossbred Holstein Friesian Cow

Azhar, D., A. Janus*, P.M. Deepa, K.C. Bipin, Biju P. Habeeb and V. Remya

Department of Veterinary Epidemiology and Preventive Medicine, College of Veterinary and Animal Sciences, KVASU, Pookode, Lakkidi P.O., Wayanad – 673576, Kerala

Received: August 2024

192/24

Accepted: October 2024

*Corresponding author's Email: janusa@kvasu.ac.in

ABSTRACT

A recently calved three-year-old Holstein Friesian crossbred cow was presented with the complaint of blood in milk from all four quarters. Clinical examination revealed slight swelling and pain of the udder. Haemato-biochemical parameters of the cow were within the normal range except for a low serum calcium. *Streptococcus agalactiae* was isolated from all four quarters based on Gram-stained morphology, cultural characteristics, biochemical tests and PCR. Multi-drug resistance and biofilm formation of the isolate were identified. The animal was treated with Ceftriaxone-tazobactam, tranexamic acid, meloxicam and calcium borogluconate and an uneventful recovery was observed.

Keywords: Haemagalactia, *Streptococcus agalactiae*, Multidrug resistance

Haemagalactia, or the presence of blood in milk, is a clinical sign often observed in dairy cows. Haemagalactia causes massive economic losses for the farmers because bloody milk is rejected by the industry and consumers. The infectious conditions mainly associated with haemagalactia are leptospirosis and several infectious pathogens-induced mastitis (Radostits *et al.*, 2007). Identifying the bacterial pathogens responsible for haemagalactia is crucial for implementing effective treatment strategies and minimizing economic losses incurred by dairy farmers. This case study presents the therapeutic management of haemagalactia associated with multidrug-

resistant *Streptococcus agalactiae* in a crossbred Holstein Friesian cow.

CASE HISTORY AND OBSERVATION

A three-year-old Holstein Friesian crossbred cow was presented to the Teaching Veterinary Clinical Complex, Pookode, Wayanad, with a history of haemagalactia from all four quarters for two days. The animal was in the second lactation and had calved three days back. There was no history of any trauma to the udder or teat. The animal was treated with a bolus of Styplon for one day. The vital parameters like temperature, heart rate and respiration rate were within the normal range on clinical examination. The feed intake of the animal was also normal. On palpation of the udder, slight swelling of the udder along with pain could be detected. Whole blood and serum analysis revealed normal hematological and biochemical parameters except for a low serum calcium (7.5 mg/dL). A peripheral blood smear ruled out the presence of haemoprotozoans. The colour of the milk varied from light red to pink. (Fig.1). The milk from all four quarters contained blood clots and flakes. Centrifugation of fresh milk at a speed of 12000 rpm for 2 minutes ruled out hemolysis (George *et al.*, 2008). (Fig. 2).



Fig. 1: Blood in milk from affected quarters



Fig. 2: Blood in milk after centrifugation

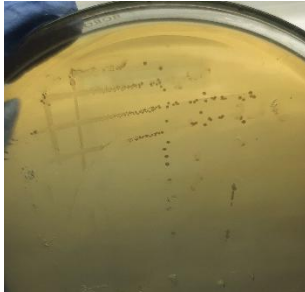


Fig. 3: Translucent small colonies of *Str. agalactiae* about 1 mm in diameter in BHIA

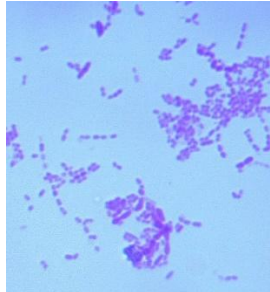


Fig. 4: Streptococci in chains after Gram staining

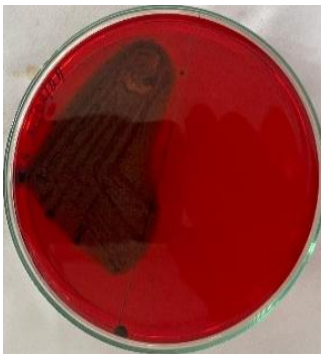

Fig. 5: Biofilm formation in the isolate in Congo red agar plate

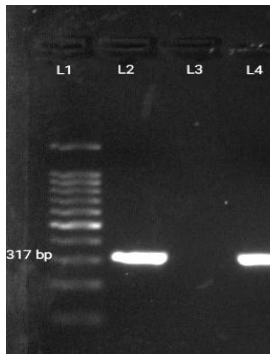


Fig. 6: Agarose gel electrophoresis of 16SrRNA specific PCR of *S. agalactiae* sp.; L1: DNA marker 100 bp, L2: positive control, L3: negative control, L4: sample (317 bp)

Isolation of bacteria was attempted from individual quarter samples by direct streaking of the milk onto brain heart infusion agar (BHIA), followed by incubation of plates at $37 \pm 0.5^\circ\text{C}$ for 48 hours. Bacterial isolate was identified based on morphology, Gram staining, cultural characteristics, biochemical tests as per Quinn *et al.* (2013) and polymerase chain reaction

Haemagalactia Associated... by Azhar *et al.* (Shome *et al.*, 2016). Congo red agar plates were prepared, and isolates were streaked onto it to study the biofilm formation ability of the bacteria. The isolate was a strong biofilm producer with black colonies of dry consistency and rough surface (Fig. 5). In vitro antibiotic sensitivity of the clinical isolates was studied using Kirby Bauer disc diffusion method (Bauer *et al.* 1966) as per the Clinical and Laboratory Standards Institute guidelines (CLSI, 2020). The isolate was resistant to enrofloxacin, amoxicillin, cefoperazone, gentamicin, tetracycline and sulphadiazine and was sensitive to ceftriaxone-tazobactam. Thus, based on the history, clinical examination, laboratory findings and molecular identification, the condition was diagnosed as haemagalactia associated with *Str. agalactiae*.

TREATMENT AND DISCUSSION

The cow was treated with Inj. Ceftriaxone-tazobactam @ 10 mg/kg BW IV SID for 5 days as per the result of the antibiotic sensitivity test, Inj. Tranexamic acid 10 ml IM for 3 days, Inj. Meloxicam @ 0.5 mg per kg IM for 3 days and Inj. Calcium borogluconate 500 ml slow IV for 2 days. The animal showed uneventful recovery after three days of therapy.

Streptococcus agalactiae is a contagious pathogen of bovine mastitis, and the mammary gland is considered the main reservoir of this bacterium in dairy herds (Tomazi *et al.*, 2018). and earlier study by Vatalia *et al.* (2021) reported bloody milk condition in cattle associated with multidrug-resistant *S. agalactiae*. In the present study, the only sensitive antibiotic was ceftriaxone-tazobactam which was in agreement with Vatalia *et al.* (2021). Bacteria that were resistant to three or more classes of antibiotics were defined as multidrug-resistant bacteria (Magiorakos *et al.*, 2012). The isolate in the present study was resistant to four different classes of antibiotics, indicating it as multidrug-resistant *S. agalactiae*. In the present study, the isolate was a strong

biofilm producer, which was in agreement with Oca *et al.* (2024). In the present study, all the hematological and biochemical parameters were within the normal range except serum calcium level, which can be substantiated by the absence of systemic signs in the cow. The low serum level, which is normally reported in the post-partum period, might also have hindered clot formation. The treatment was initiated in the affected cow with the antibiotic ceftriaxone-tazobactam, tranexamic acid and calcium. Calcium ions (Ca²⁺) are essential for the coagulation process, promoting multiple enzyme-catalysed reactions within the coagulation cascade (Tong *et al.*, 2024). Tranexamic acid is in a class of medications called antifibrinolytics. It works by blocking the breakdown of blood clots, which prevents bleeding (Das *et al.*, 2020). The animal showed uneventful recovery after five days of treatment for the mammary infections with antibiotics and supportive.

SUMMARY

The present study reports the occurrence of haemagalactia in a recently calved cow associated with mammary gland infection caused by multi-drug resistant, biofilm-forming *S. agalactiae* and its therapeutic management. Increased vascularisation of the udder during the post-partum period, immune suppression, hormonal imbalance and stress might have contributed to the condition.

REFERENCES

Bauer, A. W., W. M. Kirby, J. C. Sherris and M. Turck (1966), Antibiotic susceptibility testing by a standardised single-disk method, *Am. J. Clin. Pathol.*, **36**:493-496.

CLSI [Clinical and Laboratory Standards Institute] (2020), Performance Standards for Antimicrobial Susceptibility Testing (29th Ed). Clinical and Laboratory Standards Institute, Wayne, Pennsylvania, USA, 260p.

Das, D., N. Bora, C. Deka, E. Lucy, K. Poran, A.D. Bordoloi and K. Sarma (2020), Diagnosis and clinical management of haemagalactia in a Holstein

Haemagalactia Associated... by Azhar *et al.* Friesian crossbred cow, *J. Pharm. Innov.*, **9**: 195-197.

Magiorakos, A.P., A. Srinivasan, R.B. Carey, Y. Carmeli, M.E. Falagas, C.G. Giske, S. Harbarth, J.F. Hindler, G. Kahlmeter, B. Olsson-Liljequist and D.L. Paterson (2012), Multidrug-resistant, extensively drug-resistant and pan drug-resistant bacteria: an international expert proposal for interim standard definitions for acquired resistance, *Clin. Microbiol. Infect.*, **18**: 268–281.

Ocak, F., M.K. Turkyilmaz and S. Turkyilmaz (2024), The Relationship between Biofilm Formation and Multiple Antibiotic Resistance of Streptococcus Isolates from Bovine Milk with Mastitis, *Isr. J. Vet. Med.*, **79**:1.

Quinn, P., B. Markey, M. Carter and G.B. Carter (2013), Clinical Veterinary Microbiology. (2nd Ed). Mosby, St. Louis, 514p.

Radostits, O.M., C.C. Gay, K.W. Hinchcliff and P.D. Constable (2007), Diseases of the mammary glands. In: Veterinary Medicine. 10th ed, Saunders Elsevier, Philadelphia, Pennsylvania, 673-762.

Shome, B.R., S. Das Mitra, M. Bhuvana, N. Krithiga, D. Velu, R. Shome and H. Rahman (2011), Multiplex PCR assay for species identification of bovine mastitis pathogens, *J. Appl. Microbiol.*, **111**: 1349-1356.

Tomazi, T., A.F. de Souza Filho, M.B. Heinemann and M.V.D. Santos (2018), Molecular characterization and antimicrobial susceptibility pattern of Streptococcus agalactiae isolated from clinical mastitis in dairy cattle. *PLoS one*. **13**: e0199561.

Tong, L., Zhang, D., Huang, Z., Gao, F., Zhang, S., Chen, F and Liu, C. (2024). Calcium Ion-Coupled Polyphosphates with Different Degrees of Polymerization for Bleeding Control. *ACS Appl. Mater. Interfaces*.

Vatalia, D. J., Bhandari, B. B., Nimavat, V. R and Jhala, M. K. (2021). Isolation, molecular identification and multidrug resistance profiling of bacteria causing clinical mastitis in cows. *Agric. Sci. Dig. Res. J.* **41**: 345-351.