

## ***T. taeniaeformis* Infestation in Laboratory Rat**

Venkatesan, P.S., M.Eswarya and M.Madhavaselvi

Mass Biotech Private Limited, Padi, Chennai-600050

Email: massbiotech2019@gmail.com

Received: September 2024:

218/24

Accepted: October 2024

### **ABSTRACT**

The infection of *Cysticercus fasciolaris* (*C. fasciolaris*), the larval form of *Taenia taeniaeformis* (*T. taeniaeformis*) was reported in one of the lab rats (Wistar rats). The rat showed weight loss, lethargy, and poor coat condition. Gross pathology revealed a pale and soft cyst in liver, which was 1.5 cm in diameter. Inside the cyst, there was a pale white segmented *T. taeniaeformis*. Histopathology of liver showed parasitic cyst surrounded by dense granulation tissue. A few granulation tissues surrounding the fatty tissue with the adjacent hepatocytes were observed.

**Keywords:** Rat, *T. taeniaeformis*, Liver cyst

### **INTRODUCTION**

*T. taeniaeformis* is found in the intestine of cats and carnivores. Development of metacestode, *Cysticercus fasciolaris* (*C. fasciolaris*), occurs in the liver of rodents. *C. fasciolaris* in lab mice and rats due to contaminated feces and bedding materials was reported. Once the rats swallow the eggs, the embryo develops into the earliest larval stage, *C. fasciolaris*. Their hooks poke the rats' muscle tissues and dig into the liver via the gut and bloodstream. The larvae reach the stage of strobilocerci. Then, fluid-filled cysts are formed, consisting of a scolex that attaches to the mucosa and connects to terminal bladder till larvae grow.

### **CASE HISTORY AND OBSERVATION**

This observation was made brought to light a significant issue concerning worm infestation

in a rat in Mass Biotech, Chengalpet (Tamil Nadu). A male rat (12 weeks old) in the control group of an experiment started showing symptoms such as severe weight loss, lethargy, and a poor coat condition, for more than a week. These clinical signs prompted an in-depth investigation to determine the underlying cause.

Upon euthanasia and necropsy, a cyst (Fig. 1) was found, which was white in colour and about 1.5 cm in diameter in the left upper lobe of the liver. Inside the cyst, there was a pale white, segmented, flat tape worm of about 15 cm long with a flat elongated neck (Fig. 2). The affected liver and the obtained larva samples were subjected to histopathology. Histopathology of the liver revealed the presence of cestodes were noticed in the liver (Fig. 3). Morphological appearance and histopathology results of the cyst and larvae confirmed that it was *T. taeniaeformis*. The morphological appearance and histopathology results of the cyst and larvae, it was confirmed as *T. taeniaeformis*.

*C. fasciolaris*, the larval form of *T. taeniaeformis*, is also called as *T. crassicollis*, *H. fasciolaris*, *S. fasciolaris*, or bladder worm (Kohn and Barthold, 1984). Transmission of cysticercus infection to cat, a definite host, is through consumption of the liver of the infected rodent. *T. taeniaeformis* infection is rare and it is transmitted through food or bedding contaminated with cat fecal material.

Figure 1: Cyst (arrow) in liver

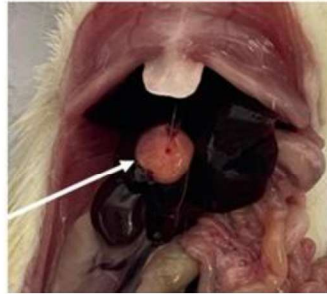


Figure 2: C. fasciolaris larvae

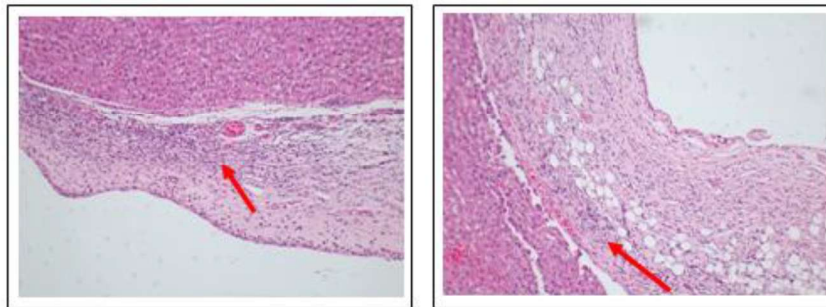


Figure 3: Necrotic core with inflammatory cells macrophages/ plasma cells, surrounded by thick fibrous granulation tissue surrounding cyst

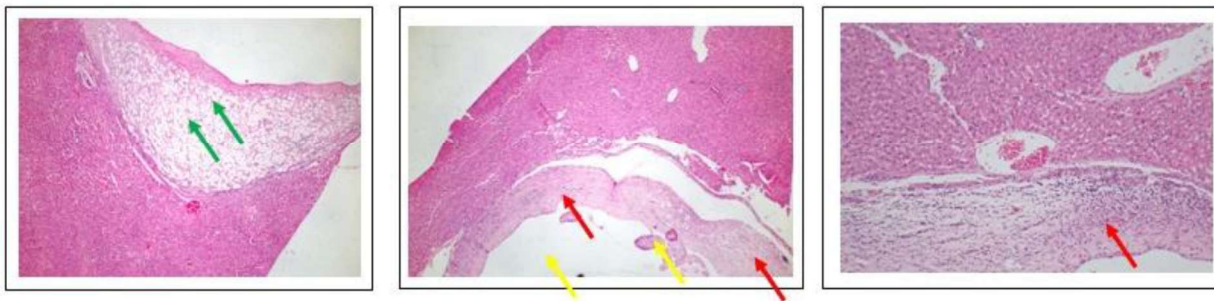


Figure 4: Multiple foci of granulomatous lesions with cestodes in lobular region of liver; Cyst surrounded by granulation tissue of hepatocytes; Granulation tissues with fatty tissue of the adjacent hepatocytes.

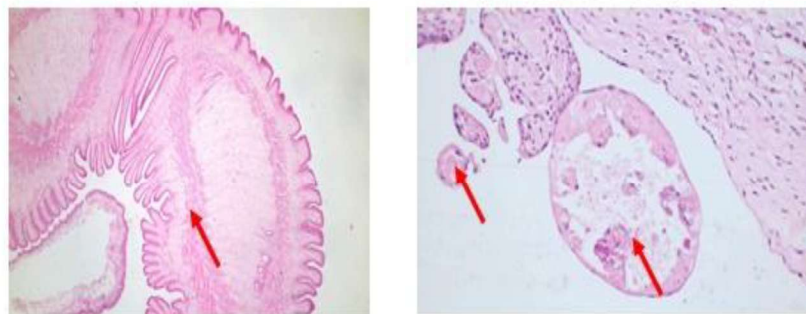


Figure 5: Different stages / cycles of parasites [Cestodes – Taenia] noticed in the cysts in liver

### CONCLUSION

*Cysticercus fasciolaris* caused significant liver damage, emphasising biosecurity and regular checks in preventing parasites in lab animals.

### REFERENCE

Kohn, D.F. and S.W. Barthold (1984), Biology and diseases of rats, in Elsevier eBooks, pp. 91–122.